



A Case Study: Chronic Plaque Psoriasis Treated By Individualized Homeopathic Medicine *Psorinum.*

Dr. Yashwanth Reddy R MD [Hom]

Assistant Professor

Physiology And Biochemistry

Dr. Mohammed Sadiq N. Mujawar MD [Hom]

Associate Professor & HOD

Dept. of Practice of Medicine

ABSTRACT:

Psoriasis has a prevalence ranging from 0.44% to 2.8% in India, with a slight male preponderance. It most commonly affects individuals in their third or fourth decade of life. Conventional medicine often resorts to symptomatic or supportive therapy. Homoeopathy offers a unique individualized approach to healing. This case study presents a 26 years old woman with symptomatically confirmed Plaque Psoriasis, who was successfully treated with Psorinum based on her characteristic skin and constitutional symptoms^{1,2}. The post-treatment images confirmed complete recovery.

Keywords:

Psoriasis, Psorinum, Homoeopathy.

INTRODUCTION:

Psoriasis is a chronic skin condition characterized by the rapid growth of skin cells, leading to the formation of thick, scaly, and inflamed patches called plaques. Psoriasis usually presents with symmetrically distributed, red, scaly plaques with well-defined edges. The scale is typically silvery white, except in skin folds where the plaques often appear shiny with a moist peeling surface. The most common sites are the scalp, elbows, and knees, but any part of the skin can be involved. The plaques are usually very persistent without treatment. Itch is mostly mild but may be severe in some patients, leading to scratching and characterised by thickened leathery skin and increased skin markings. Painful skin cracks or fissures may occur, particularly on the palms and soles³.

TYPES OF PSORIASIS

- **Plaque psoriasis:** The most common type, characterized by raised, red patches (plaques) covered with a silvery-white scale.
- **Guttate psoriasis:** Often triggered by infections, it presents as small, drop-like lesions on the skin.
- **Inverse psoriasis:** Affects skin folds like armpits and groin, appearing as smooth, red patches without scales.
- **Pustular psoriasis:** Marked by pus-filled blisters on a background of inflamed skin, which can be localized or widespread.
- **Erythrodermic psoriasis:** A severe and rare form that causes widespread redness, shedding of skin, and potential life-threatening complications.

- **Nail psoriasis:** Can cause nail pitting, discoloration, thickening, and separation from the nail bed.
- **Scalp psoriasis:** Causes redness, scaling, and itching on the scalp³.

CASE SUMMARY:

Patient details:

Patient Information:

Name: Mrs XYZ

Age: 26 years

Gender: Female

Place: Shiroda, GOA

Chief Complaints: Patient was brought to OPD by her husband on 01 October 2024 presenting with rashes on back and extremities with severe itching.

History of Present illness:

Eruptions on the back which are thick, shiny, scaly with severe itching. Scaly peeling out of rashes on scratching. Eruptions started a year ago.

Itching on becoming warm.

General & Mental Generals:

Appetite: Decreased.

Thirst: Thirsty during night

Desire: Spicy food.

Aversion: Pork.

Thermals: Chilly.

Bowel Movements: Constipated occasionally.

Perspiration: Excessive and generalized at night.

Mental state:

Fear riding Carriage.

Thinks that her itching won't be reduced.

Depressed about disease condition.

Memory weak.

Negative history:

There is no pain, stiffness in joints, inflamed tendons or nail dents.

Past history: Occasionally the patient was complaining of fever, with excessive perspiration on the body treated with allopathic medication.

Family history:

Father: DM-II and Osteoarthritis of knees

Mother: Hypertension.

Husband: Bronchial asthma and Sleeplessness.

Local examination:

Visible eruptions on the back and extremities. Scaly, shiny, white eruptions. Skin is peeling out on scratching. The Eruptions are dry and micaceous with well-defined margins on the back and knee.

Key Diagnostic Points:

Koebner phenomenon seen.

Auspitz sign positive.

Well defined border.

Scales are dry, loose and micaceous


ESR: 80 mm/hour

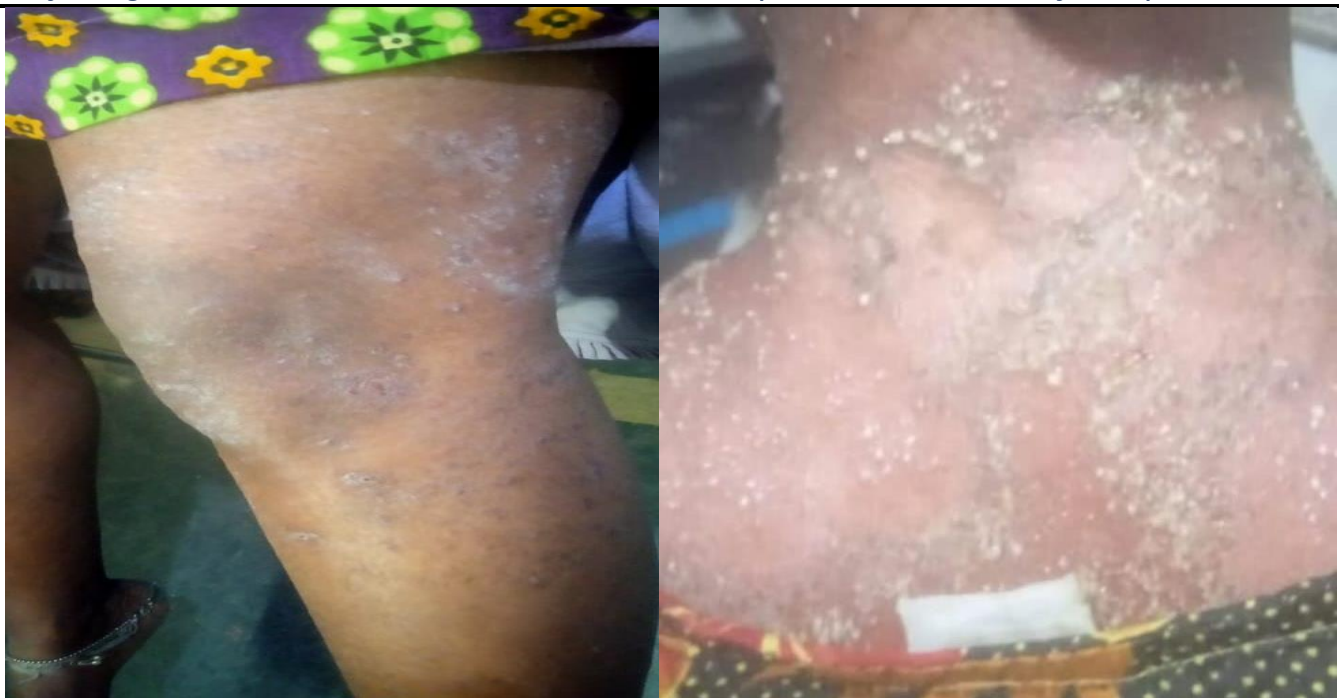

FIG:1
(BEFORE TREATMENT)

Diagnosis:
Chronic Plaque Psoriasis

Totality of Symptoms with Repertorization⁴:



Total
Rubrics
Kingdom
Bjornald's miasms

	Psor.	Puls.	Sulph.	Lyc.	Sef.	Sil.	Maz.	Merc.	Ars.	Phos.	Graph.	Lrn.	Nat-m.	Saph.	Alum.	Clem.	Kali-ar.	Arg-n.	Ars-i.	Cimic.	Mur-ac.	Nat-ar.
	15	10	10	9	9	9	7	10	8	8	7	7	7	7	6	6	6	5	5	5	5	5
	6	4	4	4	4	4	4	3	3	3	3	3	3	3	3	3	3	3	3	3	3	3
	Red	Green	Blue	Green	Red	Blue	Green	Blue	Blue	Blue	Blue	Red	Blue	Green	Blue	Green	Blue	Blue	Blue	Green	Blue	Blue
	White	Green	Red	Red	Red	Red	Red	Red	Red	Red	Red	Red	White	Red	Green	Red	Red	Red	Red	Green	White	Green
R.R. – Mind; Fear; riding; carr(16)	2			1	2				1			2	1							2		
R.R. – Mind; Despair; itching c(5)	4		1			1																
R.R. – Extremities; E. uptic n; :(45)	2	1	2	1	2	2	2	2	3	2	2	1	3	2	1	2	1		2		1	1
R.R. – Back; Eruptions; scales.(4)						2	1				1								1			
R.R. – Skin; Itching; warm; be(27)	3	2	3	3			1	4		2				1	2	1	2	1		1	1	2
R.R. – Perspiration; Night(220)	2	4	4	4	4	4	3	4	4	4	4	4	3	4	3	3	3	3	2	2	3	2
R.R. – Generalities; Food anc(.4)	2	3			1													1				

Fig 2:- Repertory sheet

Remedy Selected: Psorinum 200CH

Rationale for Remedy: Psorinum is indicated in persons who are hopeless, despair of recovery and prominent skin complaints. Its keynote symptoms include itching worse from warmth of bed, intolerable itching and perspiration at night⁴ —exactly matching this case.

TREATMENT PLAN:-

5th October 2024:- Psorinum 200 (1 dose) and placebo BD for 15 days.

Follow Up

Follow up date	Symptoms	Medicine, Potency and Dose
21/10/2024	Itching reduced. New eruptions disappearing.	Placebo for 15 days
08/11/2024	No change in eruptions. Itching Absent.	Psorinum 1m 1 dose, placebo BD for 15 days
24/11/2024	No Eruptions and no itching	placebo BD for 15 days

ESR: Normal.

Eruptions disappeared

No scaling/peeling of skin.No itching.

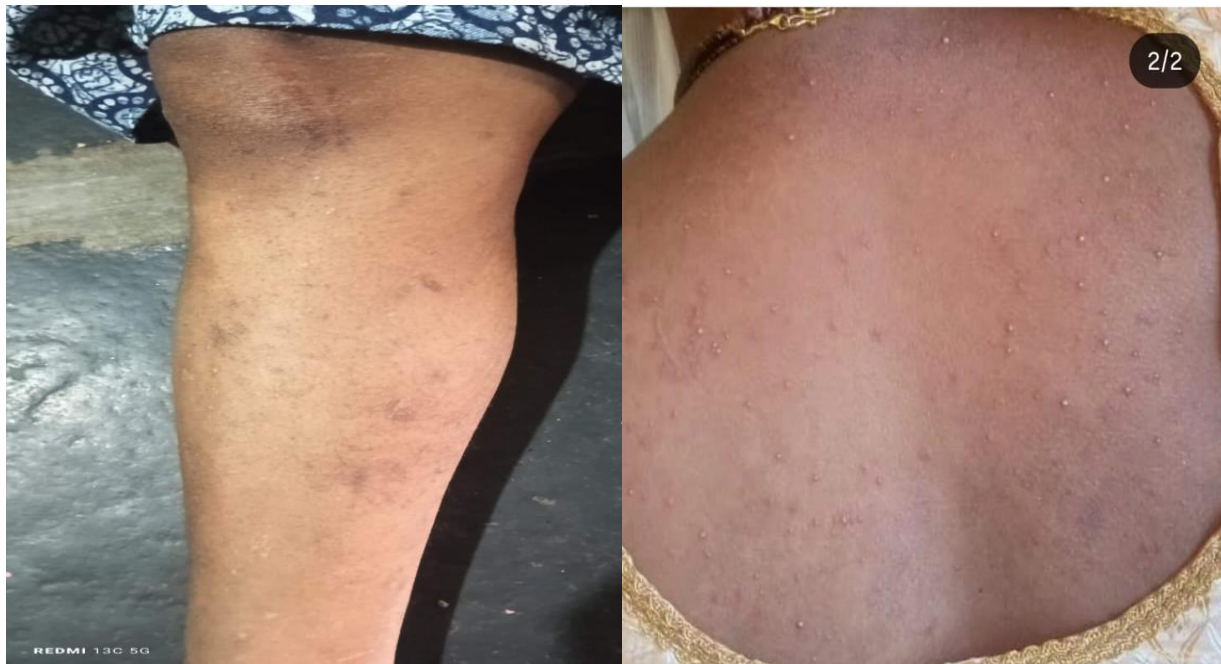

FIG 3:

After treatment

DISCUSSION:

The selection of Psorinum was based on the core Skin complaints and constitutional symptoms. The patient improved both symptomatically and objectively, as confirmed by follow up imaging. The role of Psorinum in managing psoriasis with intolerable itching worse by warmth of bed, with profuse sweat at night, and despair of recovery and hopelessness is well-established in classical Homoeopathy. This case provides clinical evidence of the curative action of an individualized homoeopathic remedy. The short recovery period and absence of recurrence strengthen the evidence.

CONCLUSION:

This case demonstrates the efficacy of individualized homoeopathic treatment in managing Psoriasis. Psorinum, prescribed based on a detailed case analysis, effectively resolved the patient's symptoms and normalized ESR levels. Homoeopathy not only addresses the symptoms but also targets the root cause, promoting long-term healing.

DECLARATION:

Patient's consent was obtained for the use of clinical data and images in this report.

CONFLICT OF INTEREST :-

Not available.

FINANCIAL SUPPORT:-

Not available.

REFERENCES:

1. Boericke W. Pocket Manual of Homoeopathic Materia Medica. New Delhi: B. Jain Publishers; 2014.
2. Allen HC. Keynotes and Characteristics with Comparisons. New Delhi: B. Jain Publishers; 2013.
3. Munjal YP API. Text book of medicine.. 10th ed. New Delhi: JP Medical Ltd; 2015.
4. Synergy Homoeopathic Software – 1.5-5CL-ENG D.1.5 (1025).