



# Histopathological Study Of Pre-Malignant And Malignant Lesions Of Oral Cavity At Tertiary Care Centre

Dr. Maulee Patel<sup>1</sup>, Dr. Krunal Vadsola<sup>2</sup> and Dr. R. K. Tandon<sup>3</sup>

Department of Pathology, SBKS Medical Institute and Research Centre, Dheeraj Hospital, Waghodia, Vadodara.

Corresponding Author: Dr. Maulee Patel, Postgraduate Resident.

1 & 2 – Postgraduate resident, 3 – Professor and Head

## Abstract

**Introduction:** Oral health is important for quantity of life. Oral cancer is major health problem in developing country. Oral cavity is most common site for both Pre-malignant and Malignant lesions.

**Aim:** To study histopathology of pre-malignant and malignant lesions of oral cavity with reference to age, sex and site distribution.

**Material and methods:** Total 140 cases of oral cavity lesions were studied from January 2023 to December 2023. Received biopsy after adequate fixation in 10% buffered formalin, were routinely processed and embedded in paraffin wax. Multiple sections are obtained and stained with Hematoxylin and eosin. All specimens are studied with perspective of age, sex, site and final histopathological diagnosis.

**Result:** Total 140 cases were studied. 61 cases were malignant, 48 cases were pre-malignant and 31 cases were others. Peak incidence of tumors of both pre-malignant and malignant lesions were seen in the age group of 41-50 years. Male predominance was seen. The buccal mucosa was most frequently involved site. Among malignant lesions most common was moderately differentiated squamous cell carcinoma and among premalignant lesions most common was keratosis with mild dysplasia.

**Conclusion:** Early detection of pre-malignant lesion can prevent further complication. Hence not only clinical examination but also histopathological examination which is gold standard for lesions of oral cavity.

**Keywords:** Histopathology, oral cavity, pre-malignant, malignant

## Introduction

Worldwide, oral cancer is the sixth most prevalent cancer, ranking eighth in developed countries and third in developing world <sup>[1]</sup>. In India Incidence rate per 100,000 population were 12.8 in men and 7.5 in women <sup>[2]</sup>. Chewing tobacco, smoking and consumption of alcohol have become social habits in India <sup>[3]</sup>. There are other predisposing factors which can develop oral malignancy such as ill-fitting dentures, sharp broken teeth which results in constant irritation of oral mucosa <sup>[4, 5]</sup>. Majority of the lesions usually are silent and asymptomatic, however, overlapping clinical presentation are noted with various other systemic disorders thereby causing difficulty in clinical diagnosis <sup>[4, 6]</sup>. 90% of the tumors arising from oral cavity are Squamous Cell Carcinoma <sup>[7]</sup>. Many malignancies arise from regions which had pre-malignant and malignant lesions, patients can be managed properly with improved longevity.

## Material and methods

This was a prospective study over the period of one year which included 140 cases which was conducted in of Department of Pathology, SBKS Medical Institute and Research Centre, Dheeraj Hospital, Waghodia, Vadodara. Specimens were received in 10% formalin and sections were processed and embedded in paraffin after grossing. Multiple serial sections of 4-5 microns thickness were obtained from the paraffin block and then stained with Hematoxylin and Eosin.

## Inclusion criteria

1. Oral cavity lesions.
2. Specimen which is adequate and representative of the lesion.
3. Properly resected surgical specimen such as punch biopsies, incisional biopsies, wedge biopsies, surgical excision are included in the study.

## Exclusion criteria

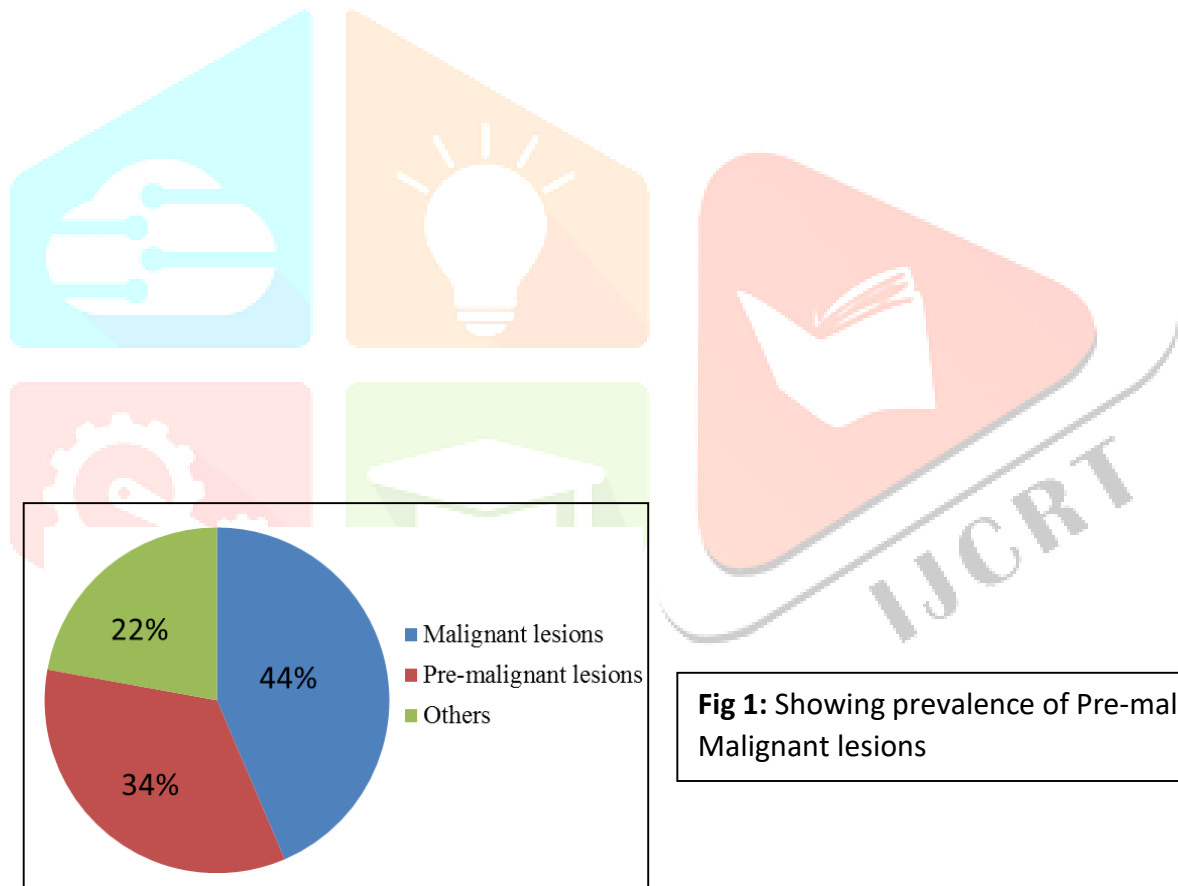
1. Inadequately preserved specimens with handling artifacts.
2. Improper clinical record (history and examination).
3. Neoplasms arising from nasopharynx and oropharynx.

## Results

A total 140 oral biopies were reported over the period of one year. Out of which 61(44%) patients were reported to be malignant, 48(34.28%) were pre-malignant, and 31(22.14%) were others (Figure-1). In age-wise distribution, majority of patients were reported in the age group of 41-50 years (Table-1). Of total cases, 110 were males and 30 were females. Of malignant cases, 51 were males and 10 were females. Of pre-malignant cases, 38 were males and 10 were females (Figure-2). Buccal mucosa was most common involved site followed by lip and tongue (Table-2). In the malignant group, 19(31.44%) had well-differentiated squamous cell carcinoma, 39(63.93%) had moderately differentiated squamous cell carcinoma (Figure-4), 1(1.6%) had poorly differentiated squamous cell carcinoma, 2(3.2%) had verrucous carcinoma (Figure-3). In pre-malignant group, 10(20.83%) had keratosis without dysplasia, 17(35.41%) had keratosis with mild dysplasia, 5(10.4%) had keratosis with moderate dysplasia, 3 (6.25%) had keratosis with severe dysplasia, 10(20.83%) had oral submucous fibrosis, 3(6.25%) had HPV related lesion (Table-3). Other 31 cases were reported as Mucous retention cyst, Mucous extravasation cyst, squamous papilloma and pyogenic granuloma.

Age group (in years)	Number of cases	Percentage
0-10	3	2.1%
11-20	7	5%
21-30	16	11.4%
31-40	35	25%
41-50	39	27.8%
51-60	26	18.5%
61-70	12	8.5%
71-80	2	1.4%
Total	140	100

**Table 1:** Age distribution of Pre-malignant and Malignant lesions



**Fig 1:** Showing prevalence of Pre-malignant and Malignant lesions

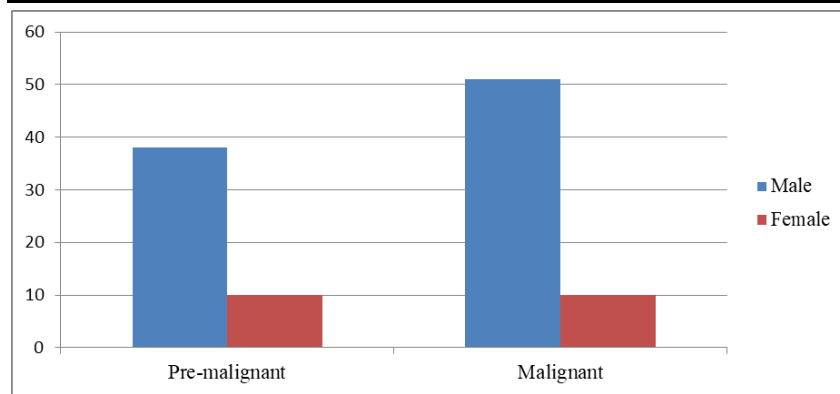


Fig 2: Showing Premalignant and Malignant lesions in individual sex

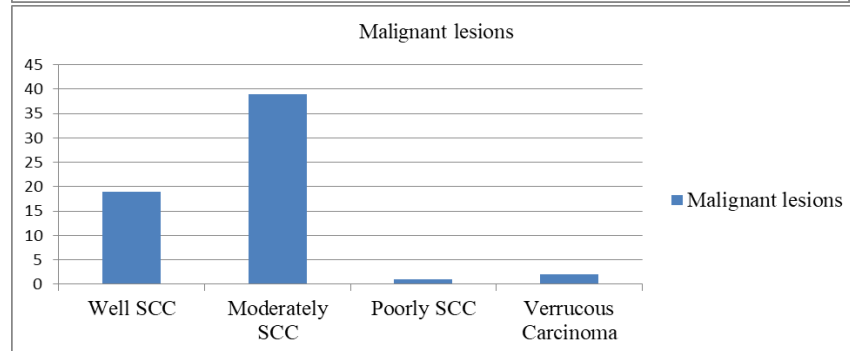


Fig 3: Showing frequency distribution of Malignant lesions

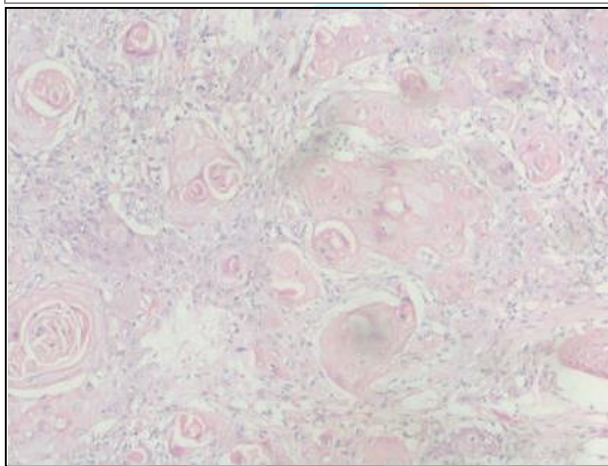


Fig 4: Showing moderately differentiated squamous cell carcinoma with formation of keratin pearls(H & E stain,20X).

## Discussion

Oral cavity is significantly more prone to an enormous number of environmental insults because of its exposure to external environment and making it common site for many tumor and tumor like lesions<sup>[8]</sup>.

The study from January 2023 to December 2023 includes variety of 140 oral cavity lesions, both malignant and pre- malignant. The results obtained after proper analyzing were compared with the results of the earlier studies by various authors.

In present study, maximum number of cases found in the age group of 41-50 years which in accordance with Saraswati *et al.*<sup>[3]</sup>. In our study, Male to Female ratio was 3.6: 1. This shows that there was high incidence of oral pre- malignant and malignant lesions in male as compared to female. Palve *et al.* observed that out of 50 cases, 60% were males and 40% were females in their study with male to female ratio of 3: 2, i. e, male predominance which similar to our findings<sup>[9]</sup>. Senguven *et al.* and Pudasaini *et al.* were reported male predominance in their study<sup>[10, 11]</sup>. In our study, the most common site involved was buccal mucosa (46%). Similar finding was seen in a study done by Modi *et al.* reported site of involvement was buccal mucosa (26.8%)<sup>[12]</sup>. Among malignant spectrum, Squamous cell carcinoma was most common malignant tumor, which was in concordance with Dias *et al.* and Brandizzi D *et al.*<sup>[13, 14]</sup> In differentiation, moderately differentiated squamous cell carcinoma was most common (63.93%) followed by well differentiated squamous cell carcinoma (31.34%) while study done by Shah PY *et al.* showed 57.35% cases of moderately differentiated squamous cell carcinoma and 30.88% cases of well differentiated squamous cell carcinoma<sup>[15]</sup>. Our study revealed that Keratosis with mild dysplasia(35.41%) was most common pre-

malignant lesions followed by Keratosis without dysplasia (20.83%) and Oral submucous fibrosis (20.83%) while study done by Kosam S *et al.* showed 5.71% cases of Keratosis with mild dysplasia and 14.28% cases of Keratosis without dysplasia which can be explained by objective variation <sup>[16]</sup>.

## Conclusion

Oral cavity lesions are frequently asymptomatic to begin with and so can be missed clinically hence the timely and accurate identification of various oral lesions becomes vital prevention of morbidity and mortality. Owing to the rising prevalence and incidence of malignancies, importance of oral hygiene with routine checkup, spectrum of oral lesions seen and their precise time bound diagnosis should be emphasized upon in society. Histopathology is still gold standard for confirmation the nature and the origin of oral cavity lesions cannot be determined by clinical examination alone.

**Funding:** No funding sources

**Conflict of Interest:** None

## References

1. Sternberg's Diagnostic surgical pathology: sixth edition.
2. G Kiran *et al.* Demographics and Histopathological patterns of Oral Squamous cell carcinoma At tertiary level Referral Hospital in Hyderabad, India: A 5 year Retrospective study. Journal of orofacial research. 2012; 2:198-201.
3. Saraswathi TR, Ranganathan K, Shanmugam S, Sowmya R, Narasimhan PD, Gunaseelan R *et al.* Prevalence of oral lesions in relation to habits: Cross sectional study in South India. Indian J Dent Res. 2006; 17(3):121-5.
4. Laishram R, Modi D, Sharma LC, Debnath K. Pattern of oral cavity lesions in tertiary care hospital in Manipur, India. J Med Soc. 2013; 27(3):199.
5. Memon IM, Iqbal SM, Hussain SI, Baig MN. Pattern of oral malignancies at tertiary care hospitals Abstract: Introduction. 2012, 268-71.
6. Author C. Histopathological study of oral cavity lesions: A study on 100 cases ijeer. 2013; 05(May):110-6.
7. DI Conway, M Petticrew, H Marlborough, J Berthiller M Hashibe, LMD Macpherson *et al.* Socioeconomic inequalities and oral cancer risk - a systemic review and meta-analysis of case control studies," International journal of cancer. 2008; 122(12):2811-2819.
8. Author C. Histopathological study of oral cavity lesions: a study on 100 cases ijerr. 2013; 05(May):110-6.
9. Palve DH, Tupkari JV. Clinicopathological correlation of micronuclei in oral squamous cell carcinoma by exfoliative cytology. J Oral Maxillofac pathol. 2008; 12:234-6.
10. Senguven B, Baris E, Yildirim B, Shanibat A, Ozer Yuzel O, Museyibov F *et al.* Oral mucosal lesions : A retrospective review of one institution's 13-year experience. Turk J Med Sci. 2015; 45:241-5.
11. Pudasaini S, Baral R. Oral cavity lesions: A study of 21 cases. J pathol Nepal. 2011; 1:49-51.
12. Modi D, Laishram RS, Sharma LD, Debnath K. pattern of oral cavity lesions in a tertiary care hospital in Manipur, India. J Med Soc. 2013; 27:199-202.
13. Dias GS, Almeida AP. A histological and clinical study on oral cancer: Despective analysis of 365 cases. Med Oral Patol Oral Cir buccal. 2007; 12(7):474-8.
14. Brandizzi D, Gandolfo M, Velazco MI, Cabrini RL, Lanfranchi HE. Clinical features and evolution of oral cancer. A study of 274 cases in Buenos Aires, Argentina. Med Oral Cir Bucal. 2008; 13(9):544-8.
15. Shah PY, Patel RG, Prajapati SG. Histopathological study of malignant lesions of oral cavity. Int J Med Sci Public Health. 2017; 6(3):472-478.
16. Kosam S, Kujur P. pattern of oral cavity lesions: A Retrospective study of 350 cases. Int J Sci Stud. 2016; 4(3):35-69.