



# INTERNATIONAL JOURNAL OF CREATIVE RESEARCH THOUGHTS (IJCRT)

An International Open Access, Peer-reviewed, Refereed Journal

## Role of the Sonosalpingography for the Assessment of Tubal Patency

1Name of 1st Author- Dr. Vijay Kishor Chakravarti , 2Name of 2nd Author - Prof Dr. Adesh Kumar , 3Name of 3rd Author – Dr.Bijendar Kumar Meena, 4Name of 4th Author – Ms. Shubhanshi Rani

1Designation of 1st Author Faculty of ParaMedical Sciences (Demonstrator), 2Designation of 2nd Author Dean ,Medical , UPUMS , 3Designation of 3rd Author Professor ,4Designation of 4th Author Assistant Professor

1Name of Department of 1st Author Radiological & Imaging Technology ,

1Name of organization of 1st Author Faculty of ParaMedical Sciences ,UPUMS,Saifai , City Etawah , Country-India

Faculty of Para Medical Sciences Uttar Pradesh University of Medical Sciences, Saifai, Etawah , Uttar Pradesh , India (1) , Dean , Medical , UPUMS , Saifai, Etawah, Uttar Pradesh, India (2) , Professor Department of Radiology NIMS University, Jaipur, Rajasthan(3), Assistant Professor SCPM College Gonda U.P. India (4).

**Abstract-** Infertility is the most common health problem in the world .Various methods and good infertility procedure are available .

**Aim and Objectives-** The aim of our study is to determine the role of Sonosalpingography in the assessment of tubal patency in cases of primary and secondary infertility (Infertility women).

**Methods** –In our study of 50 fruitless women complaining of infertility, suspected tubal pathologies underwent various radiological modalities. Sonosalpingography and Normal Saline was performed in all cases .

**Result-** Sonosalpingography has 87.18% Sensitivity and 75.67% Specificity .Analysis of the row data gave positive predictive value of 80.19% and negative predictive value of 79.9% near perfect agreement was seen between the result of the one method.

- ✚ Majority of the cases belong from 26 to 30 years of age and have been suffering from obesity.
- ✚ 90% of the cases had primary type of infertility and only 10% of the cases at secondary type of infertility.

**Conclusion** – Sonosalpingography has a high sensitivity for tubal patency and is less Expensive diagnostic procedure in the management of the infertility in the Females .easily availability and accessibility of the ultrasound in all primary health care centres definitely can prove superior to conventional method of diagnosis of tubal patency in the infertility patients.

**Keyword** – Sonosalpingography , Tubal Patency, Infertility , Normal Saline

## Introduction -

Primary and Secondary Infertility is defined as the ability to conceive after unprotected intercourse for a period of one year of couples in which the woman is under 40 years of trying for couples in which the woman is over 40 years of age. Primary infertility is a condition in which no previous pregnancies have occurred. Secondary infertility is a condition in which a prior pregnancy, although not necessarily a live birth has occurred.(1) .6.1 million people in the United States or roughly 10-15% of the individuals belonging to the reproductive age group are affected by infertility there were an estimated 48.5 million infertile couples worldwide from 1990 to 2010 (2). There is only little change noted in the overall prevalence of infertility in most of the countries (3).The prevalence of female infertility has increased since 1990, but secondary infertility has decreased overall. Tuboperitoneal factors are responsible for about 32- 42 % of female infertility in India.(4) The prevalence of pelvic disease , Genital tract tuberculosis , Chronic Infection etc. is quite common in our country so the incidence of Tubal factors in Infertile women is high.(5) Various methods have been developed for Tubal patency evaluation , SSG –Sonosalpingography used .This study is to bring to focus the value of the female pelvic SSG image in assist tubal patency in order to overcome the Sonosalpingogram reduce the cost of examination(6).

## Material And Methods –

The research was conducted in the Department of Radiodiagnosis SCPM Gonda in collaboration with Obstetrics and Gynaecology in SCPM Hospital Gonda ,Uttar Pradesh between 10 Oct 2022 to 20 Sep 2023 .All patients with primary infertility who fit in the inclusion and Exclusion criteria were selected in the study .The patient's detail history was taken clinical examination was done.

## Study Tools

The tool used for data collection will be as follows:

- ✚ Tool 1 : To observe general health and check list to assess Fallopian Tubes and Female Reproductive organs.
- ✚ Tool 2: Ultrasound (Sonography) will be used for Evaluation of Emerging Trends
- ✚ Tool 3 : Balloon catheter

## Inclusion Criteria –

- ✚ All instances of infertility measured age between 20- 40 years.
- ✚ All cases were ready to take part in the study.
- ✚ The age limit was minimum 20 years and more than 40 years.
- ✚ Active PID (Pelvic Inflammatory Disease)
- ✚ Patients with cervical pathology (e. g: polyp )

- + Hypersensitivity to differentiate.
- + The patient is unsuitable for sedation or anaesthesia.
- + The patient has history of tubal medical procedure.
- + PCOD

## Exclusion Criteria -

- + Age less than 20 years and above 40 years .
- + Patient having history of Tubule surgery .
- + Pregnant patient
- + Blood Presser
- + Cervical pathology.

Preparation of the Sonosalpingography for the patient , Bladder must be empty, after informed consent ,Antispasmodic drug was given 30 minutes before the SSG test. Patient asked to void urine before the SSG procedure ,Injection Dexamethasone , injection Chlorpheniramine maleate was kept ready. Antispasmodic was also administered half and an hour before the test.

## Sonosalingography Examination Technique –

- + The fact that transvaginal Sonography can provide information on endocrine, pelvic, uterine, and tubal variables is crucial to keep in mind. By properly planning and carrying out a sonographic examination, one might therefore combine the advantages of laparoscopy, HSG, hysteroscopy, and endocrine assessment in a single straightforward non invasive test.
- + Transvaginal ultrasonography is used to assess the pelvic organs and check for tubal patency at the couple's initial visit, allowing for a speedy diagnosis of any issues and the implementation of the best treatment plan. Prior to laparoscopy, it was believed that no infertility examination was comprehensive.
- + Without a doubt, laparoscopy is the most widely used and effective technique for examining pelvic variables and tubal patency. Negative laparoscopies can be avoided anytime the pelvic organs are deemed normal by the transvaginal ultrasonography.

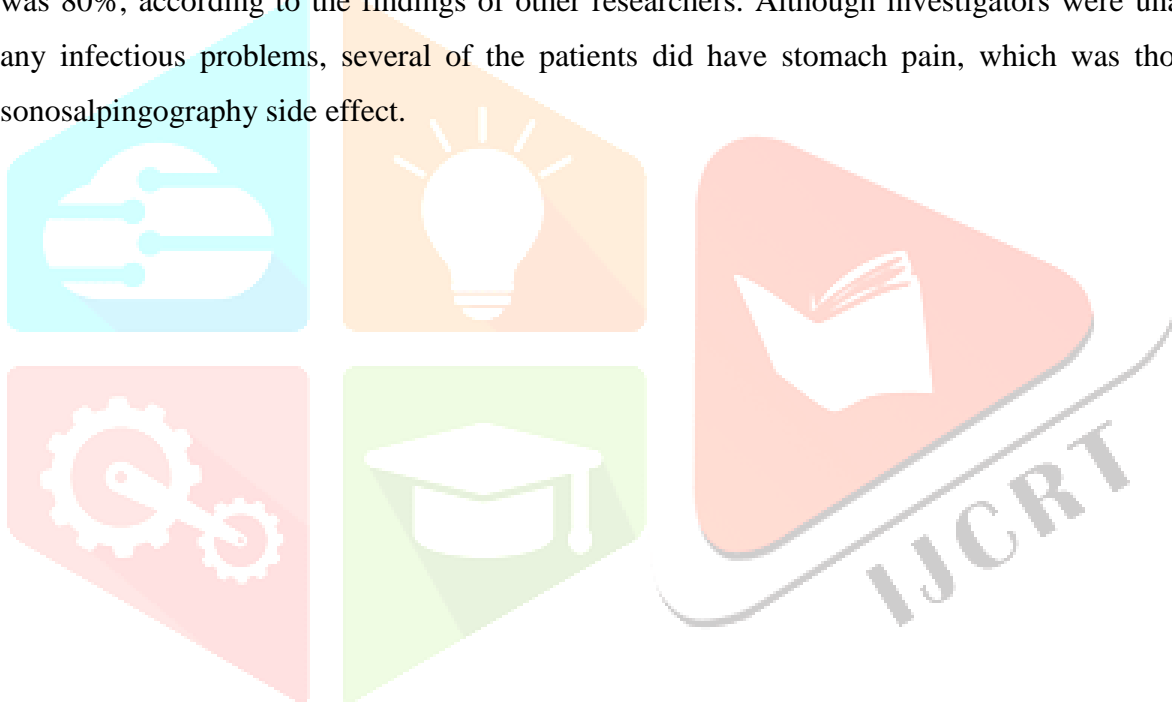
## COMPLICATION OF SONOSALPINGOGRAPHY

- + Ultrasound salpingography problems include procedure- and contrast-related. The discomfort and agony of the instrumentation are closely linked to the problems in the first group. This resembles X-ray HSG. However, between 2% and 8% of procedures fail because to either visualisation or canalization's technical challenges.
- + Many employees claim that contrast-related pain from using Echovist is less than from using HSG, although few have mentioned a greater prevalence of nausea and vasovagal responses, which seem to be particularly frequent among those with patent tubes.

- ✚ This could be because Echovist-200 has a greater osmolality than standard X-Ray contrast agents. Agitated saline appears to be less uncomfortable, most likely once more due to the injection solution's low osmolality.

## **SPECIFICITY OF SONOSALPINGOGRAPHY**

- ✚ Similar to the majority of other research, laparoscopic evaluation has revealed that the sonosalpingography diagnostic accuracies, sensitivity, and specificity are comparable to those of hysterosalpingography. Tubal peristalsis is typically undetectable in HSG, however. Further more, it is discovered that SSG enables the visualisation of polyps, adhesions, and myomas within the endometrial cavity.
- ✚ The specificity of the Sonosalpingography for identifying tubal patency was 96.2%, when the specificity was 80%, according to the findings of other researchers. Although investigators were unable to detect any infectious problems, several of the patients did have stomach pain, which was thought to be a sonosalpingography side effect.



**RESULTS - Table no.1. Representation of frequency distribution of cases with respect to Age Interval.**

Age Interval	No of cases	Percentage
20-25 Year	15	30.0
26-30 Year	26	52.0
31-35 Year	7	14.0
Above 35 Year	2	4.0
Total	50	100.0

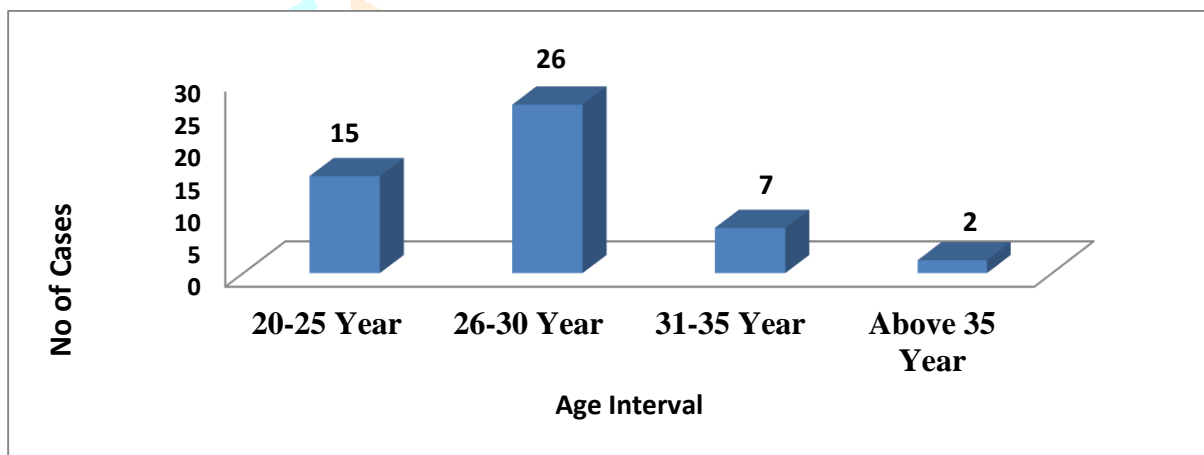


Fig.1 shows the frequency distribution of Age interval, where 15 subjects were found in 20-25 Year i.e., 30.0%, 26 subjects were found in 26-30 Year i.e., 52.0%, 7 subjects were found in 31-35 Year i.e., 14.0% and 2 subjects were found in Above 35 Year i.e., 4.0%

**Table: 2- Representation of frequency distribution of cases with respect to Type of Infertility.**

Type of Infertility	No of cases	Percentage
Primary	45	90.0
Secondary	5	10.0
Total	50	100.0

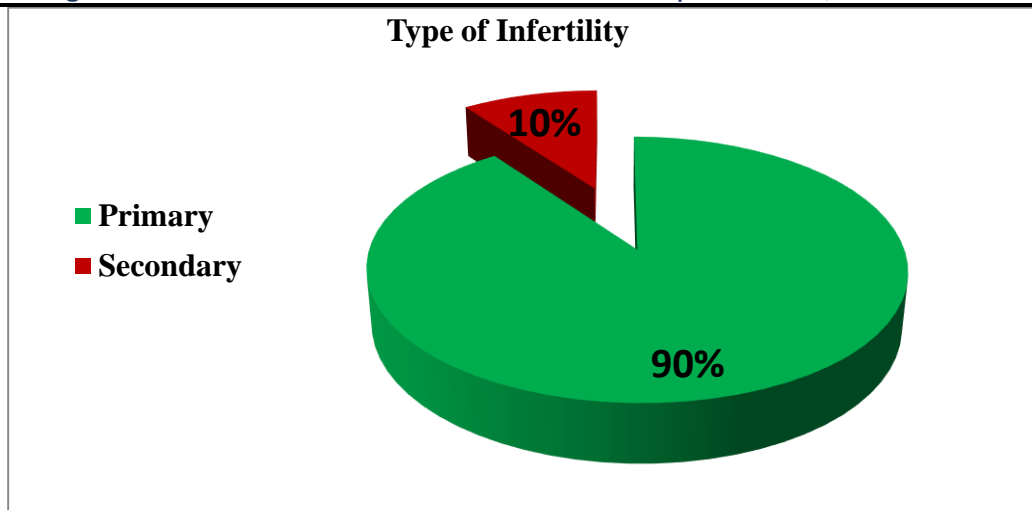


Table no .02 and Fig.no 02 show the frequency distribution of types of infertility, where 45 subject were found in Primary Infertility i.e. 90 % and 05 subject were found in secondary infertility i.e. 10%.

## DISCUSSION-

- ✚ Similarly another study that was conducted by the researchers Ghani et al. they had included 34 cases who were suffering from either primary or secondary kind of infertility and the evaluation also done for the tubal patency with the help of sonosalpingography.
- ✚ They had observed in their results that the specificity of the Sonosalpingography for diagnosing the tubal patency was 96.2% where the specificity was 80% . Even though they could not observe any infectious complications, abdominal pain was noticed in some of the patients that was considered to be the effects of sonosalpingography.
- ✚ Following that this paper had focused on the association between the type of infertility to that with the reports of SSG.

## CONCLUSION –

We concluded that Sonosalpingography is highly Sensitivity , specific and is less invasive . Fallopian tube evolution is important in infertility cases. The results of this study -Sonosalpingography showed bilateral tubal patency in 84% in cases. So I said that the Best Examination of the SSG for Infertility cases . Sonosalpingography is a best ,chief and office based technique in the evaluation of tubal patency and uterine status. The outcome of Sonosalpingography is almost similar to the values of Hysterosalpingography. The Sonosalpingography should be used initially to access tubal patency in case of Primary and Secondary infertility , if any abnormality is detected on Sonosalpingography Examination .

- ✓ 52 percent of the instances, or the majority of the cases, are from the age range of 26 to 30.
- ✓ Obesity accounted for 54% of the cases and was present in the majority of them.
- ✓ 90% of the cases belong to the primary type of infertility, and only 10% of them were presented with the secondary type.

**Funding – No funding sources.**

**Conflict of interest – None declared.**

## REFERENCES –

1. Inki P., Palo P, Anttila L. Vaginal Sonosalpingography in the evaluation of tubal patency; *Acta Obstet Gynecol Scand.* 1998 Nov; 77(10):978-82.
2. Kdous M. Hysterosalpingography in the assessment of tubal patency; *Tunis Med.* 2006 Aug; 84(8): 520-5. French.
3. A Strandell et al. The Assessment of endometrial pathology and tubal patency: a comparison between the use of USG and X-Ray HSG for the investigation of infertility patients; *Ultrasound Obs Gynecol.* 1999 sep; 14(3): 200-4.
4. Luciano D. et al. Contrast Ultrasonography for tubal patency; *J Minim Invasive Gynecol.* 2014; 21(6):994-8.
5. Monte G. et al. Hysterosalpingo contrast sonography: let's make the point; *Arch Gynecol Obstet.* 2015 Jan; 291(1); 19-30.
6. J Bacevac et al. Diagnosis value of HSG in examination of fallopian tube in infertile women; *Srp Arh Celok Lek.* Oct 2001; 129(9-10): 243-6.  
Gonca Yetkin et al The Relationship between HSG Proven Tubal Occlusion, Stimulated Intrauterine Insemination and Pregnancy Rate : *Balkan Med J.* 2017 Jan; 34(1): 60-6.
7. Asim Kurjak ,et al ,*Ultrasound in obstetrics & gynecology 2<sup>nd</sup> edition jaypee – Hysterosalingography , normal and abnormal finding ,2008,60,899-902.*
8. David sutton ,text book of radiology & Imaging 6<sup>th</sup> Ed.churchill Livingstone ,vol II 1998:45,1247-48.
9. Allahabadiya GN.Fallopian tubes and ultrasound .The Sion experience .*Fertile Steril* 1992:58: 901-2 .
10. Richman TS & et al Fallopian Tubal patency assessed by ultrasound fluid injection *Radiology* 1984;152;507-10.
11. Jonathan S. Berek. Berek& Novak's Gynaecology. 15<sup>th</sup> edn. Gopsons papers ltd: Wolters Kluwer India pvt ltd; 2012.
12. Raussman Robabeh M, Roozbeh T. comparision of hysterosalpingography and laparoscopy in infertile Iranian women with tubal factors. *Ginekol Pol.*2012 nov; 83(11): 841-3.

13. Diechert U. Evaluation of tubal patency by hysterosalpingocontrast sonography(HYCOSY). In: Kupesie S. Ziegler D. (eds). Ultrasound and infertility. New York the Parthenon publishing group. 2000:263 and 284.
14. Omigbodun AO, Fatukasi JI, AbuduT. Ultrasonography as an adjunct to hydrotubation in the management of female infertility. Cent Afr J Med. 1992 Aug;38(8):345-50.
15. L. Mastroianni et al : British Journal of obstetrics and Gynaecology, 1982 Vol 98:619-623.

