



INTERNATIONAL JOURNAL OF CREATIVE RESEARCH THOUGHTS (IJCRT)

An International Open Access, Peer-reviewed, Refereed Journal

A CASE REPORT OF GIANT CELL TUMOR IN DISTAL END OF FEMUR OF 16 YEAR OLD MALE PATIENT

Atul Kothari^{1*}, Jigar Shah², Monika Patel³, Ayushee Ganatra⁴, Maulee Patel⁵

¹Senior Resident, ²Assistant Professor, ^{3,4,5}Junior Resident

Department of Pathology, Dhiraj General Hospital, SBKS MI & RC, Sumandeep Vidyapeeth, Waghodia, Gujarat, India

Abstract

A giant cell tumor (GCT) is defined as the presence of large multinucleated osteoclast-like giant cells, along with mononuclear spindle-like stromal cells and other monocytes. It most commonly occurs in the knee joint. The most common age of presentation of GCT is 20-45 years with female preponderance. The most usual presentation of a GCT is pain due to mechanical instability from bone resorption. A localized bony swelling may be observed due to destruction of the bone and tumor progression. One should keep in mind this entity and final diagnosis is always done by histopathological examination. Curettage and Bone Grafting is a common surgical approach and effective too.

Keywords

Giant cell tumor, Multinucleated giant cells, Osteoclastoma, Knee joint.

Introduction

Giant cell tumor (GCT) also known as a giant cell tumor of bone (GCTB) or osteoclastoma, is a relatively rare, benign but locally aggressive bone tumor. The most common site of a GCT is the knee joint. Giant cells in GCTs lead to bone resorption. There is association of an H3F3A mutation, mainly pG34W with GCTs [1]. The most common age of presentation of GCT is 20-45 years with female preponderance [2, 3]. The most usual presentation of a GCT is pain due to mechanical instability from bone resorption. A localized bony swelling may be observed due to destruction of the bone and tumor progression. GCTs are often found close to joints and hence cause a limited range of motion, joint effusion, and sometimes synovitis [3]. We describe a case of a GCT of the distal femur of right side treated by an excision of the femur.

Case Presentation

A 16 year old male patient presented with a complain of right knee pain and swelling since 5 months in orthopedic outpatient department of Dhiraj general hospital, SBKS MI & RC, Waghodia, Gujarat. He also had difficulty in walking and cross leg sitting as well as squatting. On examination, a single oval 9×8×3 cm swelling was seen over the lateral aspect of the right distal thigh. The overlying skin of the swelling was normal in appearance, with no sinuses and no dilated or engorged veins. There was also history of night cries and weight loss. USG of local part revealed large multiloculated enlarged cystic lesion with multiple thick septation noted involving distal end of right femur and lesion shows significant peripheral and internal vascularity with surrounding soft tissue and subcutaneous edema, possibility of neoplastic etiology. X-ray showed a lytic lesion with well defined nonsclerotic margins (**Photograph - 1**). The patient underwent surgery and the resected specimen was sent to histopathology section of Pathology department. We received a bone specimen (distal femur and proximal tibia) measuring 11x 8 x 3 cm with smooth and glistening outer surface and intact capsule (**Photograph - 2**). On cut section, brownish areas are seen (**Photograph - 3**). Representative sections were given and processed for microscopic examination [4-7]. Microscopic examination was done by two pathologists. The sections showed tumor composed of two components which were giant cells and stromal cells. There was regular and uniform distribution of giant cells throughout the lesion. These giant cells contained 10-20 nuclei. The mononuclear stromal cells had spindle to oval shaped nuclei with ill defined cytoplasm. Areas of vascular stroma, hemorrhage and reactive woven bone formation were also seen. There was no evidence of nuclear pleomorphism, necrosis or mitosis in the sections examined. Overall findings were suggestive of giant cell tumor/ Osteoclastoma of lower end of femur (**Photograph - 4, 5**).

Discussion

A giant cell tumor (GCT) is defined as the presence of large multinucleated osteoclast-like giant cells, along with mononuclear spindle-like stromal cells and other monocytes [8]. It most commonly occurs in the epiphysis (the end portion) of long bones, such as the distal end of the femur (thigh bone), the proximal end of the tibia (shin bone), and the distal end of the radius (forearm bone). GCTs account for 5% of all primary neoplasms and 20% of all benign bone tumors [4].

Although giant cell tumors are not malignant (cancerous), they can be locally aggressive. This means they can grow and destroy surrounding bone and tissue. Common symptoms include pain, swelling, and limited joint mobility in the affected area. Pain is often more severe at night and may become chronic if left untreated. Around 12% of patients present with a pathological fracture, this indicates more aggressive disease, with the possibility of local recurrence post-treatment [6].

Our patient also presented with right knee pain and swelling since 5 months, difficulty in walking and cross leg sitting as well as squatting. X-rays, MRI (Magnetic Resonance Imaging), and CT (Computed Tomography) scans are typically used to diagnose and evaluate the extent of the tumor. A histopathological examination is necessary to confirm the diagnosis because histopathology is gold standard for the final diagnosis. The natural history of giant cell tumor is that of low grade malignancy. Microscopic grading of giant cell tumor is not of great value except for obviously sarcomatous lesion. In our case there is no evidence to suggest sarcoma. Treatment options for giant cell tumors of the lower end of the femur include Curettage and Bone Grafting, Resection followed by Reconstruction and Radiation Therapy.

Curettage and Bone Grafting is a common surgical approach. It involves removing the tumor and filling the cavity with bone graft or a bone cement substitute. In some cases, a more extensive surgery may be required, where a portion of the affected bone is removed, and reconstruction with an implant or prosthesis is performed.

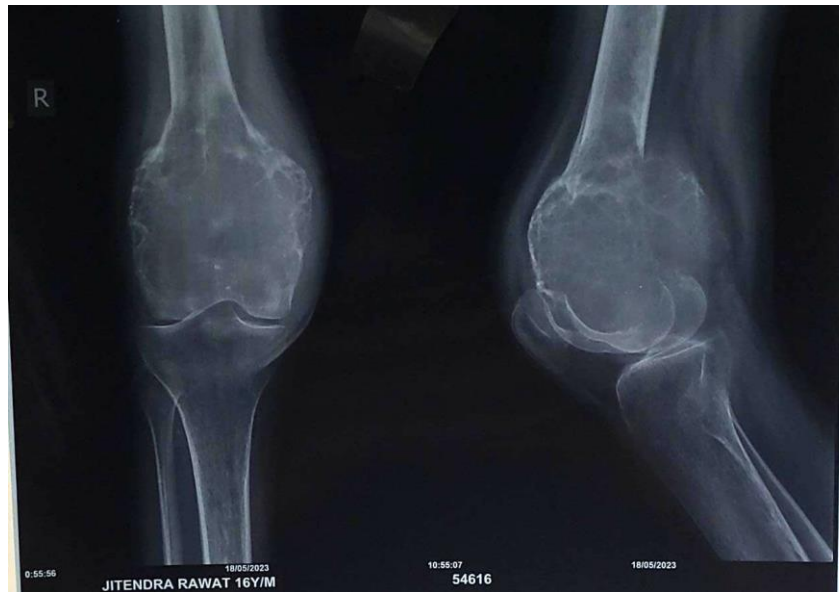In some cases, radiation therapy may be considered when surgical options are limited. The prognosis for giant cell tumors of the lower end of the femur is generally good when treated appropriately. Recurrence can occur in some cases, so long-term follow-up is often recommended.

Conclusion

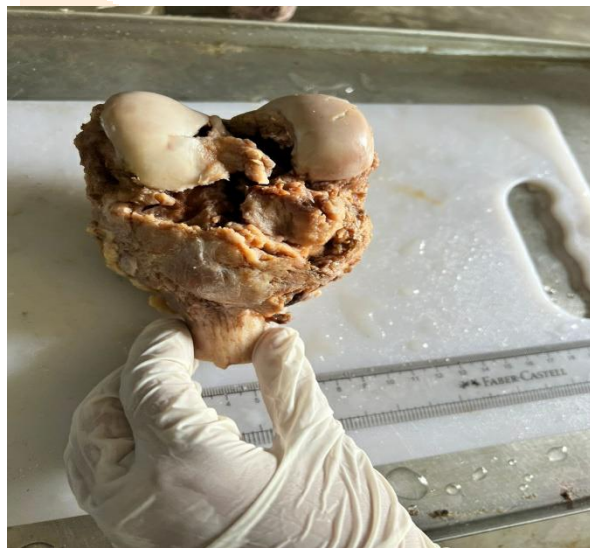Giant cell tumor of bone (GCTB) or osteoclastoma, is a relatively rare and benign but locally aggressive bone tumor. The most common site of a GCT is the knee joint. One should keep in mind this entity and final diagnosis is always done by histopathological examination. Curettage and Bone Grafting is a common surgical approach and effective too.

References

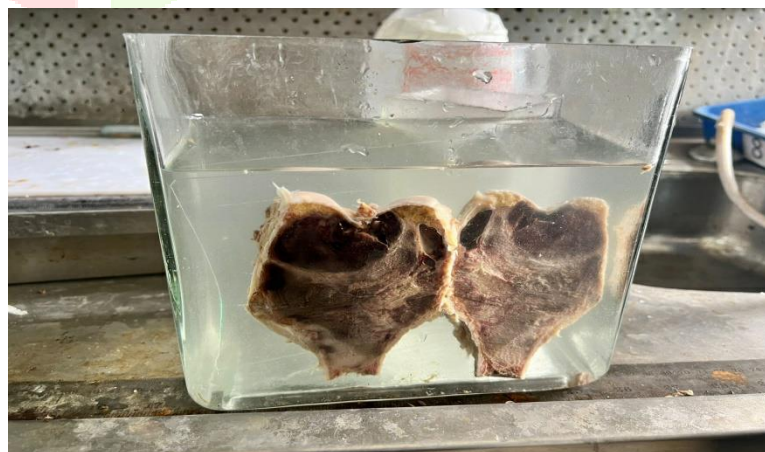1. Cowan RW, Singh G. Giant cell tumor of bone: a basic science perspective . *Bon.*, 2013; 52: 238-46. 10.1016/j.bone.2012.10.002
2. Kalil RK, Amary F. Tumors and tumor-like lesions of bone . Santini-Araujo E, Kalil R, Bertoni F, Park YK (ed): Springer, Cham; 2020.
3. Turcotte RE. Giant cell tumor of bone. *Orthop Clin North Am.*, 2006; 37: 35-51. 10.1016/j.ocl.2005.08.005
4. Rathod GB, Ghadiya V, Shinde P, Tandan RK. Pleomorphic sarcoma in 60 years old male – A case report. *International Journal of Current Microbiology and Applied Sciences*, 2014; 3(8): 510- 5.
5. Gunvanti Rathod, Pragnesh Parmar, Sangita Rathod, Ashish Parikh. Suprascapular malignant fibrous histiocytoma – A case report. *Discovery*, 2014; 12(31): 50-53.
6. Rathod GB, Goyal R, Bhimani RK, Goswami SS. Metaplastic carcinoma of breast in 65 years old female - A case report. *Medical Science*, 2014; 10(39): 77-81.
7. Gunvanti Rathod, Sangita Rathod, Pragnesh Parmar, Ashish Parikh. Diagnostic efficacy of fine needle aspiration cytology in cervical lymphadenopathy –A one year study. *International Journal of Medical and Pharmaceutical Sciences*, 2014; 4(5): 1-8.
8. Chakarun CJ, Forrester DM, Gottsegen CJ, Patel DB, White EA, Matcuk GR Jr. Giant cell tumor of bone: review, mimics, and new developments in treatment. *Radiographics*, 2013; 33: 197-211. 10.1148/rg.331125089
9. Lewis VO, Wei A, Mendoza T, Primus F, Peabody T, Simon MA. Argon beam coagulation as an adjuvant for local control of giant cell tumor. *Clin Orthop Relat Res.*, 2007; 454: 192-7. 10.1097/01.blo.0000238784.98606.d4



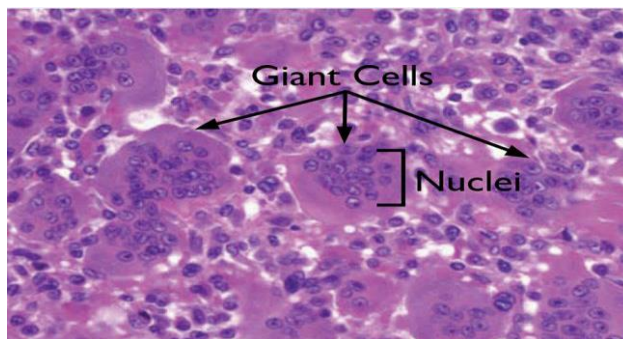
Photograph – 1: Large multiloculated enlarged cystic lesion.



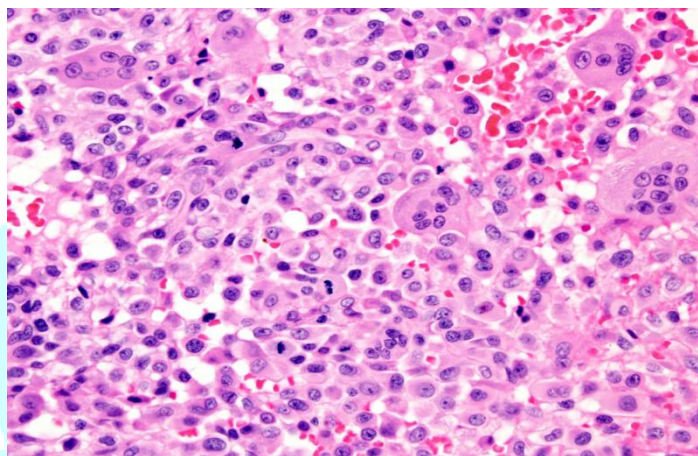
Photograph – 2: Bone specimen of distal femur proximal tibia.



Photograph – 3: Cut surface with brownish areas.



Photograph – 4: Tumor composed of giant cells and stromal cells (H& E stain, 10 X).



Photograph – 5: Tumor composed of giant cells and stromal cells (H& E stain, 10 X).

