



INTERNATIONAL JOURNAL OF CREATIVE RESEARCH THOUGHTS (IJCRT)

An International Open Access, Peer-reviewed, Refereed Journal

BONE FRACTURE DETECTION SYSTEM USING RANDOM FOREST CLASSIFIER

Geethanjali. N,

*Student, M.Sc. Computer Science,
Nirmala College for Women,
Coimbatore.*

Mrs. C. Clement Sherlin,

*Assistant Professor, Department of Computer Science,
Nirmala College for Women,
Coimbatore.*

Abstract - This proposed system is about automated techniques and methods to detect fracture. X-ray images are studied manually, but it is time-consuming and flat to errors. As X-ray images are more susceptible to noise, we used many preprocessing steps to remove noise and blur from the image. Thus, the system is able to spot fractures more accurately. The system detects fractures based on the type of fracture. The image is cleaned of noise and transformed into a clearer image so that the system can easily detect fracture. We used image processing methodologies to track bones. All unwanted objects, as well as smaller objects, are removed by the system. Finally, based on the connected component, the system detects a fracture. The system displays a bounding box around the fracture. Based on types of fracture images, preprocessing steps, and what a fracture detection system involves. The proposed system is able to detect bone dislocation with an 80% success rate, major bone fractures with 60-70% accuracy, and minor fractures with 50-60% accuracy.

Index Terms - Detect Fracture, Image processing, X-Ray image.

I. INTRODUCTION

Today, medical imaging can be a scientific field that is gaining great heights in the healthcare sector thanks to the many technological advancements and advances in computer code. It plays an important role in the designation of diseases and greater patient care, and it helps doctors choose options related to treatment type. Treatment for bone fractures, which affect a large number of people belonging to every age group, is becoming necessary in today's fashion society. It is also a typical disadvantage in many countries that are already developed, where the fracture varieties are also increasing the cut. Fractures could take place because of an easy mistake or because of

any disease. Therefore, a rapid and correct diagnosis is important for any sort of treatment to be prescribed. Subsequently, radiologists as well as doctors use X-ray results to determine if any occurrence of fracture exists, along with the exact type of fracture. Under the process of feature extraction, the method named Hough's transformation was applied to detect the line. Mallikarjuna Swamy M. S. focused on developing an associated-grade economic imaging system for rapid and correct classification of bone fractures supported by information obtained from photographs and CT images. The present research makes use of different techniques of image processing, like extraction forms, segmentation, preprocessing, and edge detection. Such techniques are classified as broken or unbroken by comparing the accuracy of various forms of programming. With the eighth, they outline the exactness of the detection system for bone fractures, along with its performance and its limitations. They intend to implement the system in four stages, namely pre-processing, bone detection, segmentation, and feature extraction. During the fusion classification, three different classifiers were used, including the Neural Propagation Network, the Nave Bayes support, and the vector machine classifier. They mentioned the outcomes showing a huge enhancement in the classification rate as well as the detection rate.

II. LITERATURE SURVEY

A. Artificial Intelligence detection of distal radius fractures: a comparison between the convolution neural network and professional assessments

In light of recent publications on the utility of DL for bone fracture diagnosis in the radiological examination, it is important for practicing physicians to recognize the current scope of DL as it may impact clinical practices in the near future. This editorial will give an within reach of the practicing clinician into the present advances in AI fracture analysis by reviewing the existing fiction on this contributor. The electronic record was searched for significant articles recitation to AI applications in bone fracture detection. They built-in all available work from PubMed, Medline, and cross-references, which satisfied the enclosure criteria. The search identified 104 references. Of those, 13 articles were eligible for analysis. Among AI advancements, fracture imaging applications can be separated into types of fracture detection, classification, segmentation, and non-interpretive tasks. In spite of the potential work obtainable in the literature, there are a lot of challenges in the

form of clinical translation and its widespread uses. These challenges range from proof of safety to clearance from the regulatory agencies.

B. Detecting intertrochanteric hip fractures with orthopedist-level accuracy using a deep convolutional neural network

The researchers trained a large deep convolutional neural network to categorize the 1.2 million high-resolution images in the ImageNet LSVRC-2010 contest into 1000 different classes. On the test data, the researcher achieved top-1 and top-5 error rates of 37.5% and 17.0%, in that order, which is significantly enhanced than the previous state-of-the-art. The neural network include 60 million parameters and 650,000 neurons contain in the neural networks. It consists of five convolutional layers, some of which are followed by max-pooling layers, and three fully connected layers with a final 1000-way softmax. To make instruction quicker, we used non-saturating neurons and a very capable GPU implementation of the convolution operation. To decrease in excess of appropriate in the fully connected layers, we engaged a recently developed regularization method called "dropout" that proved to be very effective. We also entered a variant of this model in the ILSVRC-2012 competition and achieved a top-5 test error rate of 15.3%, compared to the 26.2% achieved by the second-best entry.

C Bone Fracture Detection Using Deep Supervised Learning from Radiological Images

The performances of diagnosing intertrochanteric hip fractures from proximal femoral radiographs by a convolutional neural network and orthopedic surgeons were compared. In this study, 1773 patients were enrolled and their hip plain radiographs were cropped to exhibit only proximal fractured and non-fractured femurs. Images showing pseudarthrosis after a femoral neck fracture and those showing artificial objects were excluded. This yielded a total of 3346 hip images (1773 fractured and 1573 non-fractured hip images) that were used to compare performances between the convolutional neural network and five orthopedic surgeons.

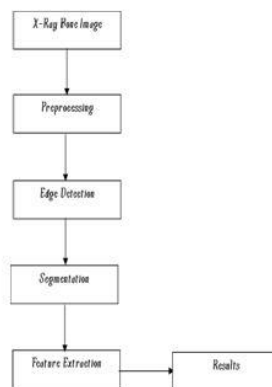
D ImageNet Classification with Deep Convolutional Neural Networks

Artificial intelligence using convolutional neural networks (CNNs) is used in image analysis. The algorithm identified the previously-identified regions of interest to detect distal radius fractures (DRFs) on anterior-posterior (AP) wrist radiographs. A total of 2,340 patients were enrolled in this study, and 340 AP wrist radiographs were obtained from those patients. The IOU (intersection of the union) was interested in the feasibility of the object detection algorithm. The diagnostic performance of the network was measured using different factors like the area under the receiver operating characteristic curve (AUC), accuracy, sensitivity, specificity, and the Youden index, and the results were compared with the actual data set. The object detection model achieved a high average IOU, and none of the IOUs had a value less than 0.5. The AUC of the CNN for this test was 0.96. The network had better performance in distinguishing images with DRFs from normal images compared with a group of radiologists in terms of accuracy, sensitivity, specificity, and the Youden index. The network exhibited a diagnostic ability similar to that of the orthopedists in terms of the above-mentioned variables. A superior performance was observed to that of the radiologists in distinguishing AP wrist radiographs with DRFs from normal images.

III.METHODOLOGY

The initial step was to apply pre-processing methods like conversion of RGB to Grayscale and improving them through filtering algorithms for removing image noise. Then, detect its

edges in an image using edge detection and segment it further. Post segmentation, every image is converted into a series of functions by making use of a feature extraction technique. So, a classification algorithm was formed depending on the extracted characteristics. The method was then checked for its accuracy.



A PREPROCESSING

It is a technique for changing any image in a digital type for performing any operations for obtaining an enhanced type of image on some associated degree. This is a sort of signal transmission where the image is used as an input such as a photograph, where the output is often a characteristic image linked to the input.

B EDGE DETECTION

The edges area element placed within the image with a robust distinction of intensity. Since edges usually occur at the positions of pictures that represent the boundaries of objects, edge detection is wide utilized in segmenting pictures after you need to divide the image into areas similar to totally different objects. Representing a picture by its edges has the additional benefit of considerably reducing the number of knowledge whereas keeping most of the data regarding the image. Since the perimeters consist principally of high frequencies, discover the sides by applying a high pass frequency filter by rotating the image with associate acceptable core within the abstraction domain.

C SEGMENTATION

Picture division is the essential development to separate the image furthermore, remove data from them. It is a movement of distributing picture into a social affair of related arrangements of pixels. The essential inspiration driving the division method is to get more information in the region of energy for an image which assistants in clarification of the thing scene. There are three essential strategies of picture the division which are region approach, limit approach also, edge approach. In this work, edge based-based the division is used which is dynamically proper for bone picture. Edge acknowledgment is one of the most generally used assignments in applications that require deciding articles' breaking points in a picture. It relies upon inspecting the changes in the power in the image. In this paper, the Canny methodology is used to make an extraordinary point of view on the bone structure.

IV. RESULTS

When compared to existing algorithms, the RFA Algorithm produces more accurate results. In this proposed work, only analyzing a dataset can give an accurate result, but here the input data has been passed and the predicted output will be the result, i.e., given an X-ray image of a fractured bone, the end of the fracture will be marked with a bounding box and it will be destroyed. The level of accuracy of this detection method in fracture is possible or not, therefore to overcome the existing process.




Fig 1. Fractured Bone

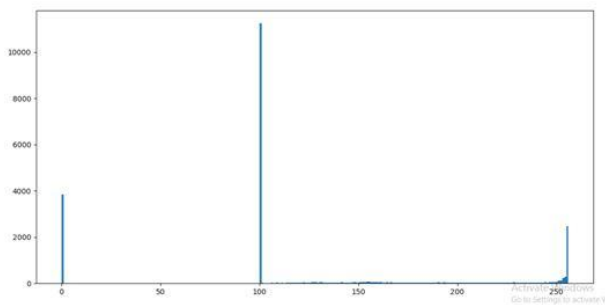


Fig 2. The graph analyzes the severity of a fractured bone and is surrounded by a bounding box.

IV. CONCLUSION

In this research article, many imaging techniques were researched, like edge detection, image segmentation, computer-aided diagnosis, etc. Finally, these parameters explain the applicability of image processing methods. The main objective of this work is to provide a more accurate and effective technique that takes less time to recognize bone fractures in the body.

REFERENCES

- [1] Chi-Tung Cheng, Tsung-Ying Ho, "Application of a deep learning algorithm for detection and visualization of hip fractures on plain pelvic radiographs" *Journal of Eur Radiol* 2019 Oct;29(10):5469-547.
- [2] N. Uma devi ; S.N. Geethalakshmi "Multiple classification system for fracture detection in human bone x-ray images" *journal of ieee*, July 2012,13252130.
- [3] Alireza Borjali , Antonia F Chen , "Comparing the performance of a deep convolutional neural network with orthopedic surgeons on the identification of total hip prosthesis design from plain radiographs" *journal of Med Phys* 2021 May;48(5):2327-2336.
- [4] Klemt, Christian PhD; Uzosike, "The Ability of Deep Learning Models to Identify Total Hip and Knee Arthroplasty Implant Design From Plain Radiographs" *journal of J Am Acad Orthop Surg* 2022 May 1;30(9): 409-415.doi: 10.5435/JAAOS-D-21-00771. Epub 2022 Feb 8.
- [5] Roy, S.; Bandyopadhyay, S.K. "A new method of brain tissues segmentation from MRI with accuracy estimation. *Journal of Procedia Computer Science.*" 2016, 85, 362–369.
- [6] Gulshan, V.; Peng, L, "Development and Validation of a Deep

Learning Algorithm for Detection of Diabetic Retinopathy in Retinal Fundus Photographs." *JAMA* 2016, 316, 2402–2410.

- [7] Roy, S.; Whitehead, T.D., "Optimal co-clinical radiomics: Sensitivity of radiomic features to tumour volume, image noise and resolution in co-clinical T1-weighted and T2-weighted magnetic resonance imaging". *eBioMedicine* 2020, 59, 102963.
- [8] David W G Langerhuizen , Anne Eva J Bulstra , "Is Deep Learning On Par with Human Observers for Detection of Radiographically Visible and Occult Fractures of the Scaphoid?" 2020 Nov;478(11):2653-2659. doi: 10.1097/CORR.0000000000001318.
- [9] Zhou, J.; Moses, D.; Dawes, L. "Using Convolutional Neural Networks and Transfer Learning for Bone Age Classification." In *Proceedings of the 2017 International Conference on Digital Image Computing: Techniques and Applications (DICTA)*, Sydney, Australia, 29 November–1 December 2017; pp. 1–6.
- [10] Anand, I.; Negi, H.; Kumar, D.; U-Net "Deep Learning Model for Breast Tumor Segmentation. In *Magnetic Resonance Images; Computers, Materials & Continua, Tech Science*" Press: Henderson, NV, USA, 2021; Volume 67, pp. 3107–3127.
- [11] Roy, S.; Whitehead, T.D.;L.;"Co-clinical FDG-PET radiomic signature in predicting response to neoadjuvant chemotherapy in triple-negative breast cancer." *Eur. J. Nucl. Med. Mol. Imaging* 2022, 49, 550–562.Diagnosics 2022, 12, 2420 16 of 1
- [12] Krupinski, E.A.; Berbaum, K.S.; "Long Radiology Workdays Reduce Detection and Accommodation Accuracy". *J. Am. Coll. Radiol.* 2010, 7, 698–704.
- [13] Shah, P.M.; Ullah, H.; Ullah, R.; Shah, D.; "Rodrigues, C. DC-GAN-based synthetic X-ray images augmentation for increasing the performance of Efficient Net for COVID-19 detection." *Expert Syst.* 2022, 39, e12823.
- [14] Sanaat, A.; Shiri, I.; Ferdowsi, S.; Arabi, H.; Zaidi, H. "Robust-Deep:A Method for Increasing Brain Imaging Datasets to Improve Deep Learning Models' Performance and Robustness." *J. Digit. Imaging* 2022, 35, 469–481.
- [15] Roy, S.; Shoghi, K.I. "Computer-Aided Tumor Segmentation from T2-Weighted MR Images of Patient-Derived Tumor Xenografts. In *Image Analysis and Recognition ICIAR*" 2019. *Lecture Notes in Computer Science; Karray, F., Campilho, A., Yu, A., Eds.; Springer: Cham, Switzerland, 2019; Volume 11663.*
- [16] Roy, S.; Mitra, A.; Roy, S.; Setua, S.K. "Blood vessel segmentation of retinal image using Clifford matched filter and Clifford convolution". *Multimed. Tools Appl.* 2019, 78, 34839–34865.