



# DISCOVERY OF A BILATERAL HIP OSTEONECROSIS AND BONE INFARCTS IN A YOUNG FEMALE PATIENT WITH KNEE PAIN

A.NEJMEDDINE, K. BERRADA, H. TABAKH, N. TOUIL, N. CHIKHAOUI

Emergency Radiology Department of Universitary Hospital Ibn Rochd, Casablanca

## ABSTRACT

**PURPOSE:** This case report aims to discuss the rare occurrence of bilateral osteonecrosis and the utility of imaging in its diagnosis and management.

**PRESENTATION OF CASE:** A 30-year-old young female presented to the department with chronic left knee pain. She was diagnosed with bone infarcts based on MRI findings, and whose CT scan that was requested for further diagnostic work showed bilateral hip osteonecrosis et diffuse bilateral bone infarcts. We learned then that the patient was taking oral steroids for years for aesthetic purpose.

**DISCUSSION:** Magnetic resonance imaging (MRI) is the gold standard for detecting the earliest stages of osteonecrosis for its high sensitivity and specificity.

It can assert the diagnosis with certainty by showing the band like pathognomonic lesions and can be used to establish a classification (Ficat) for the femoral head involvement.

The treatment is based on hygienic measures, followed by decompression surgery and possibly prosthetic replacement.

**CONCLUSION:** Glucocorticoid-induced osteocyte apoptosis accumulates and can lead to osteonecrosis, even without osteoporosis. The risk of osteonecrosis increases with increasing dose and duration of treatment and dexamethasone may be the worst culprit. MRI is the gold standard for the diagnosis of osteonecrosis, and the radiologist is required to know all the aspects of this pathology in order to be an active part of an early treatment.

This case report discusses a rare case of bilateral osteonecrosis in a 30 years-old female patient, and highlights the diagnostic and management utility of imaging.

**Keywords:** Osteonecrosis, Bone infarct, MRI, Imaging, Edema, Surgery

**Introduction :**

Aseptic osteonecrosis of the femoral head has various clinical manifestations, depending on its location, but has in common a histopathological and radiological substrate, with MRI being the non-invasive imaging technique with the highest degree of specificity and sensitivity used in its diagnosis.[1]

**Presentation of the case :**

A 30 years old female with chronic left knee pain was prescribed an MRI. She had no history of trauma, no said long term medication, infection, or other pathology. She described inflammatory left knee pain irradiating to the ipsilateral hip, partially responding to analgesic treatment, but quickly recurrent, evolving for 6 months.

MRI found intramedullary bone anomalies on both sides of the joint, on the femoral and tibial diaphyses, and on both femoral condyles.

These lesions formed serpiginous lines, hypointense in T1 with visualization of a double line on T2 sequences : an internal hyperintense line (granulation) and a peripheral hypointense line of osteosclerosis (Figure 1).

Anterior Cruciate Ligament and Posterior Cruciate Ligament were of normal volume and signal, without visualization of lesions at their insertion sites.

No significant joint effusion or menisco-ligament anomaly of the left knee were found.

We completed the patient's assessment with a CT scan of both lower limbs given the nature of the lesions and the hip pain, that showed other lesions of similar morphology, bilateral and relatively symmetrical (Figure 2), with damage to both femoral heads, marked on the left side where there was a loss of sphericity of the femoral head, with joint pinching, associated with subchondral condensations and geodes (Figure 3).

Further investigation with the patient found a history of self-medication with oral steroids for aesthetic purpose (weight gain). [1], [2]

We concluded to an MRI appearance in favour of bone infarcts in the context of diffuse and bilateral avascular onecrosis (discovered on complementary CT scan) affecting both femoral heads, at the stage of coxarthrosis in the left side (grade IV of the Ficat classification).

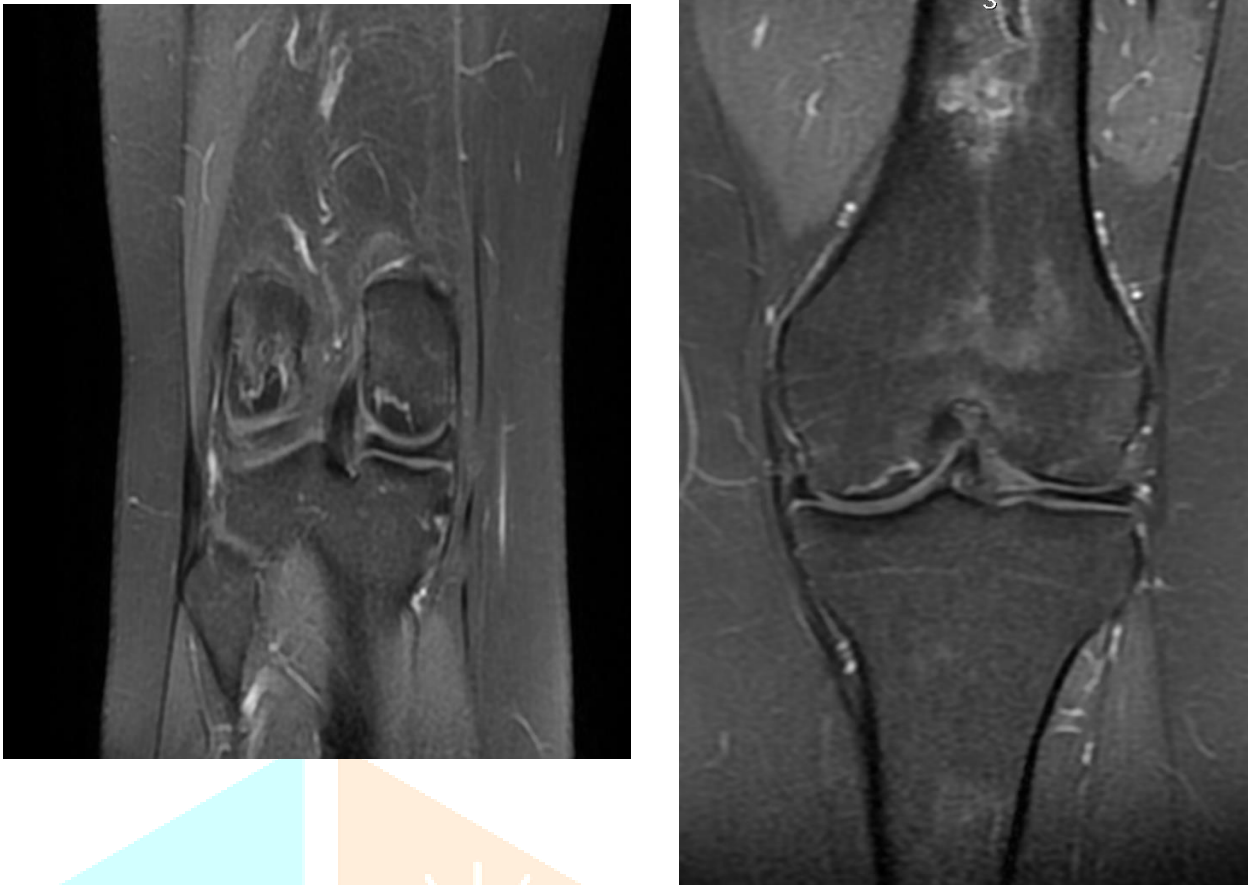


Figure 1 : serpiginous bone lesions with two peripheral lines of different signal

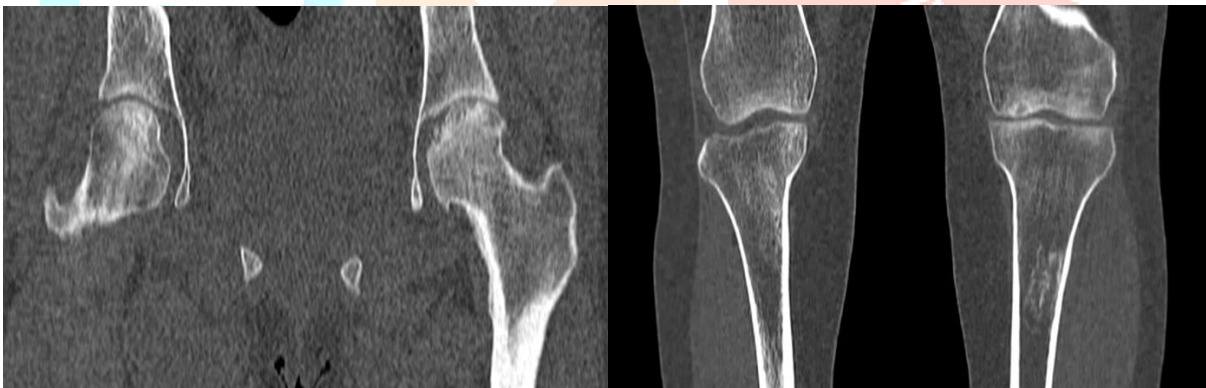

Figure 2 : bilateral damage of the knees and hip involvement

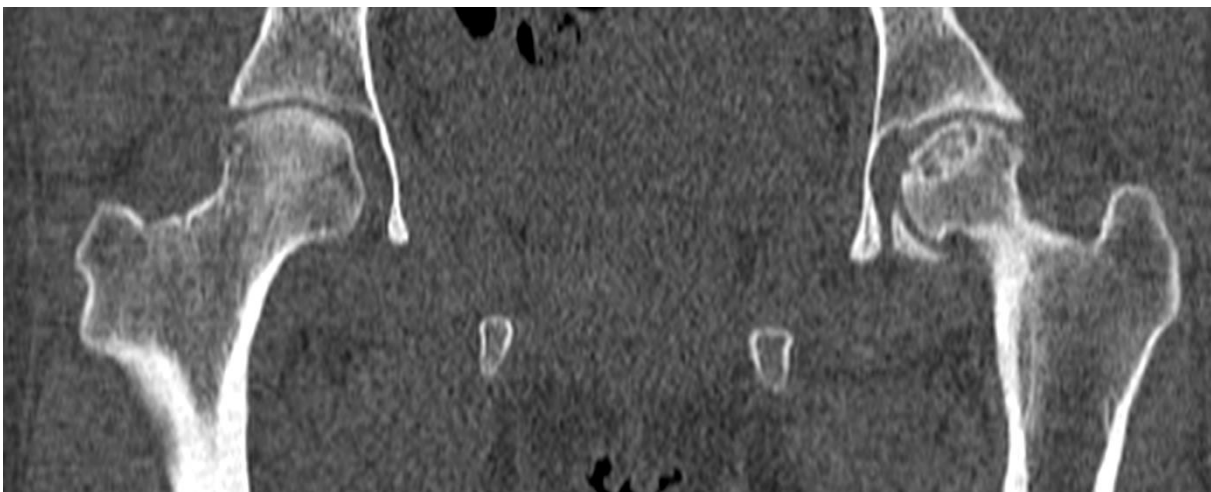


Figure 3 : bilateral hip osteonecrosis marked on the left side, with joint pinching, associated with subchondral condensation and geodes (Ficat classification : stage 4)

**Discussion :**

Non-traumatic osteonecrosis of the femoral head (ONFH) usually affects adults younger than 50 years and frequently leads to femoral head collapse and subsequent arthritis of the hip. Clinicians should enhance their precaution awareness of corticosteroid-induced ONFH.[3] MRI T1-weighted double-line sign of avascular necrosis of the femoral head is the most pathognomonic. [4] Similar cases were also reported.[5]

The annual incidence of all types of osteonecrosis doubled from 1989 to 2003 (from 1.4 to 3/100,000), perhaps due to the more frequent use of MRI [6]. Most commonly, the hip is involved but almost any bone can develop osteonecrosis. The most frequent etiological factors are trauma, alcoholism, and glucocorticoids, the later causing the most devastating form of osteonecrosis [7]. Other causes include sickle cell disease, radiation, Gaucher's disease, and Caisson disease (decompression sickness) [8]. In glucocorticoid-induced osteonecrosis, the risk increases with higher doses and prolonged treatment [8], although it may occur after short-term exposure to high doses, by intra-articular injection, and without osteoporosis. Intra-articular glucocorticoids may be particularly dangerous because the injection may accelerate joint damage by alleviating pain, thus increasing weight bearing—a kind of Charcot's arthropathy, in addition to the direct adverse effects of the steroids on bone [9, 10].

Typical clinical signs of ON are pain in the groin, thigh or buttock. Pain can occur during weight-bearing activities as well as at rest, or it can be induced by motion. Only few patients are asymptomatic. A new classification of ON has been developed by the Association of Research on Osseous Circulation (ARCO) [11]. Stage 0 is only detectable by histology. In the early stage, ARCO Stage 1, ON is reversible and can be detected by magnetic resonance imaging (MRI) and scintigraphy; X-ray examination is insufficient to detect ON in this reversible stage. Detection at this stage is crucial, as ARCO Stage 2, which is the first X-ray detectable stage, is already irreversible. The crescent sign in ARCO Stage 3 represents a separation of the subchondral plate from the underlying necrotic cancellous bone and becomes evident on MRI and radiographs (Figure 1). Stage 4 implies joint destruction and secondary arthritis of the hip.

Magnetic resonance imaging (MRI) is the gold standard for detecting the earliest stages of osteonecrosis, due to multiple studies displaying >99 % specificity and sensitivity [12]. A band-like lesion showing a low intensity signal on T1-weighted images is usually pathognomonic for this disease [13]. In addition to the pathognomonic band-like lesion, bone marrow edema has been discussed as a potential early finding indicative of ischemia.

Osteonecrosis occurs predominantly in younger patients and, therefore, efforts should be made to preserve the joint and delay hip replacement. The first approach is usually to reduce weight bearing using canes, crutches, or a walker for about 6 weeks. Another approach is core decompression with or without marrow cell transplantation, which also requires 6 weeks of reduced weight bearing. For advanced disease with obliteration of the acetabular articular space and osteophyte formation, femoral head or total hip replacement is usually required.

**Conclusion :**

Glucocorticoid-induced osteocyte apoptosis accumulates and can lead to osteonecrosis, even without osteoporosis. The risk of osteonecrosis increases with increasing dose and duration of treatment and dexamethasone may be the worst culprit.

MRI is the gold standard for the diagnosis of osteonecrosis, and the radiologist is required to know all the aspects of this pathology in order to be an active part of an early treatment.

**Bibliography :**

1. Trăistaru, MAGDALENA-RODICA, et al. "Imaging and histopathological aspects in aseptic osteonecrosis of the femoral head." *Rom J Morphol Embryol* 56.4 (2015): 1447-1453.
2. Hauzeur, Jean-Philippe, Michel Malaise, and Viviane De Maertelaer. "A prospective cohort study of the clinical presentation of non-traumatic osteonecrosis of the femoral head: spine and knee symptoms as clinical presentation of hip osteonecrosis." *International orthopaedics* 40 (2016): 1347-1351.
3. Chancelier, M. D., et al. "Aseptic osteonecrosis of the knee induced by corticoids. MRI aspects." *Journal de Radiologie* 73.3 (1992): 191-201.
4. Zalavras, Charalampos G., and Jay R. Lieberman. "Osteonecrosis of the femoral head: evaluation and treatment." *JAAOS-Journal of the American Academy of Orthopaedic Surgeons* 22.7 (2014): 455-464.
5. Weinstein, Robert S. "Glucocorticoid-induced osteonecrosis." *Endocrine* 41.2 (2012): 183-190.
6. C.C. Cooper, M. Steinbuch, R. Stevenson, R. Miday, N.B. Watts, The epidemiology of osteonecrosis: findings from the GPRD and THIN databases in the UK. *Osteoporos. Int.* 21, 569–577 (2010)
7. H.F. Mankin, Nontraumatic necrosis of bone (osteonecrosis). *N. Engl. J. Med.* 326, 1473–1479 (1992)
8. W. Drescher, G. Schlieper, J. Floege, F. Eitner, Steroid-related osteonecrosis—an update. *Nephrol. Dial. Transplant.* 26, 1728–2731 (2010)
9. C.N. Chandler, V. Wright, Deleterious effect of intra-articular hydrocortisone. *Lancet* ii, 661–663 (1958)
10. G.S. Habib, W. Saliba, M. Nashashibi, Local effects of intraarticular corticosteroids. *Clin. Rheumatol.* 29, 347–356 (2010)
11. Pierce, Todd P., et al. "Imaging evaluation of patients with osteonecrosis of the femoral head." *Current reviews in musculoskeletal medicine* 8 (2015): 221-227.
12. Chancelier, M. D., et al. "Aseptic osteonecrosis of the knee induced by corticoids. MRI aspects." *Journal de Radiologie* 73.3 (1992): 191-201.
13. Saini, A., and A. Saifuddin. "MRI of osteonecrosis." *Clinical radiology* 59.12 (2004): 1079-1093.

