



EMERGENCY EXPLORATORY LAPAROTOMY UNDER SEGMENTAL SPINAL ANAESTHESIA: A UNIQUE APPROACH

Dr. Shivaji Sonone, Dr. Harsha Deshpande, Dr. Prakash Survade, Dr. Venkata Satish Pattipati

(3rd yr Junior Resident)

(3rd yr Junior Resident)

(Professor)

(Senior Resident)

Department of Anaesthesia

Dr. Ulhas Patil medical College and hospital, Jalgaon, India

ABSTRACT:

Segmental Spinal anaesthesia is reported to be having excellent results in terms of post-operative pain, analgesia requirement, relatively less complications in several comorbidities and reduced hospital stay. It is blocking of the required dermatomes essential for the proposed surgical procedure with very low local anaesthetic drug dose. This requires Dural puncture at thoracic or higher lumbar levels. We conducted a case of a patient posted for emergency exploratory laparotomy with known case of hypertension and COPD with active lower respiratory tract infection under Segmental spinal anaesthesia. Subarachnoid block was given with 27 gauge spinal needle at level of T9-T10 by central approach. Throughout procedure patient was hemodynamically stable. After surgery, B/L Transverse abdominis plane block (TAP block) & Rectus Sheath Block (RSB) was given for postoperative analgesia.

KEYWORDS:

Segmental spinal, Exploratory laparotomy, Thoracic spinal, levobupivacaine

INTRODUCTION:

Segmental anaesthesia is blocking of the required dermatomes essential for the proposed surgical procedure with very low local anaesthetic drug dose. This requires Dural puncture at thoracic or higher lumbar levels rather than conventional spinal below L1. Lower the dose of local anaesthetic drug used more likely to produce true segmental block. It provides good hemodynamic stability, minimal motor block, faster recovery, early mobility and early voiding. Exploratory laparotomy is conventionally induced under general anaesthesia. However, it is associated with complications like hemodynamic instability, prolonged hospital stay, delayed recovery. Also, segmental spinal is a better choice particularly in those who have coexistent respiratory and cardiac comorbidities.

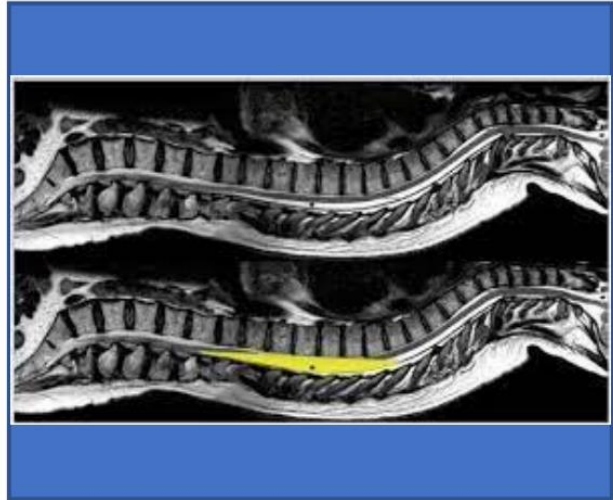
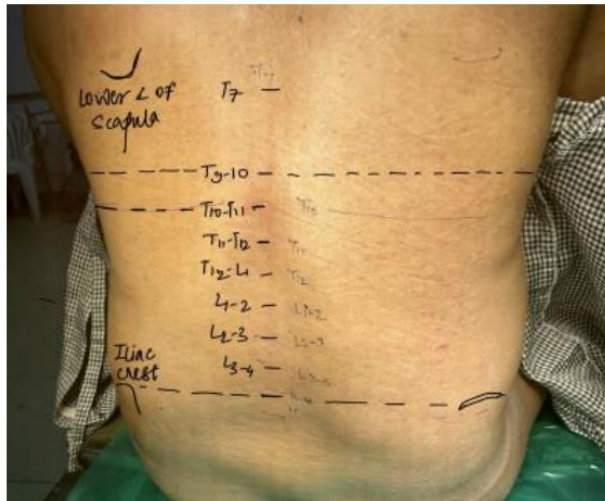CASE REPORT:

54 year old male, resident of Jargon, farmer by occupation, came with accidental perforation injury (fall on a sharp object); patient was to be taken for emergency exploratory laparotomy.

H/o cough since 10 days and cold since 4 days. H/o tobacco chewing and smoking since 20 years. H/o hypertension since 6 years (was taking amlodipine 10mg BD) No history of allergy. No previous medical and surgical history.

On examination, General condition – fair; Pallor/icterus/cyanosis/clubbing/oedema – Not present Height -170cm, Weight -86kg. BMI -29.75 Vitals – Pulse -110 beats per minute ,BP – 150/98 mmhg , RR – 22 per minute , Saturation – 96 % on air.

Airway assessment : Intact teeth, Mouth opening-2 fingers, MPC grade -III, □ Systemic examination: - Respiratory system: Air entry bilaterally equal, bilateral wheeze present - CVS :S1S2 present, No murmurs present - CNS : concious,well oriented, bilateral reflexes present, tone and power - normal - P/A :tenderness & guarding present, perforation wound present over left lumbar region of size 2*3cm. Investigations: HB-10.2,platelets-2,83,000; all other investigations were normal. Chest xray – showed COPD like changes. ECG – sinus rhythm.



Written and informed consent was taken.{relatives were also informed about possibility of conversion to general anaesthesia}.Patient was given nebulization with levosalbutamol and budesonide.After taking patient in OT, multipara monitor was attached.(Heart rate,SBP,DBP,MAP,SPo2 and ECG were recorded).IV line was secured by intracath no.20. Patient was premedicated with inj.ondansetron, inj.pantoprazole. Patient was preloaded with crystalloid {1RL}.

Patient was given sitting position to avoid potential rotation of spine associated with lateral decubitus position. Insertion level (T9-T10) was identified by palpation and use of anatomical landmarks to identify the corresponding spinous process. Under all aseptic precautions, painting and draping was done. Subarachnoid block was given with 27 gauge spinal needle at level of T9-T10 by central approach.2ML of 0.5% Isobaric levobupivacaine with addition of 25 Micrograms of fentanyl was given intrathecally. After injecting the drug, the patient was placed in supine position. No manipulation of position was required as the drug was isobaric. Sensory action was assessed by pinprick scale.

Dermatomes -- T2 (2+), T4 (3+) to L1 (3+) level achieved. Patient was able to move his ankle and toes. Duration of surgery – 2.30 hrs. (primary closure of perforation done); intraoperatively Vasopressors and opioids were not required. Throughout procedure patient was hemodynamically stable. After surgery, B/L Transverse abdominis plane block (TAP block) & Rectus Sheath Block (RSB) was given for postoperative analgesia. Patient was shifted to PACU for further observation and monitoring.

DISCUSSION:

As the patient has COPD (h/o smoking) and h/o cough and cold; segmental spinal anaesthesia was preferred over GA. Also patient is case of perforation and k/c/o hypertension; hence there was concern of haemodynamic stability.

Low dose blocks sensory nerves in preference to motor ones. This tends to preserve muscle tone and power in the legs and provides slightly less relaxation which does not seem to be an obstacle for successful surgery. Fentanyl, when used as an adjuvant increases sensitivity of blockade.

Anaesthesiologists are hesitant to perform spinal anaesthesia above the termination of the conus medullaris due to anticipation of injuring the spinal cord. However, thoracic spinal anaesthesia has been demonstrated as a safe and effective method for various surgeries.

Anatomical studies have been performed using MRI to better define the space within the spine for regional anaesthesia. These MRI images have shown that the mid to lower thoracic segment of the cord lies anteriorly, where there is a CSF field space between the Dura and the cord.

Segmental spinal anaesthesia offers benefits like better analgesia than opioids and decreases perioperative opioid requirement. There is an early recovery of bowel function and decrease complications which results in a shorter length of in hospital stay and patient satisfaction. As anaesthetic dose is lower, so haemodynamic instability becomes minimal. This technique has made it possible to perform certain major operations on and awake at high risk for morbidity and mortality under general anaesthesia.

Hence, Segmental spinal anaesthesia as a newer modality of induction is safe for major abdominal surgeries like exploratory laparotomy, especially in those patients who have other co-morbidities. Segmental anaesthesia is associated with comparatively less postoperative respiratory complication, early ambulation and reduced duration of hospital stay as compared to general anaesthesia.

REFERENCES:

1. Ellakany MH. Thoracic spinal anesthesia is safe for patients undergoing abdominal cancer surgery. *Anesth Essays Res.* 2014 May-Aug;8(2):223-8. [PMC free article] [PubMed]
2. Imbelloni LE, Quirici MB, Ferraz Filho JR, Cordeiro JA, Ganem EM. The anatomy of the thoracic spinal canal investigated with magnetic resonance imaging. *Anesth Analg.* 2010 May 01;110(5):1494-5. [PubMed]
3. Yusuf GT, Lasheen AE. General anaesthesia versus segmental thoracic or conventional lumbar spinal anaesthesia for patients undergoing laparoscopic cholecystectomy. *Anesth Essays Res* 2012;6:167– 73.

