



Corneal bee sting : a case report

Authors: MRAD Khalil , BOUSLAMTI Ahmed , SERGHINI Louay , Abdallah El hassan , Berraho Amina

Department of Ophthalmology B, Ibn Sina Hospital, University Mohamed V, Rabat, Morocco.

ABSTRACT:

Retained bee stinger after corneal sting is a rare accident responsible for a variety of clinical responses reflecting various pathogenetic mechanisms due to the venom rather than the stinger itself , Early detection of potential complications and the right care may help prevent irreversible vision loss, Removal of a retained corneal bee stinger still controversial , thus we present a case of a 46 years old man who presented to our ophthalmology department after a bee sting , this report highlights the management of a rare injury and its pathogenesis .

INTRODUCTION:

Bee sting entrance in the cornea is an uncommon, visual-compromising condition[1] When they occur ocular complications are broad and unpredictable, Locally, damage occurs through immunologic and toxic responses ,commonly because of the toxin rather than to the sting[2].

Here we report a case of a bee sting to the cornea, with retained stinger, and discuss pathophysiologic mechanisms of lesions and management of these cases.

CASE REPORT:

46 years-old man presented to our ophthalmology department for tearing, blurred vision, pain and conjunctival hyperemia of the left eye, the patient reported a bee stinger 24 hour earlier while driving his motorcycle, he denied any medical background notably no antecedent history of allergy.

The patient underwent a complete ophthalmic examination , the finding of the right eye was normal while the left eye showed a visual acuity at 2/10, the eyelid was normal , The extraocular muscles were intact ,a conjunctival hyperemia was noticed , The biomicroscopical examination of the cornea demonstrate a paraxial white corneal infiltration with edema measuring 3 mm in diameter, this edema was located largely in the epithelium and anterior stroma , in the center of the corneal infiltrate two stingers was seen just protruding from the anterior chamber, far away from the iris and the lens, there was no keratic precipitates, the depth of the anterior chamber was normal with no leakage from

the stings area , and a 1 + flare ,the iris was normal with round and responsive pupil, the lens was clear, the iop was 17 mmhg , the fundus also was normal.

An oct was performed and showed the path of the stings piercing the endothelium; however the stingers were not well visualized.

The stingers were removed surgically , under general anesthesia , a corneal strumming of the infiltrated zone was made, one sting was gently removed , while the other one was brittle, and we were obliged to perform a corneal incision to remove it from the anterior chamber , after the stingers removal a sieidel was noticed so we suture the wound with 10/0 nylon (2 stitches), the anterior chamber was cleaned by irrigation and aspiration with balanced salt solution(BSS), an intracameral injection of cefuroxime was made, and the incision was hydrosutured. Postoperatively the patient was treated with systemic and topical antibiotics and steroids plus cycloplegics.

DISCUSSION:

Isolated bee sting injury to the eye is probably an uncommon event. The ocular morbidity related with this injury would rely upon the interplay between the nature and toxicity of the venomous poisons expounded by the constituents of the bee and the resulting inflammatory response of the patient. The side effects can vary from an insignificant bothering to a significant reduction of vision [3].

A husk or outer covering and two barbed "spears" that slide partially inside the husk make up the bee stinger. The spears can be removed from the husk easily and may stay where they stung [4].A stinger may remain inert in the cornea for a long time, but more often it causes, an intense inflammatory reaction [5]. The fluctuation of the reaction is remembered to mirror the amount of toxin infused [6].

Reactions from a retained stinger are thought to be secondary to released toxins rather than the stinger itself [7]. Animal studies and earlier case reports have demonstrated that the stinger is inert and can be kept in the cornea without causing harm after the venom is inactivated [6][8].

The components of the bees venom have different degree of severity when they react with various eye tissues, particularly when combined with an intact stinger [6]. The biologic amines including dopamine and histamine induce vasodilatation leading to chemosis and congestion [9]. The nonenzymatic polypeptide toxins, mast-cell degranulating peptide, apamin (neurotoxin) and mellitin(most effective and more than 50%)[6], are responsible for direct hemolysis, membrane disruption, and protein's denaturation which in turn cause, cataract, , lens subluxation, zonulolysis and endothelial cell damage [10]. The high molecular weight enzymes like hyaluronidase and phospholipase A and B degrade the chromatophores of anterior iris layers which appear as heterochromia [11], they are also responsible for a type 1 hypersensitivity response [6]. The production of different chemotactic proteins and anaphylotoxins as a result of the immune response in the cornea causes an accumulation of inflammatory cells and, eventually, cell death. Clinically, this appears as a corneal edema and sterile infiltration surrounding the stringer [12]. The endothelial cell density decreases later at a late stage [13]. Optic neuritis, Uveitis, external and internal ophthalmoplegia, papillitis and optic atrophy, are some of the other complications that have been documented in the literature [1]. Although the reaction to a corneal bee sting is typically local, previously exposed people always run the risk of a widespread reaction [14].

Concerning the management of these cases some authors have suggested that no surgery is required if the stinger still inert and causes no symptoms [8].However operative intervention may be necessary to correct visual defects if the stinger is associated with corneal deficiencies [9]. For outpatient therapy, cycloplegics (if iritis is obvious) and analgesics should be prescribed. Topical corticosteroids are often required for the treatment of iritis, even though there are worries that their use may increase susceptibility to infections [15][16]. Oral antibiotics or ophthalmic antibiotics drops are indicated because 14% of cases involve the culture of bacteria from intraocular foreign bodies [17]. Corneal bee stings have been related to infectious complications such as hypopyon and mucopurulent

keratoconjunctivitis [8][12]. Although pseudomonas infection has been reported following corneal bee stings, coagulase-negative Staph. Aureus may be the most often cultured bacteria attributed to ocular foreign bodies. This suggests that broad-spectrum antibiotics should be prescribed [17][18].

CONCLUSION:

Corneal bee stings, with or without retained stingers, are rarely documented environmental accidents that have the potential to cause insult ranging from mild to severe and persistent [6][11]. These stings are unusual in that they can appear as penetrating, toxic or immunologic presentations or as a combination of all three processes. Their management involves early diagnosis, and emergent ophthalmologic treatment.

REFERENCES:

- [1]. Chinwattanakul S, Prabhasawat P, Kongsap P. Corneal injury by bee sting with retained stinger – A case report J Med Assoc Thai. 2006;89:1766–9
- [2]. Lin PH, Wang NK, Hwang YS, Ma DH, Yeh LK. Bee sting of the cornea and conjunctiva: Management and outcomes Cornea. 2011;30:392–4
- [3]. Razmjoo H, Abtahi MA, Roomizadeh P, Mohammadi Z, Abtahi SH. Management of corneal bee sting Clin Ophthalmol. 2011;5:1697–700
- [4]. Root, A. I.: ABC and XYZ of Bee Culture. Medina, Ohio, A. I. Root, 1978, pp. 598 and 599.
- [5]. Duke-Elder, S., and MacFaul, P. A.: Injuries. NonMechanical Injuries. In Duke-Elder, S. (ed.): System of Ophthalmology, vol. 14, pt. 2. London, Henry Kimpton, 1972, pp. 1204 and 1205
- [6]. Smolin G, Wong I. Bee sting of the cornea: Case report Ann Ophthalmol. 1982;14:342–3
- [7]. Tuft SJ, Compton DO, Coster DJ. Insect sting in a cornea. Am J Ophthalmol 1985;99:727-8.
- [8]. Gilboa M, Gdal-On M, Zonis S. Bee and wasp stings of the eye. Retained intralenticular wasp sting: a case report. Br J Ophthalmol 1971;61:662-4.
- [9]. Chen CJ, Richardson CD. Bee sting-induced ocular changes Ann Ophthalmol. 1986;18:285–6
- [10]. Ghosh SK, Chattopadhyay D, Sen AC, Chakrabarti B. Melittin-induced conformational changes in human lens protein Curr Eye Res. 1991;10:1065–8
- [11]. Singh G. Bee sting of the cornea Ann Ophthalmol. 1984;16:320–2
- [12]. Yildirim N, Erol N, Basmak H. Bee sting of the cornea: a case report Cornea. 1998;17:333–4
- [13]. Gürlü VP, Erda N. Corneal bee sting-induced endothelial changes Cornea. 2006;25:981–3
- [14]. Smith, D. G., & Roberge, R. J. (2001). *Corneal bee sting with retained stinger. The Journal of Emergency Medicine, 20(2), 125–128.* doi:10.1016/s0736-4679(00)00298-5
- [15]. Nishimoto JY. Iritis. How to recognize and manage a potentially sight-threatening disease. Postgrad Med 1996;99:255–7, 261–2
- [16]. Newell SW. Management of corneal foreign bodies. Am Fam Physician 1985;31:149–56.
- [17]. DeBroff BM, Donahue SP, Caputo BJ, et al. Clinical characteristics of corneal bodies and their associated culture results. CLAO J 1994;20:128–30.

[18]. Babushkin AE, Gimranov RM. Injury of the cornea by a bee sting complicated by Pseudomonas aeruginosa and herpesvirus infections. Vestn Ophthalmol 1990;106:65

ICONOGRAPHY :

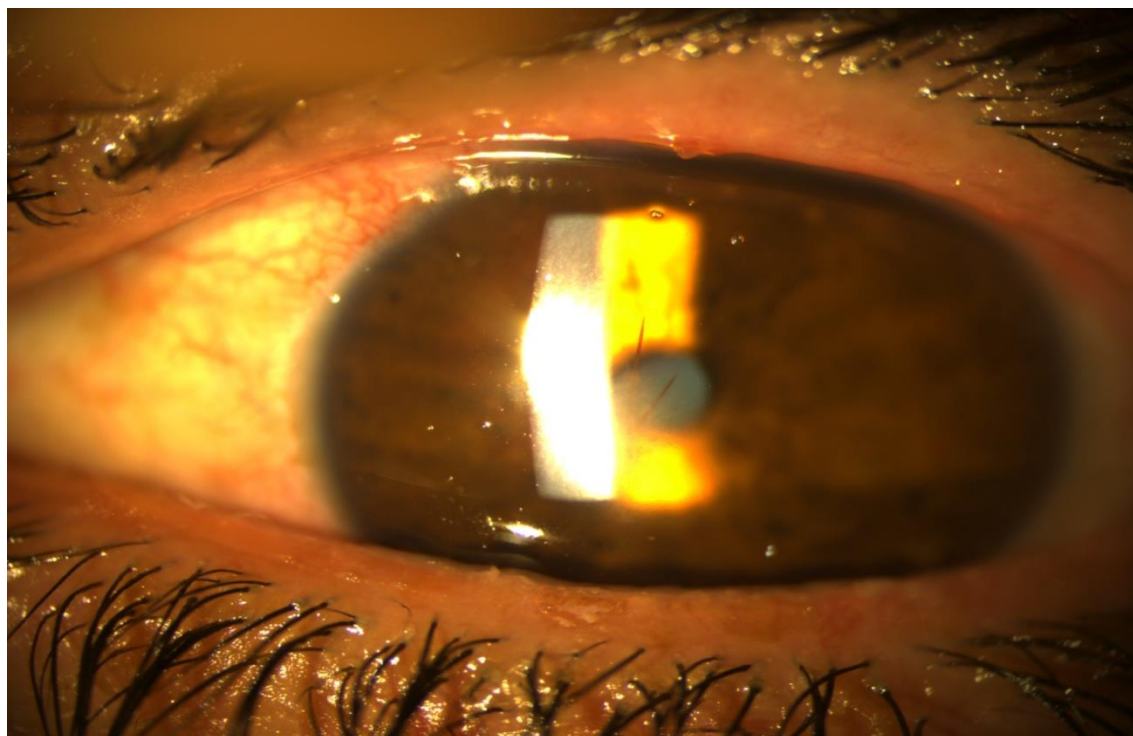


Figure 1: Slit-lamp photograph of the intracorneal stingers

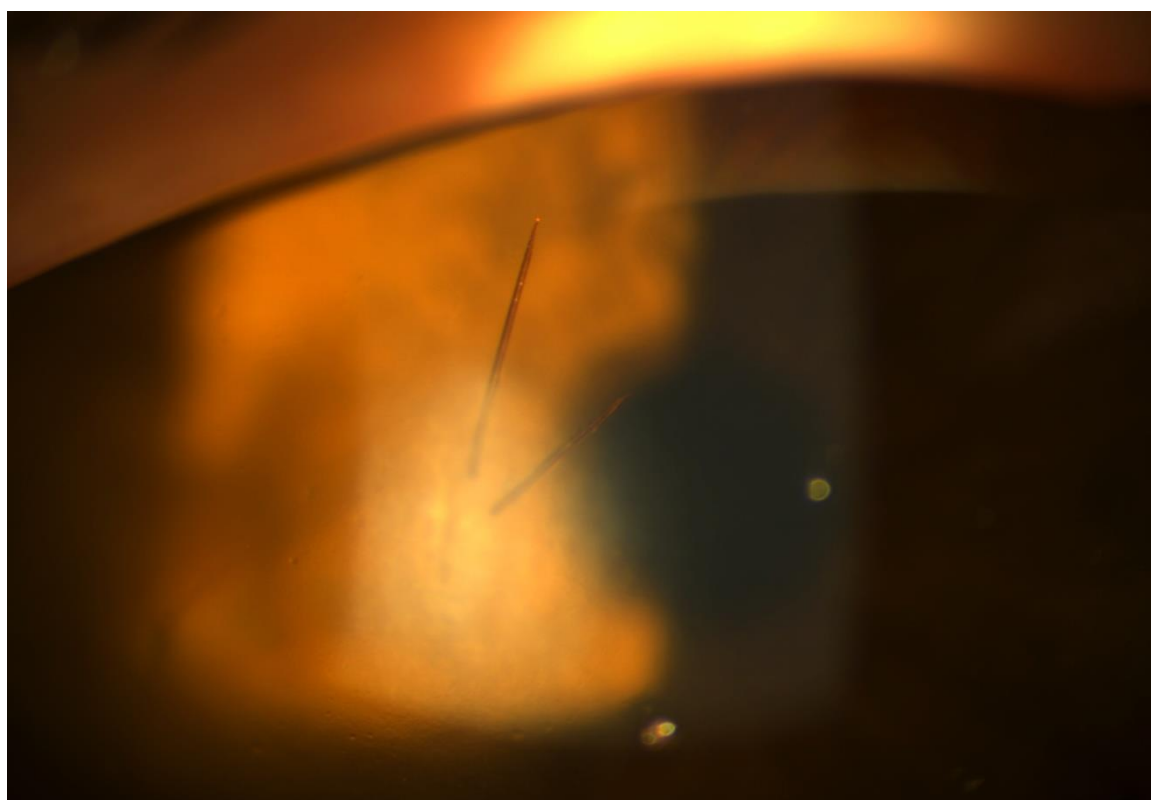


Figure 2: high magnification slit-lamp photograph showing corneal infiltration and edema centred by the stingers

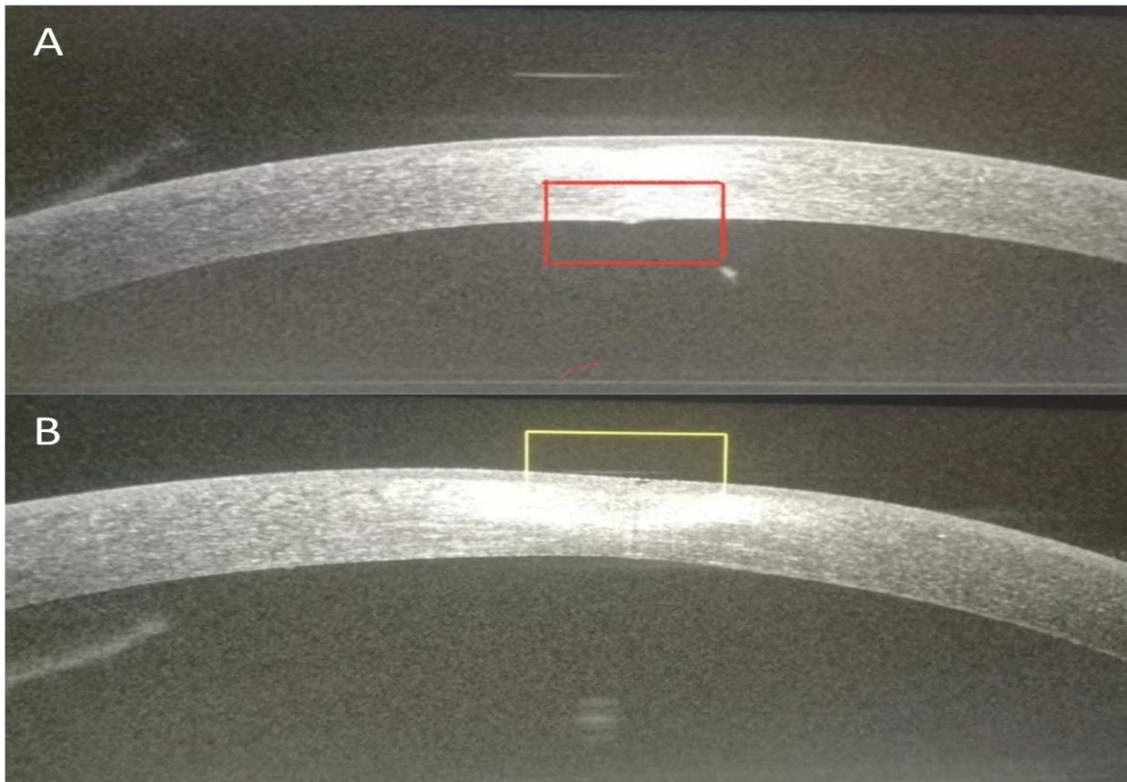


Figure 3: corneal optical Coherence Tomography (oct) **A:** endothelial breach of the stinger
B: epithelial entry point of the stinger