



# INTERNATIONAL JOURNAL OF CREATIVE RESEARCH THOUGHTS (IJCRT)

An International Open Access, Peer-reviewed, Refereed Journal

## RETROSPECTIVE CASES STUDY USING ADVANCED FIBRE DRESSING

(Sayyed Safura Samir, Ghugarkar Prasad Gorakshnath, kundansawale)

B.pharmacy, M. pharmacy, B.pharmacy

Dr.N.J.Paulbudhe collage of pharmacy vasant tekdi, 414003 Ahmednagar, Maharashtra, India

**Abstract:** A retrospective study uses existing data that have been recorded for reason other than research. A retrospective case series is the description of a group of case series is the description of a group of case with a new or unusual disease or treatment. With a case control study, cases with a without the condition of interest is identified, and the degree of exposure to a possible risk factor is then retrospectively compared between the two groups. With a matched case control study, control subject are selected such that they resemble (match) the cases with regards to certain characteristic - example - age, severity of disease. Retrospective study design is generally considered inferior to prospective study design. Therefore, a retrospective study design should never be used when prospective design is feasible.

**Index Terms -** Wound exudates, gelling fibre, Biatain Fiber, Wound edge, Periwound skin, foot, ulcer exudates

Wound exudates is a fundamental part of wound healing, but if it is present in the wrong amount, location, composition, or consistency, it can cause complications, such as infection and damage the peri-wound skin. This may lead to maceration increasing the wound surface area and prolonging healing time

Wound exudates contains a variety of components, including a high level of proteases that degrade proteins (e.g. matrix metalloproteinase's [MMPs]), micro-organisms, substances that can inhibit healing, as well as proteins that promote the growth of bacteria. This leads to an increased infection and subsequent development of bio film if exudates is not effectively managed, exudates can pool at the base of the wound bed. The risk of exudates pooling increases when dead space or a 'gap' forms as a result of the dressing not maintaining direct contact with the wound bed.

The gap presents a clinical challenge as the increased risk of exudates pooling leads to an increased risk of leakage, maceration, and infection, which may delay wound healing. Highly exuding, sloughy and cavity wounds, wounds with undermining and wounds with a steep angle between the wound edge and wound bed, and fistulas are at a higher risk of dead space and exudates pool,

### GELLING FIBRE DRESSING

Gelling fibre dressings are a solution for moderate-to-highly exuding wounds and are a well-accepted treatment option in the management of exudates. Upon exudates absorption, the fibres form a gel that supports autolysis, debridement and tissue granulation, and helps maintain a moist wound environment. However, challenges remain when using gelling fibre dressings,

Not all gelling fibres are effective at absorbing and retaining large amounts of exudates, which can lead to complication.

Some gelling fibre dressings have a surface shrinkage of more than 36% upon wetting which can lead to gap formation, exudates pooling and maceration

Clinicians can often experience issues in removing gelling fibre dressings, such as the dressing breaking removal or leaving residue or debris in the wound, which leads to increased time being required to remove the dressing or deal with resultant issues.

## BIATAIN FIBER WITH HEXALOCK TECHNOLOGY

Biatain Fiber (Coloplast) with HexaLock Technology is a soft gelling fibre dressing with integrated strength, which effectively absorbs and retains large amounts of exudates. The dressing keeps its shape with minimal shrinkage, thereby minimising the risk of gap creation and reducing exudates pooling.

Biatain Fiber can be easily removed in one-piece with minimal risk of leaving residue in the wound. The benefits of Biatain Fiber are enabled by HexaLock Technology, which is a combination of three components: an optimised combination of absorbing carboxymethylcellulose (CMC) gelling fibres and strengthening fibres; thermo bonding that locks the fibres together and a hexagon net applied by ultrasonic embossment.

Biatain Fiber is intended for use as a primary wound dressing for use in highly exuding, sloughy and cavity wounds, including undermining it is available in a square or ribbon variant and can be cut to fit the size of the wound. The choice of secondary dressing will depend on the characteristics of the wound. Covering Biatain Fiber with a conforming foam dressing, such as Biatain Silicone with Technology.

## NEED OF WORK

- THE NEED OF WORK IS TO UNDERSTAND THE IMPORTANCE OF MECHANISM IN HEALING PROCESS.
- THE NEED OF WORK IS TO AVOID NEGATIVE OUTCOMES SUCH AS INFECTION OR SCARRING.
- THE STUDY HELP TO DEFINE PROGNOSTIC FACTOR TO BE USED SO THAT THERAPEUTIC STRAGETORIES MAY VARY DEPENDING ON PREDICTIED RISK.
- IT HELPS TO STUDY A RARE OUTCOME FOR WHICH PROSPECTIVE STUDY IS NOT FEASIBLE.

## INFORMATION

### Case 1-

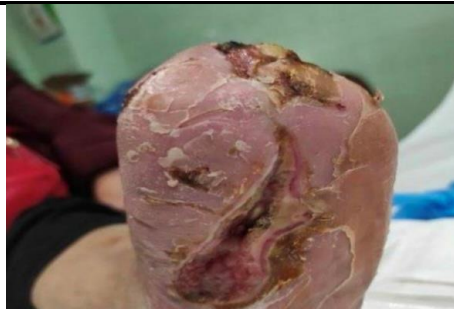The patient was a 65-year-old woman with a history of arterial hypertension, ischemic heart disease and type 2 diabetes, which developed during pregnancy 30 years ago For 7 years, she has had chronic kidney disease and haemodialysis as she was not eligible for kidney transplantation. As a result of diabetic retinopathy, she is blind in one eye. In 2014, the left first, fourth and fifth toes had been amputated.

The patient visited the emergency room for pain in the left foot after sustaining a trauma 2-3 weeks previously. There was an abscess of the third left toe, and the clinical signs of local infection were present (bleeding and purulent material). The patient was urgently admitted to the hospital for monitoring. After 2 days, the wounded area began to bleed and there was an outflow of purulent material.

She had distal pulses and no fever. As three of the toes were amputated in 2014, it was agreed that the remaining second and third toe would also be amputated. On Day 3 of hospital admission, an atypical transmetatarsal amputation was conducted tendons were sectioned, and devitalised and infected tissue removed. plantar area was left open for washing and cleaning.

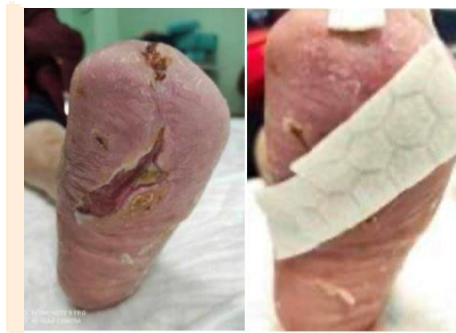The patient was discharged from hospital 10 days after surgery, and on-going treatment was conducted between primary care and the hospital. After 1 month, the wound had not progressed and because of the complex patient and wound needs, the patient was referred to the wound care specialist

The wound was dressed with Biatain Fiber and Biatain Silicone Multishape and dressing change was planned for three times per week. As exudates management and the condition of the wound improved, the plan was to reduce dressing changes to twice a week. The dressings were held in place by an elastic tubular bandage, cotton and crepe. Although the patient was unable to walk, 5 mm felt pads were used to ensure offloading of the wound. In the first 4 weeks of treatment, the wounded area had reduced in size and the condition of the periwound skin improved considerable After approximately 6 weeks,



### The management goals were as follows:

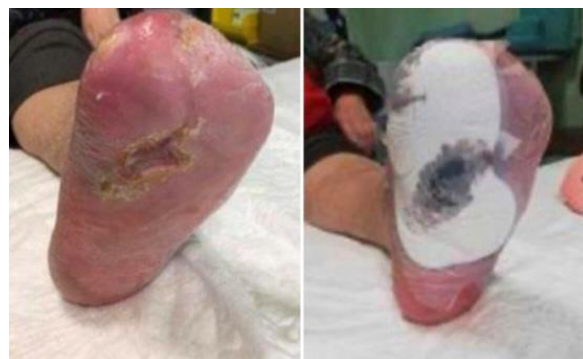- Wound bed: Remove non-viable tissue, manage exudates and protect granulation/epithelial tissue
- Wound edge: Manage exudates, remove non-viable tissue and protect granulation/epithelial tissue
- Periwound skin: Manage exudates, protect skin, rehydrate the skin, and remove non-viable tissue.



### OUTCOME

At presentation to the wound care specialist, this wound had a high level of devitalised tissue and exudates levels were high, increasing the risk of maceration of the periwound skin.

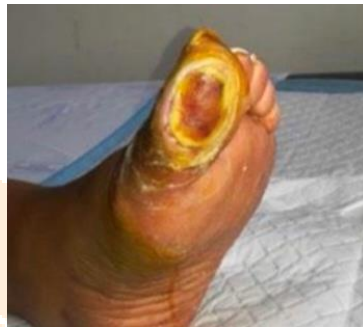The wound care plan that included Biatain Fiber supported favourable conditions for autolysis debridement by removing slough and necrotic tissue without the need for debriding products. B Fiber also absorbed and managed the high levels of exudates, helping to reduce further maceration of the periwound skin and supported epithelialisation. Biatain Fiber worked well in combination with Biatain Silicone Multi shape as a secondary dressing, as Biatain Silicone conformed to the contours of the foot, was easy to apply and provided comfort to the patient. Once gelled, Biatain Fiber was not observed to shrink in the wound and was easily removed without leaving any residue.



**CASE 2**

The patient was a 63-year-old woman with type 2 diabetes and hypertension, which was managed with oral medication. She presented to the wound care specialist with a diabetic foot ulcer (DFU) that had been present for 3 weeks and was believed to be caused by wearing tight-fitting footwear. At first a blister developed on the left first toe, which subsequently burst. The patient self-treated the wound with home remedies before seeking medical treatment. Before referral to the diabetic foot care team, the wound was treated in the local clinic with paraffin gauze, simple low-adherent, adhesive dressing and iodine. Initial assessment by the diabetic foot ulcer specialist

The foot had good palpable foot pulses (ankle-brachial pressure index=1.2) and the skin temperature was normal on the proximal aspect of the foot; however, on the distal aspects of the hallux around the wound, the temperature was abnormally warm and the wound was malodorous, which was indicative of local wound infection. The wound itself measured 50 mm (length) x 30 mm (width) x 5 mm (depth). The Triangle of Wound Assessment (Dowsett et al, 2019) was used to assess the wound bed, wound edge and periwound skin and determine the management goal.

**The management goals were as follows:**

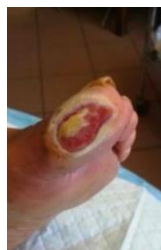- Wound bed: Remove non-viable tissue, manage exudates, manage bacterial burden
- Wound edge: Manage exudates, remove non-viable tissue
- Periwound skin: Manage exudates, protect skin, remove nonviable tissue

**Treatment**

The wound was debrided. The “football” dressing technique is a low-cost offloading method used as an alternative to the known mainstream offloading devices.

It is composed of multiple layers of gauze around the wound region, enough to provide cushioning over the wound dressing(s) applied, and crepe bandage wrapped around the midfoot, ankle and lower third of the leg firmly so that the patient can comfortably flex their ankle joint.

A semi-compressed felt material that complements the patients’ foot type and/or wound location can be added to the offloading sandal or beneath the foot.

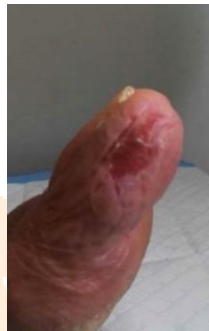

The wound was debrided with an enzymatic debriding gel, but wound moisture increased. Therefore, it was important to choose a dressing that would minimize the risk of maceration to the periwound skin. Biatain Fiber 10 cm x 10 cm was used as the primary wound dressing to manage the wound moisture and was held in place by Biatain Foam Non-Adhesive 10 cm x 10 cm (Coloplast). A “football” dressing technique was used to offload the ulcer. Rader

and Barry, 2008). Consultations and dressing changes were planned for twice weekly. The patient was prescribed a broad spectrum short course of co-amoxiclav 1 g twice daily for 7 days

After 1 month of treatment, the wound had reduced in size and the wound bed composition was improving. The wound became slightly less painful (8 out of 10). After 3 weeks, the levels of exudates had reduced and the patient only required dressing change once per week. The wound continued to reduce in size (35 mm x 20 mm x 2 mm), and the periwound skin was healthy.

Approximately 2 months later, the wound area had decreased further, and pain had considerably reduced (3 out of 10). The wound measured 1.6 mm x 1 mm x 0 mm and the wound bed composed of 90% epithelialisation tissue. There were no signs of infection and exudates level was low. The management goals were to protect the newly formed granulation and epithelialisation tissue of the wound bed and wound edges, and to protect the periwound skin. Six weeks later, the wound was fully reepithelialised with fragile, new skin. Therefore, the management goal was to protect the skin. The dressing regimen was changed to Biatain Contact 5 cm x 5 cm (Coloplast) and a 10 cm x 10 cm low-adherent-adhesive dressing.



## OUTCOME

For this sloughy, highly exuding DFU with undermining at the edge, Biatain Fiber dressing absorbed and retained exudates away from the wound bed. Biatain Fiber was easy to apply as the dressing conformed to the shape of the toe.

When the dressing was removed, it had not shrunk and it was visible that a gel had formed in the dressing which had conformed to the shape of the wound, reducing the risk of gap creation and exudates pooling.

The ulcer had initially presented with signs of local infection, which resolved with the use of Biatain Fiber without the need for a topical antimicrobial.

The patient was pleased that dressing change was pain free, that no fluid leakage occurred from the dressing, and that the wound fully healed.

## Case 3

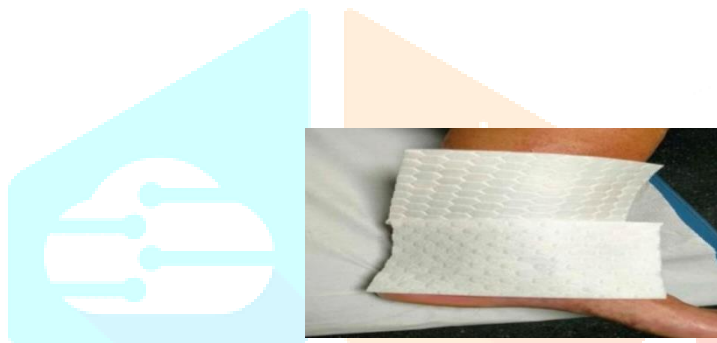
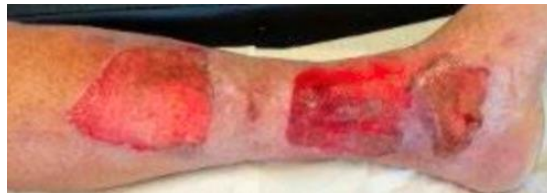The patient was an 83-year-old man with diabetes, anaemia and medical history of cardiovascular risk, including hyperlipidemia and chronic obstructive pulmonary disease (COPD). He had good mobility and a good nutritional status.

He presented to the hospital emergency department with a mixed (superficial and deep) second-degree thermal burn caused by a flame. In the emergency department, the wounded area was treated with argentic sulfadiazine plus a petrolatum mesh covered with a sterile dressing. Although most burns that are seen in the primary care setting are mild or not very serious, it is very important to know how to treat these wounds correctly to avoid complications that may harm the patient's wellbeing.

Initial wound assessment and start of treatment by the wound care specialist in the Primary Care Centre. After 2 days, the patient arrived to the Primary Care Centre with three blisters covering two-thirds of the medial part of the left leg. The wound was very painful (7 out of 10; 0=no pain, 10=unbearable pain). The Triangle of Wound Assessment (Dowsett et al, 2019) was used to assess the wound bed, wound edge and periwound skin and determine

### Management goals:

- Wound bed assessment: The tissue type was 50% sloughy and 50% granulation tissue. There were high levels of serous exudates from the wound area
  - Wound edge assessment: Healthy
  - Periwound skin assessment: Dry skin present
- The management goals
- Wound bed: Remove non-viable tissue, manage exudates, manage bacterial burden and protect granulation/epithelial tissue



### Treatment

First, the area was cleaned with saline and the devitalised tissue and skin was debrided from the wound bed. The periwound skin and wound edges of the burn were not affected. As there were high levels of serous exudates, Biatain Fiber was applied as a primary dressing Biatain Silicone Sacral 25 cm x 25 cm as a secondary dressing. Two of each dressing were required to adequately cover the injured area

A skin moisturiser was applied to perilesional skin. A crepe bandage was applied to hold the dressings in place. It was recommended to change the dressings every 48 hours. In the emergency department, the patient was prescribed paracetamol 650 mg every 6-8 hours. As the pain remained elevated and constant,

he was also prescribed tramadol 50 mg at night. Three days after the initial assessment by the wound care expert the dressings were changed. The combination of the BIATAIN FIBER WITH HEXALOCK TECHNOLOGY

BIATAIN FIBER WITH HEXALOCK TECHNOLOGY two dressings managed the exudates well, and they would edges and the periwound skin were both healthy. After 10 days of treatment the exudates level had decreased to medium, so only Biatain Silicone was applied. Dressing change was planned for every third day. After 17 days of treatment, the three wounded areas had all decreased in size. Hyperoxygenated fatty acid (HFA) oil was applied to the newly epithelialised area

After 4 weeks of treatment, all the wounds were decreasing in size and there was epithelialised tissue on the wound beds. The pain had decreased, so tramadol was no longer necessary. The wounds continued to progress, but after 43 days, two skin tears (measuring 4 cm x 2 cm and 1 cm x 2.5 cm) had occurred. The patient did not know how the skin tears occurred, but it is likely to have occurred because of friction or scratching. As a result, Biatain Fiber was applied again to protect the skin.

After 10 days (Day 53), the skin tears had resolved and it was no longer necessary to use Biatain Fiber. Biatain Silicone was used until healing. Two of the wounded areas reached full closure in just under 2 months (Day 57), only the larger, central injury remained to be closed. The wounded area was 95% epithelialised and the exudates level was very low. After 2.5 months of treatment the treatment had been successful and all the wounds had closed.

**OUTCOME**

One of the key aims of the treatment of highly exuding burns is to minimise the risk of infection by managing the high amount of exudates.

The exudates was efficiently absorbed and retained by the Biatain Fiber dressing away from the wound bed and periwound skin, which minimised the risk of further maceration to the periwound skin.

The combination of Biatain Fiber and Biatain Silicone, with their vertical absorption of exudates, was effective at supporting this large, wounded area to healing.

The removal of the dressings was simple, easy, atraumatic and painless for the patient. Biatain Fiber did not leave any residue in the wound bed nor did it shrink within the wound bed.

**Conclusion**

Case no -	Disease	conclusion
Case 1- 65-year-old woman	arterial hypertension, chronic kidney disease and haemodialysis	After 3 months of treatment the treatment had been successful
Case 2- 63-year-old woman	type 2 diabetes and hypertension	Approximately 2 months the treatment had been successful
Case 3- 83-year-old man	diabetes, anaemia and medical history of cardiovascular risk, including hyper lipidemia and chronic obstructive pulmonary disease	After 2.5 months of treatment the treatment had been successful and all the wounds had closed

**Reference**

- (1)Cohen, I.K. A Brief History of Wound Healing; Oxford Clinical Communications Inc: Yardley, PA, 1998
- (2)Winter, G.D.Nature 1962, 193 (4812), 293–294.
- (3)Gacesa, P. Alginates. Carbohydr. Polym. 1988, 8 (3), 161–182.
- (4)Dumville, J.C.; O’Meara, S.; Deshpande, S.; Speak, K. Alginate dressings for healing diabetic foot ulcers. Cochrane Database Syst. Rev. 2013, 6, Art. No.: CD009110..
- (5)Czajkowski, T.; Bogun, M. Analysis of the Polish market potential for innovative medical products made of alginate fibres, with special reference to alginate wound dressings. Fibres Text. East. Eur. 2012, 20 (6A), 16–21.
- (6)Dumville, J.C.; O’Meara, S.; Deshpande, S.; Speak, K. Alginate dressings for healing diabetic foot ulcers. Cochrane Database Syst. Rev. 2012, 2, Art. No.: CD009110.
- (7)Li, X.L.; Han, G.T.; Zhang, Y.M.; Jiang, W.; Xia, Y.Z. Preparation and physical properties of cavernous calcium alginate wound dressings. Adv. Textile Mater. Pts 1–3, 2011, 332–334, 1670–1675.
- (8)Qin, Y.M. The characterization of alginate wound dressings with different fiber and textile structures. J. Appl. Polym.

Sci. 2006, 100 (3), 2516–2520.

(9) Grizzi, I.; Braud, C.; Vert, M. Calcium alginate dressings— I. Physico-chemical characterization and effect of sterilization.

J. Biomat. Sci. Polym. E 1998, 9 (2), 189–204.

(10) Segal, H.C.; Hunt, B.J.; Gilding, K. The effects of alginate and non-alginate wound dressings on blood coagulation and platelet activation. J. Biomater. Appl. 1998, 12 (3), 249–257.

(11) Kneafsey, B.; OShaughnessy, M.; Condon, K.C. The use of calcium alginate dressings in deep hand burns. Burns 1996, 22 (1), 40–43.

(12) Advanced Wound Care: World Market Prospects 2013–2023; Visiongain: London, 2012.

(13) Wound Care Market—Current Trends, Opportunities & Global Forecasts to 2016; M. a. Markets: 2012.

(14) Weiser, T.G.; Regenbogen, S.E.; Thompson, K.D.; Haynes, A.B.; Lipsitz, S.R.; Berry, W.R.; Gawande, A.A. An estimation of the global volume of surgery: A modelling strategy based on available data. Lancet 2008, 372 (9633), 139–144.

(15) Physiological Basis of Wound Healing; P. P. Ltd.: 1994.

