



INTERNATIONAL JOURNAL OF CREATIVE RESEARCH THOUGHTS (IJCRT)

An International Open Access, Peer-reviewed, Refereed Journal

Polydactyly: A Review

1Dhawade Anusha ashok, 2Asst.prof. Ms.khandre Rajeshree A.

1B pharmacy , 2M pharmacy

1Dbatu.

2Pratibhatai Pawar college of pharmacy

Abstract:-

Polydactyly is a situation in which a individual has greater than 5 fingers per hand or 5 toes per foot. Having an odd quantity of digits (6 or more) can show up on its own, except any different signs and symptoms or disease. Polydactyly may also be handed down (inherited) in families. This trait entails only one gene that can reason quite a few variations. African Americans, greater than different ethnic groups, can inherit a sixth finger. In most cases, this is no longer triggered by using a genetic disease. Polydactyly can additionally happen with some genetic diseases. Extra digits may additionally be poorly developed and connected with the aid of a small stalk (generally on the little finger side of the hand). Or, they may additionally be well-formed and may also even function. Poorly fashioned digits are normally removed. Simply tying a tight string round the stalk can purpose it to fall off in time if there are no bones in the digit. Larger digits may additionally want surgical treatment to be eliminated.

(**Keyword:-** polydactyly, classification, Inheritance, treatment)

Introduction:-

Polydactyly is a condition in which a baby has extra fingers or toes. It is pretty frequent and most often, the greater digit is smaller than the standard fingers or toes. At times, the extra digit may additionally now not be well-formed and is simply a nubbin related to the fingers or toes by way of a skinny tissue stalk. In different cases, it is a well-formed digits with regular bone, blood vessels, muscles, and nerves. In the latter case, the digits are firmly related to the foot or hand.

Polydactyly or Polydactylism (from Greek origin, polys that means "many", and daktylos which means "finger" additionally recognized as hyperdactyly, is a congenital bodily anomaly in humans, dogs, and cats having supernumerary fingers or toes. Polydactyly is the contrary of oligodactyly which suggests fewer fingers or toes. The more digit is generally a small piece of tender tissue that can be removed. Occasionally it incorporates bone except joints; not often it can also be a complete, functioning digit. (A. Teebi,et al., 2001)

Polydactyly is the look of one or various supernumerary digits in the limbs of quite a few supernumerary digits in the limbs of vertebrates. It is usually understood as a surplus to the ordinary digit range in the wild type of a given (A.lange,et al.,2017).The greater digit is most frequent on the ulnar (little finger) aspect of the hand, much

less frequent on the radial (thumb) side, and very hardly ever inside the center three digits (B.Dorshorst,et al.,2010).

Different types of polydactyly can be distinguished: preaxial polydactyly refers to extra digits that are located anterior to the median axis of the limb, i.e., the radial element of the hand (thumb side), and the tibial component of the foot (first-toe side); whereas postaxial polydactyly are additions of digits posterior to the median axis, i.e., the ulnar thing of the hand and the fibular factor of the foot.

These are respectively recognised as postaxial (little finger), preaxial (thumb), and central (ring, middle, index fingers) polydactyly. The greater digit is most often an extraordinary fork in an current digit, or it may additionally not often originate at the wrist as a everyday digit does. Polydactyly belongs to the class of duplication. The greater fingers are typically smaller than his different fingers and are abnormally developed. The more fingers or toes may additionally be small and non-functional, in the case of nubbins or pores and skin tags, or they might also be totally shaped with bones and skeletal connections. Polydactyly frequently happens bilaterally (on each arms or each feet), or it might also appear on simply one hand or foot. Similarly, a character can also have greater digits on simply the hands, simply the feet, or some different combination.(B. Morrison,et al., 2008)

Polydactyly is characterised through the manifestation of supernumerary digits in the palms and feet. Polydactyly is characterised by means of the manifestation of supernumerary digits in the palms and feet. Based on the place of duplication.(S.Justine,et al.,2022)

The predominant etiology of polydactyly seems to be genetic. The genetics of polydactyly is surprisingly heterogeneous, and now not solely restrained to Mendelian inheritance. Most familial polydactyly are inherited in an autosomal dominant trait with variable penetrance, but autosomal recessive and X-linked inheritance patterns have additionally been stated . Generally, phenotypes of autosomal dominant polydactyly are much less extreme with variable penetrance and incomplete expressivity, which are ordinarily precipitated by using gene editions related with the anterior-posterior (AP) patterning of limb development. Genetic prognosis of polydactyly performs an essential position in threat stratification of probably life-altering skeletal dysplasia-related sickness and recurrence danger prognostication after surgical intervention for the affected individual.

Polydactyly is extra than a phenotype of skeletal dysplasia, and it may additionally point out a systemic congenital sickness or connective tissue disease. For example, quick rib polydactyly syndrome kind II (SRPS) is a genetic ailment whose seen phenotypes consist of a slim chest and polydactyly, however most of SRPS II sufferers do now not live on for lengthy due to the fact of their kidney, coronary heart and blood vessel dysfunction. Genetic prognosis of polydactyly allow clinicians to discover life-altering skeletal dysplasia-related disease. In spite of the substantial development of clinical genetics in latest years, molecular prognosis of polydactyly can nevertheless be challenging. A find out about via entire exome sequencing has been carried out in a highly small pattern with preaxial polydactyly, with a diagnostic yield of about 15%.(Zu.Bailing,et al., 2021)

Thumb polydactyly is a frequent congenital hand deformity and it represents a bodily and emotional trouble as the psychological burden at the back of proudly owning an greater finger is usually linked to psychosis in adulthood (P. sananta,et al.,2022).

Non-operative remedy is typically unsuccessful in managing signs and symptoms such as immoderate width, peculiar digit alignment, and growth. Prenatal prognosis and molecular cytogenetic characterization of WHS in a fetus with facial cleft and preaxial polydactyly. aCGH, QF-PCR and FISH assist to delineate the nature of a prenatally defected aberrant chromosome, and the obtained records is beneficial for genetic counseling.(C.Chen,et al.,2020) Polydactyly can additionally happen with different limb anomalies like variable ranges of syndactyly of fingers and toes.

History and Physical:-

Patients with polydactyly may additionally existing in infancy or later and may additionally appear in isolation or with different beginning defects. Polydactyly of hand and foot can be labeled into three principal categories: preaxial, central, and postaxial. In 1995, the congenital hand committee of the International Federation of Societies for Surgery of the Hand determined to exchange the phrases preaxial and postaxial polydactyly to radial and ulnar polydactyly. Radial polydactyly includes the thumbs, and ulnar polydactyly entails little fingers. Central polydactyly consists of the ring, middle, and index fingers, and is frequently related with syndactyly and cleft hand.(H.Ahmed ,et al.,2017)

The most frequent shape of polydactyly of hand is radial polydactyly, and the incidence charge is greater in Whites in contrast to different ethnic populations. Most instances are sporadic and unilateral except any related systemic problems. In these cases, the greater digits are considered anterior to the thumb. Radial polydactyly used to be similarly categorised by means of Wassel in 1969 into seven subtypes, serially from kind I to kind VII, and it is used through hand surgeons very efficiently all through the administration of the patients. Ulnar polydactyly used to be categorized by means of Temtamy and Mckusick into two categories, kind A and kind B. The phrases radial, central, and ulnar are used to describe the polydactyly of the top limb.

In contrast, the terms tibial, central, and fibular are used to describe polydactyly of the decrease limb. Polydactyly of the decrease limb was once categorized by way of Swanson primarily based on the presentation of the more digit on the foot. If greater digit influences the exquisite toe, it is known as tibial polydactyly, and when it impacts the little toe, it is known as fibular polydactyly. When the central three digits are affected, then it is referred to as central polydactyly.(A.Swanson ,et al.,1976)

Classification:-

Polydactyly can be categorised into preaxial, central, and postaxial sorts relying on the region of the duplication. About seventy nine p.c of all duplications are postaxial, 15 p.c are preaxial and ultimate 6 percent are Central .(A.Akhtar ,et al.,2017)

Temtamy and McKusick have described polydactyly based totally on the location of the more digit such as Preaxial (medial ray), central, and postaxial (lateral ray). Postaxial polydactyly taking place in 80% of the patients is frequently asymmetric. Preaxial polydactyly impacts the huge toe and occurs in 15% of patients, whilst central duplication happens in(J.Christensen,et al.,2011)

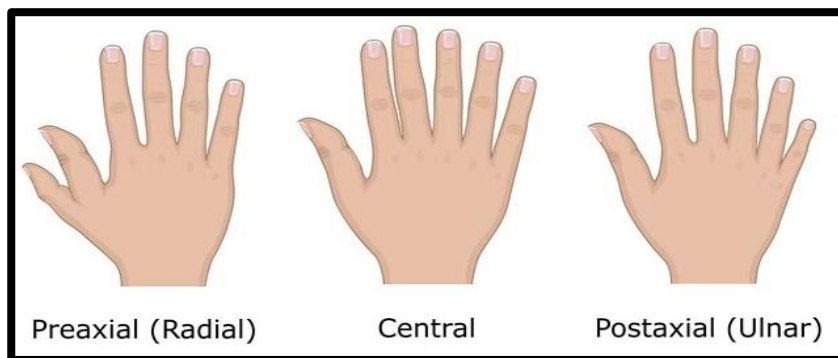


Fig1: Classification of Polydactyly

Preaxial:-

In preaxial polydactyly, the extra digit is existing on the outdoor of the massive toe or thumb. When current in the feet, the presence of the more digit is regarded as tibial polydactyly. When existing in the hand, it is regarded as radial polydactyly.

Based on the Wassel classification, preaxial polydactyly is similarly categorised into seven types:

- Bifid distal phalanx
- Duplicated distal phalanx
- Bifid proximal phalanx
- Duplicated proximal phalanx
- Bifid metacarpal
- Duplicated metacarpal
- Triphalangia

Preaxial polydactyly takes place in 1 in 1,000 to 10,000 newborns. Type IV or duplicated proximal phalanx is the most frequent form, and happens in 43%. It may additionally be linked with syndromes such as tibial defects, Fanconi's anemia, imperforate anus, Holt-Orams syndrome, Blackfan-Diamond anemia, and cleft palate. Type II or duplicated distal phalanx is in the 2nd role and takes place in 15% of the population.

Males are extra affected than females. Conditions such as polluxabductus are related with preaxial polydactyly. Preaxial polydactyly (medial ray polydactyly) typically consists of the thumb and can happen itself in 1 of four kinds (types 1, 2, 3, and 4).⁴⁵ It tends to be related with GLI3 on chr7p13 and SHH on chr7q36.

Preaxial polydactyly is the most frequent shape of polydactyly. This disease takes place with disruption of the sonic hedgehog (SHH) gene in the quarter of polarizing recreation (ZPA), which is in the anteroposterior manipulate center.⁵⁻⁷(A.Bischoff,et al.,2022)

Based on the Wassel classification, preaxial polydactyly is similarly labeled into seven types:

1) Bifid Distal Phalanx :- Thumb polydactyly is the most frequent kind representing the duplication of a biphalaengeal thumb .Usually located as unilateral form, whilst in bilateral cases, arms are extra preferentially affected and the left hand PPD are uncommon as in contrast to proper hand PPD . There is a low incidence of familial reappearance and excessive incidence of affected men than females.

2) Duplicated Distal Phalanx :- Preaxial polydactyly kind two or TPT (replaced biphalaengeal thumb) the place the thumb has an greater center phalanx with abnormally lengthy and skinny first metacarpal, having epiphyses at each ends .

3) Bifid Proximal Phalanx:- Preaxial polydactyly kind three is very uncommon disease segregating in an autosomal dominant fashion. In this type, the index finger is commonly duplicated. One or two triphalaengeal digits exchange the thumb. The metacarpal of the accent digit indicates distal epiphysis, due to such phenotypes PPD kind three is separated from PPD kind two or TPT

4) Duplicated Proximal Phalanx:- In polysyndactyly the thumb is duplicated mildly, the distal phalanxes exhibit radial deviation or with a large and bifid thumb. Syndactyly of 1/3 and fourth fingers is not often existing In the feet, the first toe indicates polydactyly, and the first metacarpal is tibially deviated and short.

5) Bifid Metacarpal:- Whole duplication of distal and proximal phalanx with bifurcation of the metacarpals

6) Duplicated Metacarpal:- Complete duplication of distal and proximal phalanx and metacarpal.

7) Triphalangia:- Variables diploma of duplication with triphalangeal thumb.(M. Umair,et al.,2018)

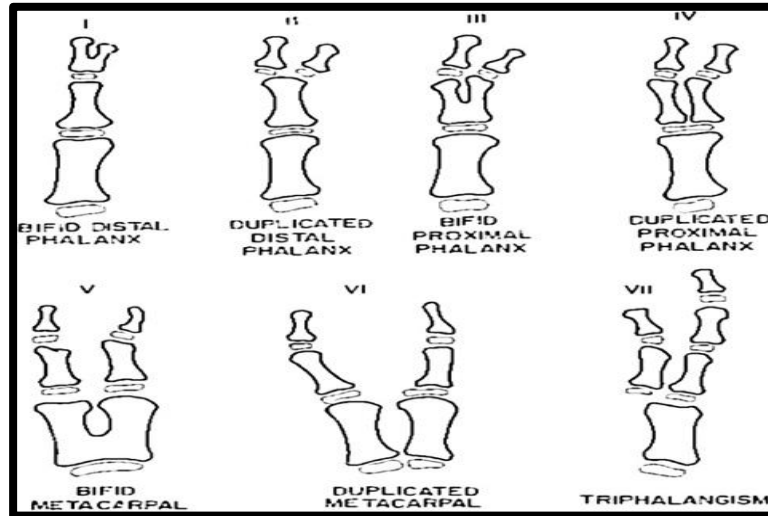


Fig2:- Classification of Preaxial Polydactyly

Postaxial:-

In postaxial polydactyly, the extra digit is current on the outdoor of the little toe or little finger. When existing in the feet, the presence of the more digit is regarded as fibular polydactyly. When current in the hand, it is acknowledged as ulnar polydactyly.

When the digits are nicely formed, it is classified as Type A. The presence of vestigial digits characterizes Type B polydactyly. Postaxial polydactyly is viewed 10 instances extra frequently amongst African-Americans and takes place in 1 in 3,000 infants. Inheritance in general follows an autosomal dominant pattern.

Various research have pronounced the incidence of polydactyly amongst embryos and newborns, throughout one-of-a-kind human races and the two genders.

In Japan, the frequency of polydactyly is greater in embryos that are spontaneously aborted in contrast with newborns. About 0.35% of polydactyly of all sorts put collectively used to be discovered in 36 380 brought on abortion embryos. Among the 129 embryos that had been affected, postaxial polydactyly was once viewed in 29 embryos (12 versus 17 in the fingers and toes respectively)

In Seattle, out of 5200 abortions, polydactyly used to be seen in 20 embryos. Of these, 67.9% had postaxial polydactyly. Bilateral polydactyly used to be determined in 33% and different abnormalities had been related in 30%. Among newborns, polydactyly instances are the lowest amongst the Japanese (0.08/1000), whilst South Africans and African-Americans in the USA have been suggested to have 1%.

In unilateral polydactyly, the left foot or the left hand is the most frequently affected. In one specific learn about of 762 newborns with unilateral polydactyly, the left hand was once affected in 77%. The equal find out about observed that out of 56% of newborns with postaxial polydactyly in the foot, the left foot used to be affected. Left-side polydactyly was once seen in 10 of eleven affected newborns. Compared with unilateral polydactyly, bilateral types are extra common.

Postaxial polydactyly (lateral ray polydactyly) is characterised via a hypoplastic or absolutely developed little finger, is frequently (H.Ahmed,et al.,2017)

Classification of Postaxial:-

1) Postaxial Polydactyly Type A :-

In PAP kind A, completely developed greater digit articulates with both a duplicated metatarsal or metacarpal or with the fifth metatarsal or metacarpal . The duplicated digit can also have one to three bony factors relying upon its size, which effects in flexion wrinkle and a well-developed nail(S.Temtamy,et al.,1978)

2) Postaxial Polydactyly Type B:-

In PAP kind B, the richest kind of polydactyly in a range of populations, the greater digit may additionally no longer be nicely developed and therefore happens in the structure of a skin, from a negligible signal of small protuberance to spine-like outgrowth on the ulnar aspect of fifth finger, or a nubbin-like 2–3 cm lengthy “pedunculated postminimus,” commonly having a nail. The articulation web site of the fifth digit alongside this nubbin is variable and often thru as a small cutaneous bridge. Preferentially, the left hand and the higher limbs are ordinarily affected. This kind of polydactyly indicates extra complex genetics and thus, the estimated penetrance is about 43% .

3) Complex types of polydactyly:-

Complex polydactylies are labeled one after the other as they have a one of a kind phenotype than PAP or PPD .

i) Mirror-Image Polydactyly (MIP)

In MIP posterior digits duplication occurs, whilst the anterior digits are definitely exchanged in reverse order by way of the posterior digits. Thus, the association of an more digit is in descending order from the central digit, e.g. little finger, ring finger, center finger, index finger, and the center finger, ring finger, little finger with thumb/hallux absent suggested an man or woman with entire duplication of all fingers having 9 digits on proper and 10 digits on the left hand, for this reason having a bilaterally intricate configuration.

ii) Mesoaxial or Central Polydactyly:-

Mesoaxial or Central polydactyly is a “hidden” duplications with obvious syndactyly or in the center phase of the hand, synonychia, might also be existing as a mass of tissue, even though all mesoaxial sorts are now not hidden (Figure II). Central polydactyly like 2d finger duplication is dominantly inherited . The deformity is typically bilateral, and the fourth digit is duplicated most frequently; these duplications are greater frequent than the index digit duplication .

iii) Palmer and Dorsal Polydactyly:-

Palmer polydactyly is a very uncommon sickness in which greater digit commonly occur from the ventrum or dorsum phase of autopods. It might also be proven as a poorly developed digit ray or a small pores and skin (tag), or a developed digit with or barring nail and implanted into the autopod as a hook (Figure III).

iv) Haas Type Polysyndactyly:-

In Haas kind polysyndactyly all the digits are fused cutaneously, and there is a postaxial or a preaxial greater ray in the internet. Due to a whole syndactyly, the motion of digits is constrained and the fusion of adjoining fingers offers a cup-shaped look to the hand (Figure IV).

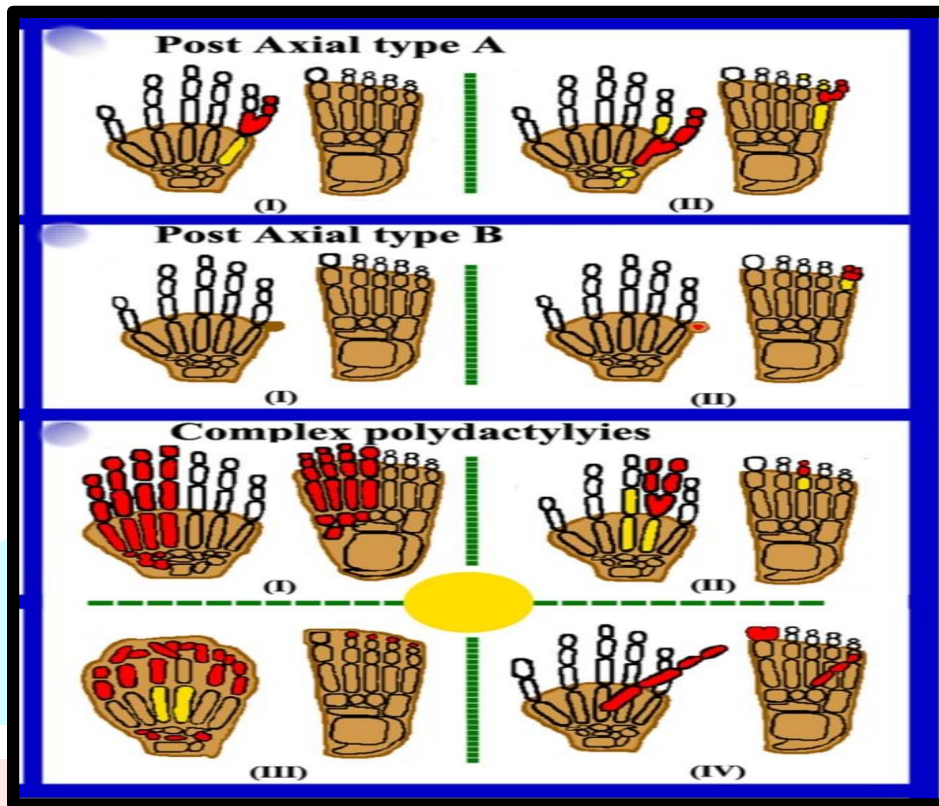


Fig3:- Classification of Postaxial Polydactyly

Central:-

The place the extra digit is existing between the toes or fingers, is a uncommon structure of polydactyly.

Central polydactyly (also “central ray” polydactyly) is related with syndactyly and cleft hand.⁴⁵ It dominantly seems syndromically.(Hand malformation,et al.,2015)

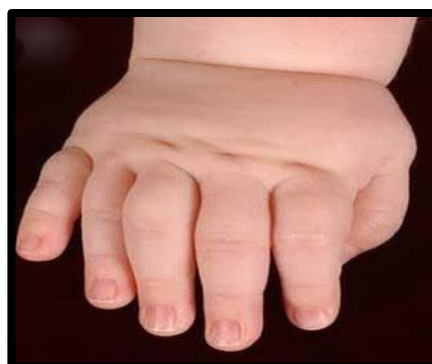

Fig4:- Central Polydactyly

Causes of Polydactyly:-

Polydactyly happens when the physique follows a one of a kind set of instructions than normal whilst forming the fingers or toes at some point of development. Researchers are nonetheless gaining knowledge of about all the genes that purpose more digits. The trait may also be exceeded down in households as an isolated, benign condition, like having a hitchhiker's thumb or being double jointed is viewed a non-syndromic anomaly.

Alternatively, the trait might also exist as phase of a syndrome, which is a crew of a number of recognizable scientific elements that regularly take place together. Some syndromes that might existing with polydactyly consist of GreigCephalopolysyndactyly Syndrome (GCPS) or Bardet-Biedl Syndrome (BBS).

The causes are: (C. Garrett,et al.,1988)

- Asphyxiating thoracic dystrophy
- Carpenter syndrome
- Ellis-van Creveld syndrome (chondroectodermal dysplasia)
- Familial polydactyly
- Laurence-Moon-Biedl syndrome
- Rubinstein-Taybi syndrome
- Smith-Lemli-Opitz syndrome
- Trisomy thirteen
- Wolf- Hisschhorn syndrome

Genetic Causes:-

Polydactyly is related with distinct mutations, both mutations in a gene itself or in a cis-regulatory.

Element accountable for the expression of a unique gene. In many instances Sonic hedgehog (Shh) is affected, hardly ever Indian Hedgehog (double foot mutant) or Bone morphogenetic proteins (BMP). Also mutations in Hoxa- or Hoxd clusters are said main to polydactyly. Interactions of Hoxd13 and GLI3 result in synpolydactyly, a aggregate of greater and consolidated digits. Other sign transduction pathways in this context are the Wnt signaling pathway or Notch. In a concrete case of preaxial polydactyly (Hemingway mutant) a mutation of the cis-regulatory thing ZRS (ZPA regulator sequence) is associated. ZRS is a noncoding element, 800.000 basepairs far flung to the goal gene Shh.

An ectopicexpression of Shh is considered on the anterior facet of the limb. Normally Shh is expressed in an organiser region, known as the sector of polarizing exercise (ZPA) on the posterior limb side. From there it diffuses anteriorly, laterally to the increase course of the limb. In the mutant mirroring smaller ectopic expression in a new organiser area is considered on the posterior aspect of the limb. This ectopic expression motives phone proliferation turning in the uncooked fabric for one or greater new digits. (N. naveed,et al.,2017)

Symptoms of Polydactyly:-

Children with polydactyly are born with one or extra greater fingers or toes

The greater digit can also be

- A small, raised bump or a piece of pores and skin that appears like a small finger or toe that isn't thoroughly fashioned (nubbin)
- A complete, working finger or toe
- For some children, polydactyly is solely one function of a greater complicated genetic circumstance or syndrome. These kids will have different symptoms and symptoms(Crossmark,vol.99)

Inheritance of Polydactyly:-

African, Americans, extra than different ethnic groups, can inherit a sixth finger. In most cases, this is no longer brought on by means of a genetic disease. Polydactyly can additionally manifest with some genetic diseases. The circumstance has an incidence of 1 in each five hundred stay births. Postaxial hand polydactyly is a frequent remoted ailment in African black children, and autosomal dominant transmission is suspected. Postaxial polydactyly is extra accepted in blacks than in whites and is greater well-known in male children. In contrast, postaxial polydactyly viewed in white adolescents is normally syndromic and related with an autosomal recessive transmission.

One learn about by way of Finley et al. blended facts from Jefferson County, Alabama, United States and Uppsala County, Sweden. This learn about confirmed incidence of all kinds of polydactyly to be 2.3 per a thousand in white males, 0.6 per one thousand in white females, 13.5 per a thousand in black males, and 11.1 per a thousand in black females. African Americans, greater than different ethnic groups, can inherit a sixth finger. (J.Hand Surg Eur,2005) Most cases, this is no longer precipitated via a genetic disease.

Polydactyly can additionally show up with some genetic diseases. Research has proven that the majority of congenital anomalies take place throughout the 4-week embryologic length of fast limb development. Polydactyly has been related with 39 genetic mutations. More unique loci and genetic mechanisms accountable for problems of duplications will be described with time, as molecular lookup continues

Forms of Polydactyly:-

There are many special varieties of polydactyly, ranging from

- a small greater bump on the facet of the hand,
- a finger which widens to cease in two fingertips,
- an greater finger which dangles through a skinny twine from the hand,
- a hand which appears everyday without that it has a thumb and 5 fingers, and an endless quantity of different variations.(G. Jepsen,et al.,1966)

Diagnosis:-

Tests used to diagnose the condition:

- Chromosome studies
- Enzyme tests
- X-rays
- Metabolic studies

During pregnancy, this situation might also be recognized with ultrasound or a extra superior take a look at known as embryofetoscopy throughout the first three months. Your baby may additionally want an X-ray to see if there are bones in the more digit and to see how the more digit connects to the relaxation of the hand or foot. If the physician thinks your baby would possibly have different genetic problems, your toddler may have checks to take a look at their chromosomes. (J. Aroson,et al.,2006)

Where prenatal diagnoses is unclear, molecular genetic techniques can be complementary. First, DNA ought to be extracted from the fetus in utero through unique methods.⁵⁷ Next, the DNA is analyzed for applicable mutations by means of sequence analysis, deletion/duplication analysis, or cytogenetic/fluorescent in situ hybridization analysis.

Complications:-

In polydactyly of the hand, bleeding and anesthetic problems can also happen all through the perioperative period. Functionality can be reduced later due to the contracture or ligamentous laxity. A painful neuroma is every other complication, in particular when the usage of suture ligation, and it happens at the remedy site. Beneath the suture ligation site, a painful neuroma varieties due to the fact the digital nerves of the more digit are reduce off at the pores and skin level, so it can't retract in the tender tissues. As a result, the young people are inclined to damage to the pores and skin tag ensuing in pores and skin breakdown (M.farrugia et al.,2016).

In polydactyly of the foot, hallux varus is the most frequent complication of tibial polydactyly that may additionally lead to subsequent surgical correction. Fibular polydactyly may additionally have a residual angular deformity.

Syndromes Associated with Polydactyly:-

Ulnar polydactyly is regularly bilateral and related with syndactyly and polydactyly of the feet. This can be a easy or complex polydactyly. Ulnar polydactyly takes place as an remoted congenital condition, however can additionally be section of a syndrome. The syndromes which show up with ulnar polydactyly are: Greig cephalopolysyndactyly syndrome, Meckel syndrome, Ellis–van Creveld Syndrome, McKusick–Kaufman syndrome, Down syndrome, Bardet–Biedl syndrome, Smith–Lemli–Opitz syndrome. (MM Al-Qattan,et al., 2010) Type VII of radial polydactyly is related with numerous syndromes: Holt–Oram syndrome, Fanconianemia: aplastic anemia at the age of 6, Townes–Brocks syndrome, Greig cephalopolysyndactyly:also takes place with ulnar polydactyly.

The syndromes related with central polydactyly are: Bardet–Biedl syndrome, Meckel syndrome, Pallister–Hall syndrome, Legius syndrome, Holt–Oram syndrome, Also, central polydactyly can be related with syndactyly and cleft hand. Other syndromes which includes polydactyly encompass Acrocallosal syndrome, Basal telephone nevus syndrome, Biemond syndrome, Ectrodactyly-ectodermal dysplasias-cleft lip/palate syndrome, Mirror hand deformity,Mohr syndrome, Oral-facial-digital syndrome, Rubinstein-Taybi syndrome, Short rib polydactyly, and VATER association. It can additionally show up with a triphalangeal thumb.

Materials and Methods:-

1)Family history:-

Written is of the same opinion for conducting the learn about and e-book of the results, together with patient's snap shots and radiographs, had been got from elder individuals of the family. Pedigree of the household used to be drawn after interviewing elders and mother and father of affected members. Analysis of the pedigree furnished significant proof of inheritance of the disease in an autosomal recessive manner. Affected household contributors (IV-1, IV-2) had been examined by using a scientific officer at nearby authorities hospital. X-rays of the affected person fingers and ft had been carried out at the equal hospital.

2) Extraction of genomic DNA:-

For genetic analysis, blood samples have been supplied via seven folks together with two affected (IV-1, IV-2) and 5 unaffected (III-1,III-2, IV-3, IV-4, IV-5) in the family. Extraction of genomic DNA, from the accumulated blood samples, used to be carried out the use of the widespread phenol/chloroform technique and quantified the usage of Nanodrop-1000 spectrophotometer.

4) Surgical technique:-

The most commonly used surgical method for the cure of preaxial polydactyly is ablation of the radial thumb and reconstruction of the joint. The surgical results fluctuate relying on several elements inclusive of the hypoplasticity and the diploma of angulation of the thumbs. The term “balanced” is used for the duplicated thumbs which lie straight and parallel. (M. Ozdemir, et al., 2019)

Under prevalent anesthesia, a new medical evaluation, together with the measurement of the nails of the two thumbs, and the passive mobility of the metacarpophalangeal (MCP) and the interphalangeal (IP) joints, was once measured by way of one of the authors. After a zigzag pores and skin incision and subcutaneous dissection (Fig. 1A), we eliminated the whole nail of the radial thumb and delimited an unguis tender tissue flap harvested from the radial edge. The nail of the ulnar thumb reproduction used to be consequently completely preserved. If the nail of one of the thumbs is extra than 70% of the contralateral normal, thumb nail width, it is retained in its entirety with excision of the different nail.

When the nail width is much less than 70% of the contralateral normal, a nail lengthening surgical treatment is wished. Depending on the size of the contralateral fingernail, we designed a small rectangle excision whose dimension tiers between two and three mm, and the distance from the distal border of the eponychium is about 5 mm (Fig. 1A). At the stage of subcutaneous vascular community the rectangle web site used to be de-epithelialized. After a small retractor separated the eponychium from the nail matrix, we ought to slide the eponychial flap proximally and suture two ends by way of PDS® 6.0 (H. Zhang, et al., 2016)

Treatment of Polydactyly:-

In most cases, medical doctors dispose of an greater finger or toe in early childhood. The aim of therapy is to supply your infant a hand or foot that works properly and appears typical. The technique for getting rid of an more digit relies upon on how it connects to the hand or foot. An more digit might also join with solely a slender stalk of tissue, or it might also join greater deeply and share bones, muscle tissue and different tissues with the hand or foot.

Vascular clip:- If the digit is poorly shaped and carries no bone, every now and then the therapy is as easy as attaching a vascular clip at the base in the course of a health facility visit. The clip stops blood glide to the digit so it will fall off, like the stump of stomach button does quickly after birth. After attaching the clip, the medical doctor places a bandage on your child’s hand or foot. In a couple of weeks, your baby comes lower back to the health center to have the bandage removed. (P. Meinecke, et al., 1990)

Surgery:- If the digit is higher formed, a medical professional gets rid of it in the working room when your baby is about 1 yr old. This is accomplished as a day surgery. Your child’s surgical procedure will be primarily based on their specific condition. More complicated instances may additionally require complicated surgery. The surgical procedure can also contain cautiously slicing via or round bones, ligaments, muscles, tendons and different tissues to put off the greater digit. Then the general practitioner may also want to go or reconnect some constructions earlier than closing the pores and skin so the complete hand or foot works nicely and appears normal.

After surgery, your toddler may also want to wear a solid or splint on their hand or foot whilst it heals. The physician will favor your baby to come lower back for follow-up visits to make certain they are recuperation well. Some youth who have vast surgical procedure with reducing thru many tissues may additionally have occupational remedy to assist with swelling, scarring and stiffness.

Procedure of Treatment:-

The reconstruction does no longer genuinely contain an ablation of the smaller duplication portion. The shared articular floor have to be reshaped, the bones realigned, and the collateral ligaments of the joint ought to be reconstructed to make sure the balance of that joint, and tendons need to be realigned. If these established standards are now not adhered to, the thumb will in any other case have an unstable metacarpal phalangeal joint, and substantial residual deformity, and primary purposeful problems. On occasion, due to the fact of joint floor malalignment (particularly when the duplication entails a shared joint in addition to the ligament and tendon readjustments) a corrective bony osteotomy can also be considered.

This process includes honestly tacking the bone and resetting its perspective and might also be required at the preliminary correction of the polydactyly. This is carried out to keep away from any long-term misalignment of the reconstructed thumb and to decrease the danger of a residual zigzag unstable deformity to that reconstruction (S.Marles,et al.,1990).While it is necessary to meet with the infant at a younger age, inside a month or two of birth, the true reconstructive surgical treatment for polydactyly (digital duplication) will normally be carried out someplace round 9 or 10 months of age.

Conclusion:-

Polydactyly does not generally pose any health risk over time. Surgical treatment is more likely to result in a satisfactory outcome if surgery is done in the first few years of life to give the child the most ability to adapt and accommodate to the changes in their hand. People are less likely to be satisfied with surgery for polydactyly if surgery is delayed past early childhood. A hand therapist can help with some problems before and after surgery, tailored to the individual problem and the temperament of the child, but some children proceed through their surgery and recovery without needing therapy. The goals of surgery are to improve the appearance of the hand and to prevent progressive deformity from developing as the child grows.

Surgery is generally successful in both of these areas, largely correcting the appearance and social stigmata of congenitalism. In many cases, surgery results in a greatly improved but not perfectly normal appearance, and in some situations a normal appearance can not be expected. For example, each of the duplicated thumbs in the above diagram is likely to be smaller than a normal thumb, and no amount of surgery will allow a smaller thumb to "catch up" and perfectly match a normal size thumb on the opposite hand. Fortunately, unless there is something particularly eye-catching about the hand (like an extra finger or thumb), what people notice about another person's hand is not the appearance of an individual finger or thumb, but how the person uses their hand.

Reference:-

1. AS Teebi, AJNR 2009 30:– clinical dysmorphology, Journals.lww.com,(2001)1620-1622.
2. Axel lange, polydactyly in development inheritance and evolution, THE QUARTERLY REVIEW OF BIOLOGY Volume 92,(2017), 0033-5770.
3. B Dorshorst, Journal of heredity, Am Genetic Assoc(2010)
4. BE Morrison, Experimental Biology and Medicine, ebm.sagepub.com(2008)
5. Justine S. Kim, Operative technique and management of central foot polydactyly, JPRAS Open 32 (2022) 61–71
6. Bailing Zu, Identification of the genetic basis of sporadic polydactyly in China by targeted sequencin, Computational and Structural Biotechnology Journal 19 (2021) 3482–3490
7. Panji Sananta, The management of mirror foot polydactyly: A case report,International Journal of Surgery Case Reports 91 (2022) 2210-2612.
8. Chih-Ping Chen, WolfeHirschhorn syndrome: Prenatal diagnosis and molecular cytogenetic characterization of a de novo distal deletion of 4p(4p16.1 / pter) in a fetus with facial cleft and preaxial polydactyly,C.-P., Chen et al. / Taiwanese Journal of Obstetrics & Gynecology 59 (2020) 425-431

9. Ahmed H, Genetic Overview of Syndactyly and Polydactyly Plastic and reconstructive surgery. Global open.(2017)
10. Swanson AB, A classification for congenital limb malformations, The Journal of hand surgery,(1976)
11. Akhtar Ali, GLI3 MEDIATED POLYDACTYLY : A REVIEW, Journal of Scientific Research Banaras Hindu University, Varanasi, Vol. 61, (2017) : 121-129 ISSN : 0447-9483
12. J.C. Christensen, Congenital polydactyly and polymetatarsalia: classification, genetics, and surgical correction, J. Foot Ankle Surg. 50 (3) (2011) 336–339
13. Alex Bischoff, First metatarsophalangeal joint arthrodesis for hallux valgus in a patient with preaxial polydactyly and triphalangeal hallux, Foot & Ankle Surgery: Techniques, Reports & Cases 2 (2022) 2667-3967
14. Muhammad Umair, Clinical Genetics of Polydactyly: An Updated Review, MINI REVIEW , (2018)
15. Humayun Ahmed, BA; Genetic Overview of Syndactyly and Polydactyly, Plast Reconstr Surg Glob Open,(2017),5-1549.
16. Temtamy, S. A., . “Syndactyly,” in The Genetics of Hand Malformations, eds S. A. Temtamy and V. A. McKusick (New York, NY: Wiley),(1978),301–322.
17. Teaching Resources: Hand Malformations [Internet]. Gainesville, FL.: University of Florida. Available at <https://www.peds.ufl.edu/divisions/genetics/style/images/polydactyly-composite.gif>. (2015)
18. C Garrett, Journal of medical genetics, (1988) -jmg.bmj.com
19. Niha Naveed, POLYDACTYLY -A REVIEW, International Journal of Information Research and Review, (2017),4302-4305.
20. Crossmark, vol. 99 no. 11> Laura A. Lettice, 7548–7553
21. J Hand SurgEur Vol August vol. 30 no. 4,(2005) 346-349
22. GL Jepsen – Science, (1966) – sciencemag.org
23. JK Aronson – British Journal of General Practice, (2006) -bjgp.org
24. Farrugia MC, Polydactyly: A Review. Neonatal network : NN. (2016).
25. MM Al-Qattan – Journal of Hand Surgery (European Volume), 2010 – jhs.sagepub.com
26. Meltem Özdemir, MD, Wassel type III polydactyly, Radiology Case Reports 1 4 (2019) 287–290
27. Haifeng Zhang, Thumb function and appearance following treatment of Wassel type III duplication thumbs, International Journal of Surgery Open 4 (2016), 2405-8572
28. P Meinecke, Journal of medical genetics, (1990)
29. SL Marles, Journal of medical genetics,(1990),jmg.bmj.com