



# KNOWLEDGE AND AWARENESS ABOUT SYSTEMIC CONDITIONS AND ITS ORAL MANIFESTATIONS FOR PATIENTS UNDERGOING DENTAL EXTRACTION AMONG DENTAL STUDENTS

**Dr. Vandana shenoy, Anusre A, Apparna I, Gayathri K, Dr. Mohamed Afradh**

Professor, Dental Intern, Dental Intern, Dental Intern, Senior Lecturer

Department of oral and maxillofacial surgery,

Thai Moogambigai dental college and hospital, Chennai, India.

## ABSTRACT:

Exodontia or extraction of the tooth is defined as the painless removal of the entire tooth or the root with minimum trauma to the investing tissues, so that the wound heals uneventfully and no postoperative prosthetic problem is created. A proper History of the patient is necessary before extraction for evaluating the patient. Many systemic diseases have direct or indirect relation with Exodontia. So, it is necessary for the practitioner to understand the indications, contraindications and management of the patient in case of emergency of these patients during extraction. The survey is conducted among the undergraduate students.

**KEYWORDS:** Anticoagulant therapy, complications, Extraction, oral manifestations, oral-systemic connection.

## INTRODUCTION:

Exodontia is the painless removal of the entire tooth or root from the socket with minimal trauma to the adjacent tissues, so the wound healing will happen uneventfully. This is done with the aid of local anaesthesia<sup>[1]</sup>. Removal of tooth can be due to various reasons, in most of the cases it is done where the tooth cannot be saved by any means of endodontic treatment and the tooth is highly infected. Extraction of a healthy tooth can also be done in cases of orthodontic treatments i.e therapeutic extractions<sup>[2]</sup>. Tooth extraction can be of two types. The intra- alveolar extraction, also called Forceps extraction in which forceps, elevators are used for removal of the tooth. The other being Trans-alveolar extraction where the tooth is removed by sectioning and bone removal, which is also called as Surgical extraction<sup>[3]</sup>. The extraction of tooth and the local anaesthetic agent used during extraction is directly related with the systemic condition of the patient. So, it is very important that the Dentist is aware of the relationship between the patient's systemic condition and the procedure performed. This survey is done in order to assess the awareness among the undergraduates regarding Exodontia and its systemic considerations. Many systemic conditions can have an indirect or direct impact on the Tooth extraction procedure. The questions were asked based on the relation between the systemic condition and extraction of tooth, the indications and contraindications of the same. General questions based on the exodontia and the Myths of exodontia have also been asked in this survey considering the motive of the study.

**AIM:** The Aim of the study is to assess the knowledge and awareness of Exodontia and its relation with the systemic conditions. The Questionnaire is mainly based on the relation between the extraction and the systemic diseases, the indications and contraindications of anaesthetic agents in relation to systemic diseases and also regarding their emergency management. Questions which are related to the general knowledge, myths of extractions have also been asked in this survey.

### **METHODOLOGY:**

The survey was conducted in an online based questionnaire format in google forms and was sent to various groups of undergraduate's students. The responses of each question among two hundred fifty one students are collected, summarised and analysed. The statistical analysis through percentage is then interpreted and a conclusion is formatted.

### **STATISTICAL ASSESSMENT:**

The statistical analysis of the above survey gives us key data. The interpretation is as follows:

A majority of 88.4% students are aware of the definition dental extraction and 6.4% were not aware about the same. About 60.2% of students were aware that sodium hypochlorite is not a composition of local anaesthesia and 39.8% didn't have knowledge regarding the same. A total of 70.5% students are sure that wisdom teeth/3rd molar should be removed or preserved according to the situation whereas 29.5% of the students were in a confused state. Approximately 67.3% of students agree that avoiding alcohol consumption promotes healing after tooth extraction and 13.9% disagree, whereas 18.7% are unaware about it. A minimum of 37.1% responders were aware that extraction of teeth is avoided during the menstrual cycle and the rest unaware of it.

A minority of 46.6% students does not believe in the myth that "extraction during winter season is not safe", which suggests that the majority of 53.3% students lack knowledge about the same. Only about 38.6% of the students believe that tooth extraction recovery requires 21 days for complete healing. 69.3% of students had accurately answered that the second trimester is safer to perform dental extraction during pregnancy. An astounding 65.3% of the participants suggest avoiding straw after dental extractions because it may dislodge the blood clot.

Remarkably 57.8% of the students were aware that dental procedures should be avoided for minimum 6 months after myocardial infarction. A majority of 76.6% students knew the normal blood sugar level. About 64.9% of the participants were aware that both delayed wound healing and Periodontitis are the oral manifestations of Diabetes and the rest 35.1% were in a confused state. Around 67.3% of the students were aware that both excessive bleeding during hemostasis and difficulty in achieving hemostasis are the complications of dental extractions in patients under anticoagulant therapy. Approximately 61% of the students were aware that traumatic extractions can cause dry sockets when the blood clot fails to form, dissolve, or dislodge.

It is observed that around 29.1% students believe that a high fever following a tooth extraction is not a common occurrence. A total of 68.9% students were aware that applying local pressure and suturing the extraction site is the safer management of patients under anticoagulant therapy during dental extraction. Around 58.2% of the participants agree that blood thinners should be stopped before dental extraction procedure is observed. About 59.4% of the participants were aware that ibuprofen is contraindicated in asthmatic patients. Among the participants around 50.6% knew that both articaine and prilocaine local anaesthesia should be avoided in severe anaemic patients, whereas the remaining 49.4% were in unclear state.

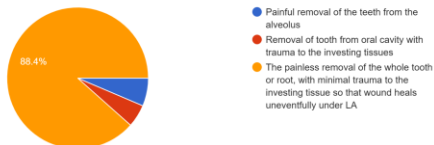
A majority of 58.9% of the students were unaware that the recurrent oral ulcers, oral candidiasis and Angular cheilitis are the oral manifestation of anaemia. Only 30.7% of the students knew that magenta tongue is seen in anaemia while the remaining were unclear about it. About 52.2% of the participants were unaware that chvostek sign is seen in hypocalcemia. Around 58.6% knew that the seizure/convulsion are due to Hypoglycemia, Hypoxia, and local anaesthetic overdose. Dental erosion and water thrush are the oral findings of gastrointestinal disease and a majority of 62.5% of the students were aware of it. 55% students agree that cardiac patients may require to stop aspirin prior to tooth extraction. A minority of 24.3% of the students were aware that supine position is avoided in the management of patients under digitalis.

Among the participants 53.4% knew that gingival bleeding and periodontitis are the most common oral feature in hypertensive patients and around 47% were unaware about it. Premature tooth loss and bad breath are due to poor dental hygiene and 62.2% were aware of it. Around 56.2% of the students were unaware that pregnancy epulis is the common condition during pregnancy. Only 45.4% of students knew that pseudo ankylosis is also seen in scleroderma and the remaining 81.2% were unaware about it. About 53% were aware that oral manifestations of Cushing's syndrome include alveolar bone loss, oral candidiasis, risk of infections may be increased with complex dental procedures. Only 49% were aware that honeycomb plaque is seen in Systemic lupus erythematosus. Around 53.8% of the study participants knew that cobblestone mucosa is seen in Crohn's disease.

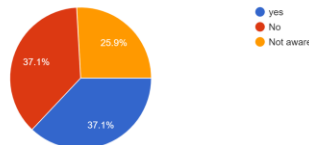
About 57.7% of the students were unaware that the antibiotic protocol for infective endocarditis must be given one hour before the procedure, only 42.2% knew about it. A majority of 64.9% were aware that one must stop the procedure and place the Tab.nitroglycerin sublingually (1 dose every 5 minutes up to 3 doses until pain relieves), If the patient with angina experiences chest pain during dental treatment. Around 49.4% of the participants knew that the management of a patient receiving aspirin or warfarin in a minor oral surgery and the patient's INR with < 3.5 is no adjustment in the warfarin dosage or the dosage should be reduced to allow the INR to fall low or should be stopped before 3 days for the procedure and rest were unclear of it.

About 47% of the study participants knew that epinephrine is the drug to be avoided with patients on digitalis and the remaining 52.9% were in a confused state. A majority of 57% were aware that Bupivacaine is local anaesthesia with high cardiac toxicity. Around 52.2% knew that One can augment clotting during surgery with the use of local hemostatic measures such as local compression, bone wax, oxidised cellulose and Ivy. "Some electrical dental equipment, such as an electrical cautery, a pulp tester, USS, can interfere with early generation- pacemakers". A minority of 43.4% state that the above given statement is true whereas the remaining 56.5% were in an unclear state.

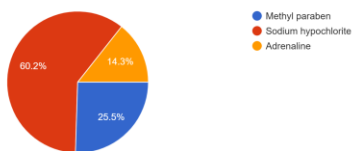
1. Define Dental extraction.  
251 responses



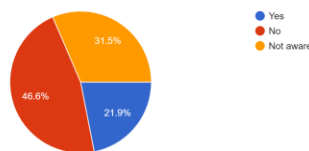
5. Can you extract tooth when patient undergoing menstrual cycle?  
251 responses



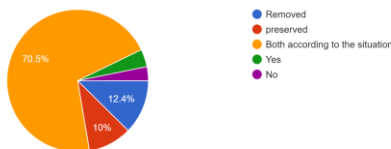
2. Which of the following is not a composition of local anesthesia?  
251 responses



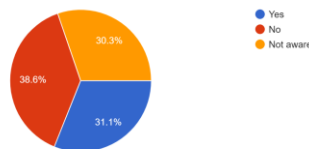
6. Do you believe in the myth "extraction during winter season is not safe"?  
251 responses



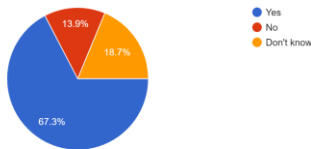
3. Do you believe that the wisdom teeth / 3rd molar should be removed or preserved?  
251 responses



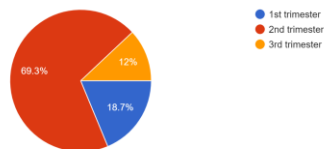
7. Do you believe in the myth that tooth extraction recovery requires 21 days for complete healing?  
251 responses



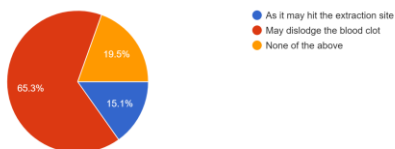
4. Do you think it is true that avoiding alcohol consumption promotes healing after tooth extraction?  
251 responses



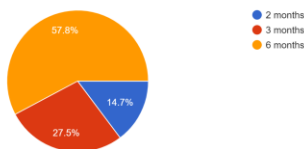
8. Which trimester is safer to perform dental extraction during pregnancy?  
251 responses



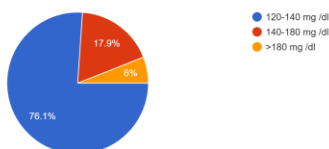
9. Why do they suggest to avoid straw after dental extractions?  
251 responses



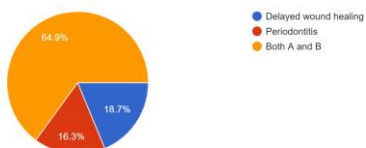
10. After myocardial infarction dental procedure must be avoided for?  
251 responses



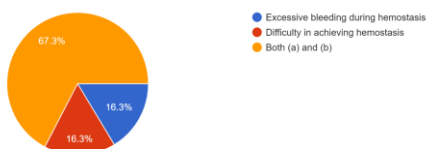
11. What is the normal blood sugar level?  
251 responses



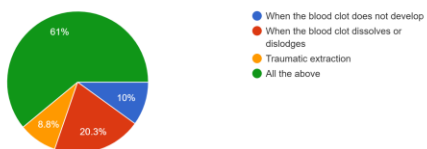
12. What are the oral manifestations of Diabetes?  
251 responses



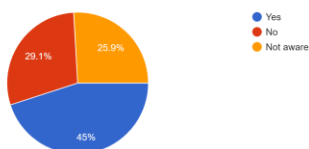
13. What are the complications of dental extractions in patients under anticoagulant therapy?  
251 responses



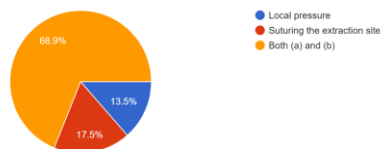
14. Dry socket occurs due to  
251 responses



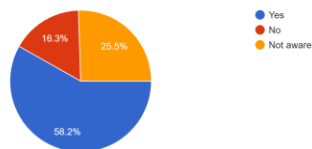
15. Do you believe that a high fever following a tooth extraction is a common occurrence?  
251 responses



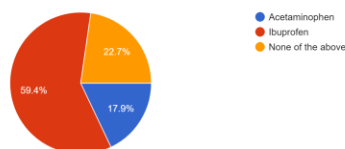
16. Management of patients under anticoagulant therapy during dental extraction.  
251 responses



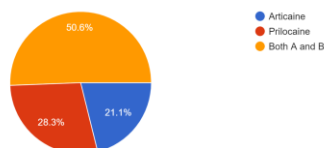
17. Should blood thinners be stopped before dental extraction procedure?  
251 responses



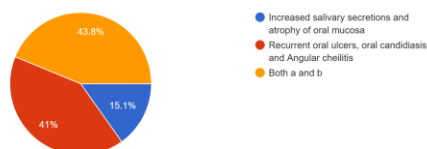
18. Which drug is contraindicated in Asthmatic patients while undergoing dental extractions?  
251 responses



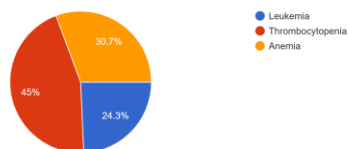
19. Local anesthesia to be avoided in patients with severe anemia.  
251 responses



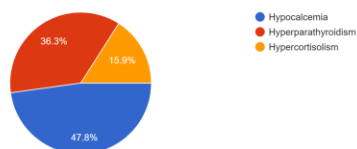
20. What are the oral manifestations of anemia?  
251 responses



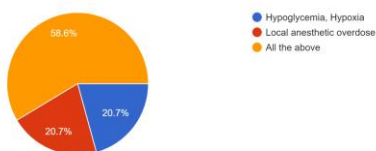
21. Magenta tongue is seen?  
251 responses



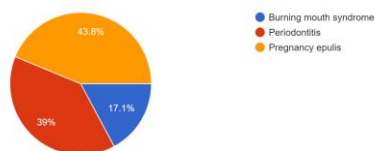
22. Chvostek sign is the hallmark finding of?  
251 responses



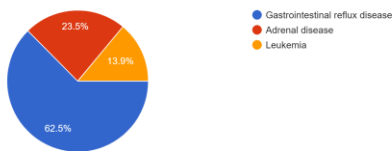
23. Seizure /convulsion can occur due to  
251 responses



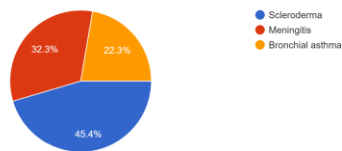
29. Which condition is more common during pregnancy?  
251 responses



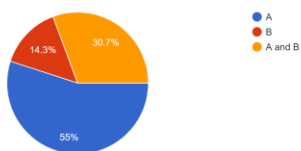
24. Dental erosion and water thrush are the oral findings of?  
251 responses



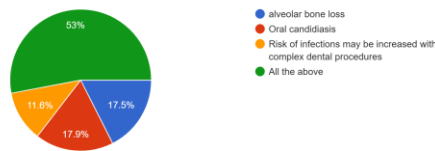
30. Pseudo Ankylosis is seen in?  
251 responses



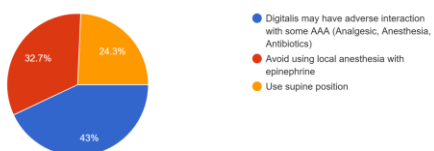
25. Which of the following statements is correct? A) Cardiac patients may require to stop aspirin prior tooth extraction B) Cardiac patients may require to continue aspirin prior tooth extraction  
251 responses



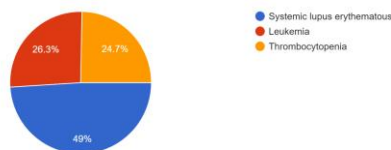
31. The oral manifestations of Cushing's syndrome include  
251 responses



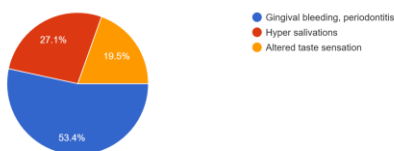
26. Management of patients under digitalis (congestive heart failure) includes all except  
251 responses



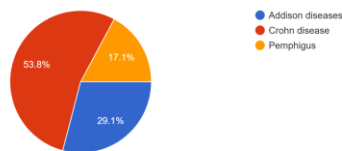
32. Honeycomb plaque is seen in  
251 responses



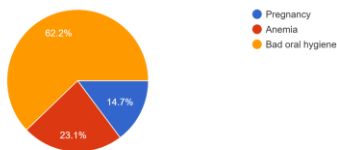
27. What are the most common clinical features seen in hypertensive patients?  
251 responses



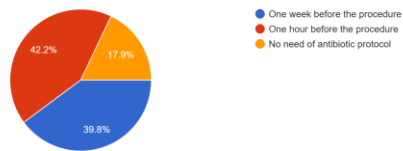
33. Cobblestone mucosa is seen in  
251 responses



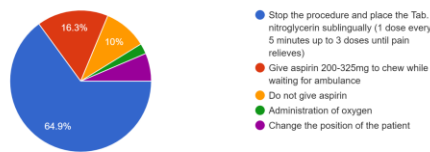
28. Premature tooth loss and bad breath can be due to?  
251 responses



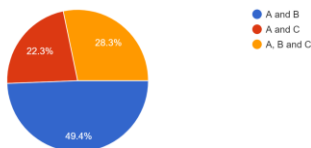
34. The antibiotic protocol for infective endocarditis must be given  
251 responses



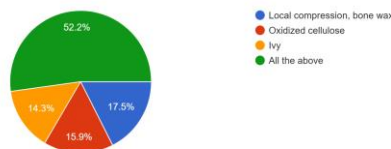
35. If the patient with angina experiences chest pain during dental treatment one must  
251 responses



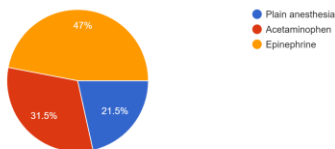
36. The management of patient receiving aspirin or warfarin if it a minor oral surgery and the patient's INR is < 3.5. A) No adjustment in the w...ys for the procedure C) Dosage must be increased  
251 responses



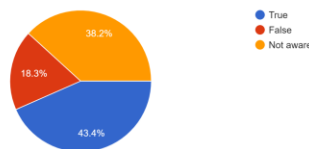
39. One can augment clotting during surgery with the use of local hemostatic measures such as  
251 responses



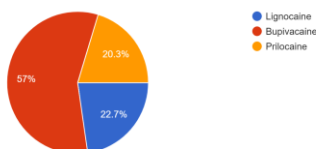
37. What are the drugs to be avoided with patients on digitalis?  
251 responses



40. State whether the following statement is True or False. "Some electrical dental equipment, such as an electrical cautery, a pulp tester, USS, can interfere with early generation- pacemakers".  
251 responses



38. Local anesthesia with high cardiac toxicity.  
251 responses



## DISCUSSION:

Exodontia or extraction of the tooth is defined as the painless removal of the entire tooth or the root with minimum trauma to the investing tissues, so that the wound heals uneventfully and no postoperative prosthetic problem is created. Tooth extraction can be of two types. The intra- alveolar extraction, also called Forceps extraction in which forceps, elevators are used for removal of the tooth. The other being Trans-alveolar extraction where the tooth is removed by sectioning and bone removal, which is also called as Surgical extraction [3].

Awareness among dental students regarding the definition of dental extraction was questioned, out of which most of them were aware of the definition of dental extraction meanwhile 6.4% of the students should be acknowledged theoretically. The Local anaesthetic solution composition is one of the most important entity when it comes to extraction. Sodium hypochlorite has the ability to cause pulpal necrosis and so it is used as an intra canal medicament and to remove the debris in the root canal [4]. Whereas adrenaline and methyl paraben act as vasoconstrictors and Bacteriostatic agents respectively. When given the composition of Local anaesthetic solutions and asked to find the odd component around 60.2% of the students were able to identify the appropriate option i.e Sodium hypochlorite. The wisdom tooth extraction is mostly done as a prophylactic extraction where the patient's jaw is small to accommodate the third molar or in case of any endodontic or periodontal reasons [5]. When questioned about this, the majority claimed that extraction of a third molar must be done only, when necessary, which shows strong ethical consideration.

Consuming alcohol before and after extraction of the tooth can cause an adverse effect on the analgesic effect of the post extraction medication and also might cause dry socket as alcohol thins the blood and might disturb the blood clot formation [6]. Around 67.3% of the participants are aware of this.

Considering tooth extraction during menstruation in women, it is recommended not to undergo extraction as there are more incidences of alveolar osteitis and may cause increased distress to the body due to the hormonal changes 62.9% of the participants were not aware of this [7].

If the patient is a pregnant woman, it is important that the extraction or any other procedure is done only during the second trimester where the mother will be a feeling of well being and by this time the organogenesis of the foetus will be completed [9]. According to Kurien et al. several elective and emergent dentoalveolar procedures are more safely performed during the second trimester because organogenesis is complete and the risk to the foetus is reduced [9]. Majority of the students were correctly aware about this concept and the rest can be educated through theoretical classes. Using straw post extraction can create a negative pressure inside the oral cavity which might dislodge the clot, so it is advised not to use straw at least one week after extraction. Around 65.3% are in favour of this statement.

Normal blood sugar levels in a healthy adult should be between 100 and 140 mg/dL at bedtime. After fasting, it should be between 70 and 100 mg/dL [12]. Though more than 76.1% of the students understand the concept, the rest require significant theoretical education.

According to Bitu Rohani, the oral manifestations of Diabetes Mellitus entail dry mouth (xerostomia), dental caries, periapical lesions, gingivitis, periodontitis, burning mouth, altered taste, geographic tongue, increased susceptibility to infections, and defective wound healing [13]. Majority of them are aware of it and the rest must be educated properly.

A dry socket lesion, according to John Mamoun, is a post-extraction socket with exposed bone that is not covered by a blood clot or healing epithelium and exists inside or around the socket or alveolus for days after the extraction process. It is caused by traumatic extraction, a lack of blood flow to the intaglio surface of the socket and eventual blood flow blockage to the socket [11]. Around 61% of the responders are correctly aware of it and the remaining must be acknowledged by conceptual studies.

Tooth extraction is a surgical procedure where bleeding can occur. In high-risk individuals, the difficulty of the extraction or complications associated with the procedure may increase the risk of bleeding. Prior to performing such a dental procedure, a patient undergoing anticoagulant treatment should be thoroughly assessed. Anticoagulant medications may increase the patient's risk of excessive bleeding during hemostasis and make it more difficult to achieve hemostasis after surgical procedures [14]. According to Abdullah et al., a gauze pressure pack was applied to the extraction site for 30 minutes after extraction. When the bleeding continued to the next day, the patient was asked to report back and managed by a local hemostatic agent, namely oxidised cellulose, with suturing using 3/0 Vicryl [14]. A majority of the students were aware of it and the rest must be educated through a theoretical approach.

For Asthmatic patients Ibuprofen is contraindicated because it worsens symptoms by causing the airways to narrow in a condition known as bronchospasm. Hence the patient should be prescribed an alternative drug for pain relief [20]. Dental erosion is the loss of mineralised structures of the tooth due to chemicals which are not produced by bacteria, it can be due to many extrinsic and intrinsic causes, when quizzed about this around 62.5% considered Gastrointestinal disease as a major cause which is acceptable [21].

According to the ADA, acquired methemoglobinemia is a serious but uncommon condition in which methemoglobin is incapable of carrying oxygen. The use of prilocaine and articaine has been linked to an increased risk of developing methemoglobinemia [22]. Around 49.4% of the students were not aware of it, which is definitely a matter of concern and must be educated through a theoretical approach. This will not only improve theoretical knowledge but also help in clinical practices.

### **Myths in tooth extraction:**

Most people avoid extraction during the winter season believing the myth that extraction can cause a lot of pain which is not true. If a patient is suffering from pain due to dental caries it is always better to consider treating it as the cold air in the winter season exhaled through the mouth will only aggravate the pain. Around 21.9% agreed with the statement. Socket healing will normally take a minimum of 21 days to heal completely. Only 31% of the participants were able to give a more appropriate response [8].

### **Systemic conditions, their oral manifestations and management:**

Cardiovascular system: In A patient who had a history of myocardial infarction, extraction or other dental procedures are mostly indicated only after 6 months of the episode. In case of emergency the procedure has to be done only in a hospital where there is essential care given in case of any episode and about 145 participants are aware of the above mentioned detail [10].

Presence of Erythematous tongue also called magenta tongue is considered as one of the important signs of vitamin B12 deficiency which leads to pernicious anaemia [15]. Only 30% of the students are aware about this. Dr. Franz Chvostek observed a high irritability in the peripheral nerves mostly in the facial nerve when percussed. This is considered as a major sign of Hypocalcemia thus the name "Chvostek sign" [16]. Only 47% of the participants were able to give the answer. Which shows unawareness about the oral manifestations of vitamin and mineral deficiencies among the students. Seizures occur due to uncontrolled hyperexcitation of the neurons. It can be due to hypoxia where a decrease in the oxygen supply to brain causes improper signals [17], in hypoglycemia where the patient may go into COMA if left untreated [18] and seizure can also occur due to Local anaesthetic toxicity or overdose where there will be inhibition of membrane depolarisation and

increased excitation <sup>[19]</sup>. when quizzes about this around 58% agreed that seizure is caused by all the above mentioned reasons.

According to Nilofer et al., The oral manifestation of anaemia includes glossitis, recurrent oral ulcer, erythematous mucositis, angular cheilitis, oral candidiasis, and pallor of oral mucosa <sup>[23]</sup> of which only 41% are aware of and the rest must be theoretically educated.

According to Jagadish et al., systemic sclerosis is a rare connective tissue disorder with a wide range of oral manifestations. The soft tissues surrounding the temporomandibular joint were affected, resulting in pseudo ankylosis. Around 54.5 % were unaware and must be educated theoretically <sup>[24]</sup>.

Fabue et al., described that hypercortisolism can cause alveolar bone loss. This, in turn, can lead to tooth loss. Oral candidiasis is common, and the risk of infection may be elevated by complex dental procedures <sup>[25]</sup>. A honeycomb plaque is a chronic, well-circumscribed plaque characterised by white lacy hyperkeratosis and buccal erythema. The lesion usually affects both the lining and the masticatory tissues. Oral manifestations of Systemic lupus erythematosus are common and can include oral ulceration, honeycomb plaque, purpura, petechiae, and angular cheilitis <sup>[26]</sup>. Crohn's disease is a chronic inflammatory condition. Any part of the gastrointestinal tract, from the mouth to the anus, can be affected. Cobblestone ulcers are small, densely packed lesions that resemble cobblestone streets. Cobblestones can aid in the diagnosis of Crohn's disease <sup>[27]</sup>. The oral manifestations are acknowledged through theory as well by giving reference to standard text books.

According to the AHA, the antibiotic protocol for infective endocarditis must be administered one hour before the procedure for increased effectiveness and compliance <sup>[28]</sup>.

Nitroglycerin is a vasodilatory drug that is currently FDA approved and is used to treat anginal chest pain. Nitroglycerin is usually taken as a tablet and absorbed sublingually. Nitroglycerin may be prescribed to patients as a prophylaxis prior to an event that may cause anginal symptoms. They must be instructed to allow the nitroglycerin to dissolve in their mouth and absorb the drug through their oral mucosa. The dose is repeated every 5 minutes until relief is achieved. The onset of vasodilatory effects occurs within 1 to 3 minutes of administration, with a maximum effect occurring within 5 minutes <sup>[29]</sup>. When a cardiac patient who is under digitalis it is advised to avoid supine position which causes the abdominal organs to compress the lungs and cause distress to the patient. Around 61 participants are aware of this statement <sup>[30]</sup>.

Epinephrine should be avoided in patients taking digitalis because it causes a significant loss of intracellular sodium in mitochondrial and basal cytoplasmic areas, which lowers heart rate and initially increases spike amplitude <sup>[34]</sup>. The Clinical signs seen in the oral cavity in a patient with hypertension is Bleeding gums, gingival enlargement, periodontitis, and hyposalivation seen less frequently. About 53% of the participants were able to give a more appropriate answer <sup>[31]</sup>.

Premature tooth loss and Halitosis occurs due to many reasons. Bad oral hygiene being the most common cause which leads to periodontitis. 62.2% of the respondents showed a positive response for this which shows increased awareness of clinical applied knowledge of the students <sup>[32]</sup>. Epulis in pregnancy is also called Pregnancy tumour. It is a hyperplastic lesion most commonly from the buccal mucosa. 110 students responded with correct answers.

Aronson described that bupivacaine has a powerful depressant effect on electrical conduction in the heart, primarily through an action on voltage-gated sodium channels that govern the initial rapid depolarization of the cardiac action potential. The actions of bupivacaine on channels other than voltage-gated sodium channels are likely to contribute to the dose-dependent cardiotoxic effects of bupivacaine <sup>[35]</sup>. Local hemostatic measures such as local compression, bone wax, oxidised cellulose, and ivy can be used to enhance clotting during surgery <sup>[36]</sup>.

Common dental procedures frequently require the use of electrical equipment, which may come into contact with an implanted pacemaker or defibrillator. Electromagnetic interference (EMI) occurs when one electronic equipment's electromagnetic field interferes with the operation of another electronic device. These electromagnetic signals do have potential to imitate the electrical activity of the heart or to be interpreted as electrical noise by an implanted pacemaker or defibrillator <sup>[37]</sup>.

## CONCLUSION:

The present study clearly shows the lack of knowledge about exodontia, systemic conditions and its oral manifestations, and various myths about dental extraction. Based on the data collected from this study we can conclude that the awareness about Exodontia and the considerations in patients with systemic conditions who are undergoing extraction is Average. When it comes to questions based on the oral manifestations of the systemic conditions the responses obtained are average to low. Participants being aware of oral health and its significance based on their personal experience, this study clearly



emphasises the need for more knowledge and programs to raise awareness of systemic diseases and its oral manifestations in the context of general health among dental students.

## REFERENCES:

- Jain, A. (2021). Principles and Techniques of Exodontia. In: Bonanthaya, K., Panneerselvam, E., Manuel, S., Kumar, V.V., Rai, A. (eds) Oral and Maxillofacial Surgery for the Clinician. Springer, Singapore. [https://doi.org/10.1007/978-981-15-1346-6\\_13](https://doi.org/10.1007/978-981-15-1346-6_13).
- Hussain Ali Albannai. Exodontia: Tips and Pearls. ARC Journal of Dental Science. 2020; 5(2):4-10. DOI: <https://doi.org/10.20431/2456-0030.0502002>.
- "The Extraction of Teeth" by Geoffrey L. Howe, Second edition.
- Goswami M, Chhabra N, Kumar G, Verma M, Chhabra A. Sodium hypochlorite dental accidents. Paediatr Int Child Health. 2014 Feb;34(1):66-9. doi: 10.1179/2046905512Y.0000000042. Epub 2013 Dec 6. PMID: 24090808.
- Friedman JW. The prophylactic extraction of third molars: a public health hazard. Am J Public Health. 2007 Sep;97(9):1554-9. doi: 10.2105/AJPH.2006.100271. Epub 2007 Jul 31. PMID: 17666691; PMCID: PMC1963310.
- How Long Until You Can Drink Alcohol After a Tooth Extraction <https://www.byte.com/community/resources/article/alcohol-after-tooth-extraction/>.
- Eshghpour M, Rezaei NM, Nejat A. Effect of menstrual cycle on frequency of alveolar osteitis in women undergoing surgical removal of mandibular third molar: a single-blind randomized clinical trial. J Oral Maxillofac Surg. 2013 Sep;71(9):1484-9. doi: 10.1016/j.joms.2013.05.004. Epub 2013 Jul 15. PMID: 23866782.
- de Sousa Gomes P, Daugela P, Poskevicius L, Mariano L, Fernandes MH. Molecular and Cellular Aspects of Socket Healing in the Absence and Presence of Graft Materials and Autologous Platelet Concentrates: a Focused Review. J Oral Maxillofac Res. 2019 Sep 5;10(3):e2. doi: 10.5037/jomr.2019.10302. PMID: 31620264; PMCID: PMC6788423.
- Kurien S, Kattimani V S, Sriram R, Sriram S K, Prabhakar Rao V K, Bhupathi A, Bodduru R, Patil N N. Management of Pregnant Patient in Dentistry. J Int Oral Health 2013; 5(1):88-97.
- Chaudhry S, Jaiswal R, Sachdeva S. Dental considerations in cardiovascular patients: A practical perspective. Indian Heart J. 2016 Jul-Aug;68(4):572-5. doi: 10.1016/j.ihj.2015.11.034. Epub 2016 Jan 11. PMID: 27543484; PMCID: PMC4990738.
- Mamoun J. (2018). Dry Socket Etiology, Diagnosis, and Clinical Treatment Techniques. Journal of the Korean Association of Oral and Maxillofacial Surgeons, 44(2), 52–58. <https://doi.org/10.5125/jkaoms.2018.44.2.52>
- Chart of normal blood sugar levels for adults with diabetes age wise. Medically reviewed by : Dr. Surajeet Kumar Patra, MBBS, MD, FDIAB, September 2, 2022, Written by : Dr. Ashwini Sarode Chandrashekara.
- Rohani B. (2019). Oral manifestations in patients with diabetes mellitus. *World journal of diabetes*, 10(9), 485–489. <https://doi.org/10.4239/wjd.v10.i9.485>
- Abdullah, W. A., & Khalil, H. (2014). Dental extraction in patients on warfarin treatment. *Clinical, cosmetic and investigational dentistry*, 6, 65–69. <https://doi.org/10.2147/CCIDE.S68641>
- Systemic Disease Manifestations in the Oral Cavity Geraldine N. Urse, DO, FACOFP Doctors Hospital Family Practice, Grove City, Ohio Osteopathic Family Physician, Volume 6, No. 3, May/June 2014. <https://www.ofpjournal.com/index.php/ofp/article/download/20/19/0>.
- Hujoel IA. The association between serum calcium levels and Chvostek sign: A population-based study. *Neurol Clin Pract*. 2016 Aug;6(4):321-328. doi: 10.1212/CPJ.0000000000000270. PMID: 29443134; PMCID: PMC5727700.
- Ingram J, Zhang C, Cressman JR, Hazra A, Wei Y, Koo YE, Žiburkus J, Kopelman R, Xu J, Schiff SJ. Oxygen and seizure dynamics: I. Experiments. *J Neurophysiol*. 2014 Jul 15;112(2):205-12. doi: 10.1152/jn.00540.2013. Epub 2014 Mar 5. PMID: 24598521; PMCID: PMC4064411.
- Reno CM, Skinner A, Bayles J, Chen YS, Daphna-Iken D, Fisher SJ. Severe hypoglycemia-induced sudden death is mediated by both cardiac arrhythmias and seizures. *Am J Physiol Endocrinol Metab*. 2018 Aug 1;315(2):E240-E249. doi: 10.1152/ajpendo.00442.2017. Epub 2018 Feb 27. PMID: 29486140; PMCID: PMC6139495.
- Mahajan A, Derian A. Local Anesthetic Toxicity. [Updated 2022 Oct 3]. In: StatPearls [Internet]. Treasure Island (FL): StatPearls Publishing; 2022 Jan-. Available from: <https://www.ncbi.nlm.nih.gov/books/NBK499964/>

20. Asthma and ibuprofen: What are the effects? Medically reviewed by Alan Carter, Pharm.D. — By Tom Seymour on September 11, 2017. <https://www.medicalnewstoday.com/articles/319354>
21. Johansson AK, Omar R, Carlsson GE, Johansson A. Dental erosion and its growing importance in clinical practice: from past to present. *Int J Dent.* 2012;2012:632907. doi: 10.1155/2012/632907. Epub 2012 Mar 7. PMID: 22505907; PMCID: PMC3312266.
22. American Academy of Pediatric Dentistry. Use of local anesthesia for pediatric dental patients. *The Reference Manual of Pediatric Dentistry.* Chicago, Ill.: American Academy of Pediatric Dentistry; 2021:332-7.
23. Nilofer H, Chaithra Kalkur, Padmashree S, Anusha L R . Diagnosis of Iron Deficiency Anemia through Oral Manifestation - A Case Report. *JOJ Case Stud.* 2018; 7(4): 555724. DOI: [10.19080/JOJCS.2018.07.555724](https://doi.org/10.19080/JOJCS.2018.07.555724).
24. Jagadish, R., Mehta, D. S., & Jagadish, P. (2012). Oral and periodontal manifestations associated with systemic sclerosis: A case series and review. *Journal of Indian Society of Periodontology*, 16(2), 271–274. <https://doi.org/10.4103/0972-124X.99275>
25. Carlos Fabue L, Jiménez Soriano Y, Sarrión Perez MG. Dental management of patients with endocrine disorders. *J Clin Exp Dent.* 2010;2(4):e196-203. <http://www.medicinaoral.com/odo/volumenes/v2i4/jcedv2i4p196.pdf>
26. Hammoudeh, M., Al-Momani, A., Sarakbi, H., Chandra, P., & Hammoudeh, S. (2018). Oral Manifestations of Systemic Lupus Erythematosus Patients in Qatar: A Pilot Study. *International journal of rheumatology*, 2018, 6052326. <https://doi.org/10.1155/2018/6052326>
27. Crohn's disease and cobblestones explained. Medically reviewed by Saurabh Sethi, M.D., MPH — By Jenna Fletcher on November 14, 2021 <https://www.medicalnewstoday.com/articles/crohns-disease-cobblestone>
28. Thornhill, M. H., Dayer, M., Lockhart, P. B., & Prendergast, B. (2017). Antibiotic Prophylaxis of Infective Endocarditis. *Current infectious disease reports*, 19(2), 9. <https://doi.org/10.1007/s11908-017-0564-y>
29. Kim KH, Kerndt CC, Adnan G, et al. Nitroglycerin. [Updated 2022 Sep 27]. In: StatPearls [Internet]. Treasure Island (FL): StatPearls Publishing; 2022 Jan-. Available from: <https://www.ncbi.nlm.nih.gov/books/NBK482382/>
30. [https://www.google.com/url?sa=i&url=https%3A%2F%2Fwww.digirad.com%2F3-ways-upright-cardiac-imaging-vs-supine%2F&psig=AOvVaw1NkI1bKGe1fDW5O1CNReqf&ust=1670084877437000&source=images&cd=vfe&ved=0CBAQjRxxqFwoTCMDbrZGt2\\_sCFQAAAAAdAAAAABAE](https://www.google.com/url?sa=i&url=https%3A%2F%2Fwww.digirad.com%2F3-ways-upright-cardiac-imaging-vs-supine%2F&psig=AOvVaw1NkI1bKGe1fDW5O1CNReqf&ust=1670084877437000&source=images&cd=vfe&ved=0CBAQjRxxqFwoTCMDbrZGt2_sCFQAAAAAdAAAAABAE) .
31. Kumar P, Mastan K, Chowdhary R, Shanmugam K. Oral manifestations in hypertensive patients: A clinical study. *J Oral Maxillofac Pathol [serial online]* 2012 [cited 2022 Dec 2];16:215-21. Available from: <https://www.jomfp.in/text.asp?2012/16/2/215/99069>.
32. <https://www.marchofdimes.org/find-support/topics/pregnancy/dental-health-during-pregnancy> .
33. Rabinerson D, Kaplan B, Dicker D, Dekel A. [Epulis during pregnancy]. *Harefuah.* 2002 Sep;141(9):824-6, 857, 856. Hebrew. PMID: 12362490.
34. Kenneth R. Keefner, Thomas K. Akers, Sodium localization in digitalis- and epinephrine-treated tunicate myocardium, *Comparative and General Pharmacology*, Volume 2, Issue 8, 1971, Pages 415-422, ISSN 0010-4035, [https://doi.org/10.1016/0010-4035\(71\)90038-3](https://doi.org/10.1016/0010-4035(71)90038-3).
35. J.K. Aronson MA, DPhil, MBChB, FRCP, HonFBPhS, HonFFPM, in *Meyler's Side Effects of Drugs*, 2016
36. Kommu SS, McArthur R, Emara AM, Reddy UD, Anderson CJ, Barber NJ, Persad RA, Eden CG. Current Status of Hemostatic Agents and Sealants in Urologic Surgical Practice. *Rev Urol.* 2015;17(3):150-9. PMID: 26543429; PMCID: PMC4633658.
37. Dental Equipment and Implantable Pacemakers and Defibrillators, Boston scientific, February 2, 2009. [https://www.bostonscientific.com/content/dam/bostonscientific/quality/education-resources/english-a4/EN\\_ACL\\_Dental\\_Equipment\\_20090202.pdf](https://www.bostonscientific.com/content/dam/bostonscientific/quality/education-resources/english-a4/EN_ACL_Dental_Equipment_20090202.pdf)