



INTERNATIONAL JOURNAL OF CREATIVE RESEARCH THOUGHTS (IJCRT)

An International Open Access, Peer-reviewed, Refereed Journal

Review of Glaucoma Detection

Jayesh yadav¹, Jitendra Dangra², Dr. Sandeep Tare³

¹M. Tech Scholar, ²Assistant Professor, ³Associate Professor, Director MER skclnct group
Lakshmi Narain College of Technology, Indore, India

Abstract- The goal of this review article is to explore the usage of a range of image processing technologies in order to provide an automated diagnosis of glaucoma. Glaucoma is a neurological disease that affects the optic nerve. If left untreated, it may cause a person to gradually lose part or all of their vision. It is true that a considerable percentage of people in the world's rural and semi-urban areas suffer from eye issues; nevertheless, this is also the case in all other locations. The diagnosis of retinal illnesses is now almost exclusively accomplished by the processing of images obtained through the study of photographs of the fundus of the retina. Some of the fundamental image processing techniques for diagnosing eye diseases include image registration, picture fusion, image segmentation, feature extraction, image enhancement, morphology, pattern matching, image classification, analysis, and statistical measurements.

Keywords- Image Registration; Fusion; Segmentation; Statistical measures; Morphological operation; Classification.

I. INTRODUCTION

Eye illnesses such diabetic retinopathy, glaucoma, age-based macular degeneration, and others affect a significant number of individuals who live in rural and semi-urban settings. Glaucoma is a medical illness that causes damage to the optic nerve, and it is the second biggest cause of visual loss in the United States. It is often referred to as the "quiet thief of sight." It is accompanied by a progressive degeneration of the optic nerve head (ONH), which is brought on by an elevation of the intraocular pressure inside the eye. The optic nerve is responsible for transmitting picture data to the brain. A blind spot is formed as a result of injury to a significant number of nerve fibres, which ultimately leads to a loss of eyesight. Changes in the appearance of the optic disc might be one of the signs that someone has glaucoma in their eye. The optic disc has an oval form and a vibrant orange-pink hue with a lighter region in the centre. The orange-pink hue fades away as a result of the degeneration of nerve fibres, causing it to seem pale. i.e. an increase in the size of a depression known as a cup and a reduction in the thickness of the neuroretinal rim. The white area in the middle, known as the cup, does not contain any neuroretinal tissue. The cup-to-disc ratio of a typical eye is anywhere between 0.3 and 0.5. The ratio drops to 0.8 when glaucomatous eye is considered.

In Germany, there are around 5 million individuals who are at risk for developing glaucoma, and there are approximately 800,000 people who are affected by glaucomatous damage [1]. It is feasible to do automated early identification of eye illness if optical imaging of the retina is obtained beforehand. This is accomplished by executing a series of image processing processes.

Image processing techniques have been shown to be helpful in the early identification of glaucoma and other eye diseases as a result of recent advancements in the area of medical imaging. Images of the retinal fundus help professionals who have been properly educated to identify any abnormalities or change in the retina. Ophthalmoscopes are the specialised instruments that are used in order to obtain these pictures. Analysis and processing of medical images are becoming more important in the field of non-invasive therapy as well as clinical research. Glaucoma severity may be evaluated with the use of the information gathered about the optic disc. Because it is a key landmark feature, the placement of the optic disc is an essential problem that must be considered in retinal image processing. The fundus camera and the picture of the retinal fundus may be seen in Figure 1.

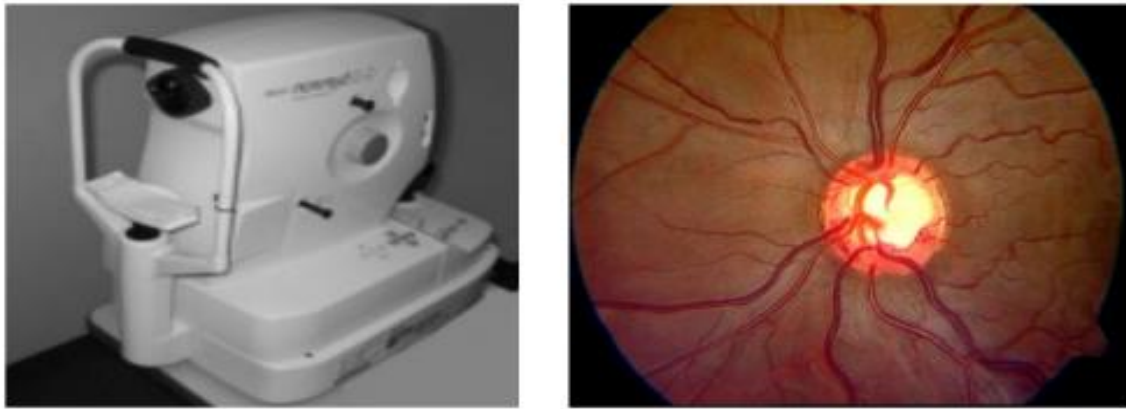


Fig. 1 Digital fundus camera and acquired retinal fundus image

II. IMAGE PROCESSING TECHNIQUE

Enhancement, Registration, Fusion, Segmentation, Feature extraction, Pattern matching, Classification, Morphology, Statistical measurements and Analysis are just some of the various image processing techniques that are utilised in automated early diagnosis and analysis of various eye diseases. Other techniques include: [2][3].

Picture Improvement - Changing an image's brightness and contrast are two components of image enhancement. Filtering and histogram equalisation are also included in this process. It is part of the preprocessing procedure that is used to improve several aspects of the picture.

Image Registration is a critical step in the process of retinal image diagnosis, since it is used to identify any changes that may have occurred. During this step, both of the pictures are brought into alignment on the same coordinate system. There are a variety of timings and imaging tools that may be used to capture an image. When making a medical diagnosis, it is vital to integrate data obtained from a variety of pictures, and geometric alignment of the images is performed so that the results of the analysis and measurements may be improved. [4]

Image Fusion is the process of merging information that was obtained from a variety of imaging equipment. Image fusion is also known as "image stitching." It seeks to do this by incorporating modern information that is multi-sensory, multi-temporal, or multi-view into a single picture that contains all of the information in an effort to limit the quantity of information that is available.

The process of determining and then extracting certain regions of interest from a picture is referred to as "Feature Extraction."

The process of splitting a picture into its component parts, each of which consists of a group of pixels that are identical to one another in accordance with a set of criteria, is known as segmentation. The focus of segmentation algorithms is on the region rather than the individual pixels. The primary purpose of image segmentation is to extract distinct aspects of a picture, which can then be merged or separated in order to produce an object of interest on which analysis and interpretation may be conducted. This is accomplished via a process known as "feature extraction." It involves things like clustering and thresholding, among other things.

Morphology is the study of form, structure, and organisation. It is also known as the science of appearance. Mathematical morphology refers to a group of non-linear operations that may be carried out on a picture in order to eliminate any features that are smaller than a certain reference form. Erosion, dilation, opening and shutting are all examples of different morphological operations.

Image analysis relies heavily on classification as a method for estimating statistical parameters according to the grey level intensities of pixels. Classification is an essential component of image analysis. Labeling a pixel or group of pixels based on the grey values and other statistical characteristics is included in this process. Picture analysis functions are used in order to get a comprehension of the contents of an image. [5].

III. LITERATURE REVIEW

In the published research, there are several studies that report on the identification of optic disc as well as the detection and categorization of glaucoma. The work may be summarised as follows:

Enhancement of retinal fundus image to emphasise characteristics for abnormal eye identification was a project that Kevin Noronha worked on in the year 2006 [6]. This study details the procedures that were carried out in order to identify the primary characteristics of retinal fundus pictures. These characteristics include the optic disc, the fovea, exudates, and blood vessels. Find the brightest portion of the fundus and apply the Hough transform so the author may figure out where the optic disc is and where its centre is.

Sangyeol Lee completed the paper titled "Validation of Retinal Image Registration Algorithms by a Projective Imaging Distortion Model"[4] in the year 2007. There have been many different suggestions made for approaches to retinal image registration. In addition to this, the authors propose a validation tool that can be used with any retinal image registration approach. This tool works by retracing the course of the distortion and obtaining the geometric misalignment from the coordinate system of the reference standard.

S. Sekhar carried out the work "Automated localization of retinal optic disc using hough transform"[7] in the year 2008. The picture of the retinal fundus is used extensively in the diagnostic and therapeutic processes for a broad variety of eye illnesses, including diabetic retinopathy and glaucoma. The approach that has been developed includes two stages: in the first stage, a region of interest (ROI) is located in an image via the use of morphological processing, and in the second stage, an optic disc is identified through the use of the Hough transform.

Zhuo Zhang completed the work "ORIGA-light: An Online Retinal Fundus Image Database for Glaucoma Analysis and Research"[8] in the year 2010. The authors provide an online dataset known as ORIGA-light with the intention of providing the general public with access to clinical retinal pictures. The author maintained a steady stream of system updates that included further clinical ground-truth photos. The segmentation of the optic disc and cup is the primary emphasis of the suggested approach.

Vahabi Z presented "The novel technique to Automatic identification of Optic Disc from non-dilated retinal images"[9] in the year 2010. The author offers a novel filtering methodology to identify Optic Discs, which includes methods such as Sobel edge detection, Texture Analysis, Intensity, and Template matching. The wavelet domain is used to apply the suggested technique to each of the 150 photos in the Messidor dataset.

Zafer Yavuz completed the work "Retinal Blood Vessel Segmentation Using Gabor Filter And Tophat Transform"[10] in the year 2011. The author presented a technique for the segmentation of retinal blood vessels in this work. The approach involves first using a Gabor filter to emphasise the blood vessels, and then using a top-hat transform. At a later stage, the result will be transformed into a binary picture using p-tile thresholding.

Nilan jan Dey carried out the research for the paper "Optical Cup to Disc Ratio Measurement for Glaucoma Diagnosis Using Harris Corner"[11] in the year 2012. In this study, the CDR was calculated using the Harris Corner method. The Harris corner detector [12,13] determines the regional variations of the signal by comparing patches that have been moved in a variety of directions by a negligible amount. The local autocorrelation function of a signal is used as the foundation for this method.

R. Geetha Ramani published her paper "Automatic Prediction of Diabetic Retinopathy and Glaucoma via Retinal Image Analysis and Data Mining Techniques"[5] in the year 2012 [citation needed]. In this study, an innovative method for the automated diagnosis of illness was suggested. Analysis of the retinal pictures and various data mining methods are used so that the retinal images may be reliably classified as either normal, diabetic retinopathy impacted, or glaucoma affected.

Review of Image Processing Techniques for Automatic Detection of Eye Diseases was a proposal that was made by ManjulaSri Rayudu in the year 2012 [14]. This review article explains how image processing methods may be used to automatically diagnose eye disorders. Image registration, fusion, segmentation, feature extraction, enhancement, pattern matching, image classification, statistical measures, and analysis are some of the essential image processing methods for diagnosing eye illnesses.

IV. GLAUCOMA DETECTION ALGORITHM

For assessment of glaucoma, cup-to-disc ratio is most widely accepted index. Early research was done for detection and localization of optic disk. The various algorithms used in this direction are vessel's direction matched filter, curvelet transform, active contour model, fuzzy c-mean clustering, artificial neural networks, k-NN regressor, pyramidal decomposition, edge detection, entropy filter and feature vector[15-21].

Other techniques include averaging filter, template matching technique and canny edge detector. S.Sekhar et al. [22] applied Hough transform to detect Optic Disk. After preprocessing a binary image is obtained which can be used to find the contours of OD. Morphological closing is performed on ROI to calculate the magnitude gradient of edge detection and fill the vessels according to (1).

$$f \bullet B = (f \oplus B) \ominus B \quad (1)$$

For removing any peaks, morphological opening is applied according to (2).

$$f \circ B = (f \ominus B) \oplus B \quad (2)$$

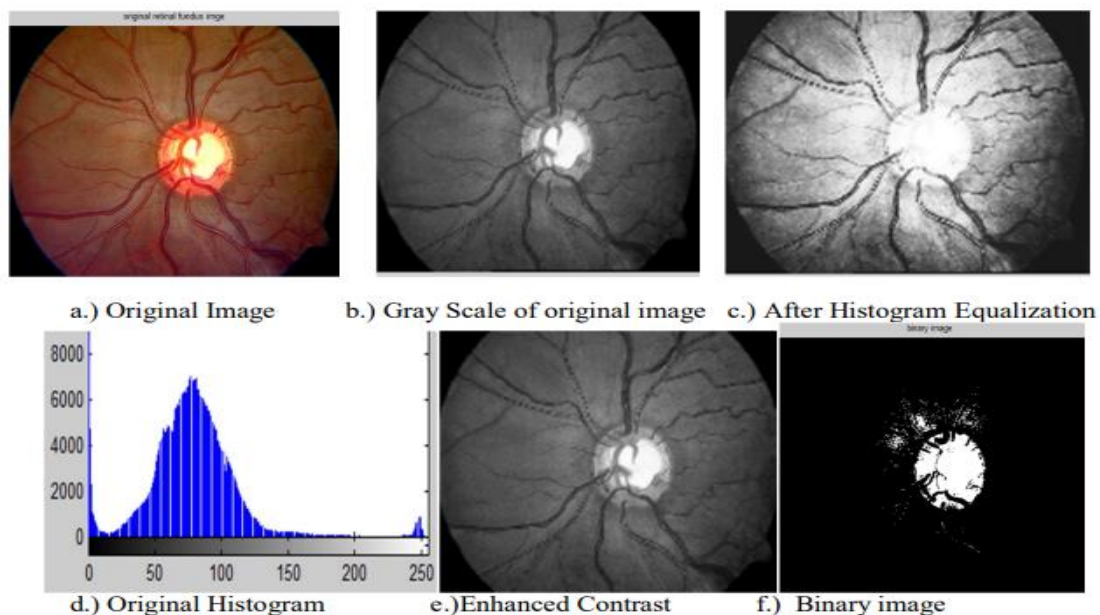
Where f is the grayscale image, B is binary structuring element; \oplus is dilation \ominus is erosion operators

In their study [23], Gopal Dat Joshi and colleagues revealed how to calculate the cup-to-disc ratio (CDR) for the purpose of diagnosing glaucoma by using morphological operations and the Hough transformation. Cup is segmented inside the optic area utilising vessel bends (r-bends for designating cup boundaries), as well as pollar information. These r-bends are scattered in a manner that is not consistent over the OD area. Therefore, a local interpolating spline is used for the purpose of cup border detection.

The matched filter strategy was suggested by Aliaa Abdel and colleagues [15]. During the preprocessing stage, the illumination equalisation technique and the adaptive histogram equalisation approach are used to respectively normalise the luminance and contrast of the image. A two-dimensional Gaussian-matched filter is used in order to segment the retinal vessels. R. Chrastek and colleagues [24] presented a technique for segmenting the head of the optic nerve and validated their approach. Morphological procedures, the Hough transform, and an active contour model are all components of this technique.

V. RESULTS

As a part of survey of various image processing techniques, the author has implemented some of the techniques like preprocessing; histogram equalization morphological operation etc. and result are as follows:



VI. CONCLUSION

In order to begin the process of glaucoma detection and diagnosis, the author of this study came to the realisation that the optic disc has to be segmented as the very first stage in the procedure. After the phase of capturing images has been finished, the preprocessing stage will start with the application of thresholding, lighting, and histogram equalisation. The optic disc and cup are segmented using a variety of techniques, such as the Hough transform, k-means clustering, fuzzy c-means clustering, active contour method, matching filter approach, vascular bends, and morphological processes. After that, the CDR is calculated, and classification is conducted so that it may be determined whether or not the patient's eye condition is normal or glaucomatous.

References

- [1] Initiativkreis zur Glaukomfrüherkennung, Germering, Germany, www.glaukom.de
- [2] R.ManjulaSri,KMM Rao, "Novel Image Processing Techniques to Detect Lesions using Lab View", IEEE Conference Publications on Annual IEEE India Conference INDICON. Publication Year: 2011 , Page(s): 1-4
- [3] Viralkumar Bulsara, Surabhi Bothra, Poonam Sharma, K.M.M.Rao, "Low Cost Medical Image Processing System for Rural/Semi Urban Healthcare", IEEE Conference Publications on Recent Advances in Intelligent Computational Systems (RAICS),Publication Year: 2011 , Page(s): 724 – 728
- [4] Sangyeol Lee, Michael D. Abr` amoff, and Joseph M. Reinhardt." Validation of Retinal Image Registration Algorithms by a Projective Imaging Distortion Model" 29th Annual International Conference of the IEEE EMBS Cité Internationale, Lyon, France August 23-26, 2007.
- [5] R. Geetha Ramani," Automatic Prediction of Diabetic Retinopathy and Glaucoma through Retinal Image Analysis and Data Mining Techniques"
- [6] Kevin Noronha, Jagadish Nayak, S.N. Bhat, "Enhancement of retinal fundus Image to highlight the features for detection of abnormal eyes"
- [7] S. Sekhar," Automated localisation of retinal optic disk using hough transform", Department of Electrical Engineering and Electronics, University of Liverpool, UK.
- [8] Zhuo Zhang," ORIGA-light : An Online Retinal Fundus Image Database for Glaucoma Analysis and Research", 32nd Annual International Conference of the IEEE EMBSBuenos Aires, Argentina, August 31 - September 4, 2010
- [9] Vahabi Z," The new approach to Automatic detection of Optic Disc from non-dilated retinal images" Proceedings of the 17th Iranian Conference of Biomedical Engineering (ICBME2010), 3-4 November 2010

- [10] Zafer Yavuz," RETINAL BLOOD VESSEL SEGMENTATION USING GABOR FILTER AND TOPHAT TRANSFORM", 2011 IEEE 19th Signal Processing and Communications Applications Conference (SIU 2011) 978-1-4577-0463-511/11 ©2011 IEEE
- [11] Nilanjan Dey," Optical Cup to Disc Ratio Measurement for Glaucoma Diagnosis Using Harris Corner", ICCVNT12
- [12] Harris C, Stephens, M. , 1988, A Combined Corner and Edge Detector, Proceedings of 4th Alvey Vision Conference
- [13] Konstantinos G Derpanis, 2004, The Harris Corner Detector
- [14] Manjula Sri Rayudu," Review of Image Processing Techniques for Automatic Detection of Eye Diseases", 2012 Sixth International Conference on Sensing Technology (ICST) 978-1-4673-2248-5/12 ©2012 IEEE
- [15] Aliaa Abdel-Haleim Abdel-Razik Youssif, Atef Zaki Ghalwas, and AmrAhmed SabryAbdel-Rahman Ghoneim ,"Optic Disc Detection From Normalized Digital Fundus Images by Means of a Vessels' Direction Matched Filter-IEEE Transactions On Medical Imaging, Vol. 27, No. 1, January 2008
- [16] Zhuo Zhang et al. "MRMR Optimized Classification for Automatic Glaucoma Diagnosis"-33rd Annual International Conference of the IEEE EMBS, Boston, Massachusetts USA, August 30 - September 3, 2011
- [17] Mahdad Esmacili, Hossein Rabbanin and Alireza Mehri Dehnavi: "Automatic optic disk boundary extraction by the use of curvelet transform and deformable variational level set model" in Pattern Recognition, Vol. 45 (2012) , pp. 2832–2842
- [18] Chisako Muramatsu et al.,"Automated segmentation of optic disc region on retinal fundus photographs: Comparison of contour modeling and pixel classification methods" in Computer Methods And Programs In Biomedicine Vol.101 (2011) , pp. 23–32.
- [19] Meindert Niemeijer, Michael D. Abramoff and Bram van Ginneken" Fast detection of the optic disc and fovea in color fundus photographs" in Medical Image analysis, in press.
- [20] Rashid Jalal Qureshi et al. "Combining algorithms for automatic detection of optic disc and macula in fundus images; Computer Vision and Image Understanding ,Vol. 116 (2012) ,pp.138–145
- [21] Chih-Yin Ho, Tun-Wen Pai, Hao-Teng Chang and Hsin-Yi Chen, " An automatic fundus image analysis system for clinical diagnosis of glaucoma",-2011 International Conference on Complex, Intelligent, and Software Intensive Systems.
- [22] S.Sekhar,W.Al-Nuaimy and A.K.Nandi,"Automated Localisation Of Retinal Optic Disk Using Hough Transform", 5th IEEE International Symposium on Biomedical Imaging: From Nano to Macro, 2008, pp.1577 - 1580
- [23] Gopal Datt Joshi, Jayanthi Sivaswamy, and S. R. Krishnadas,"Optic Disk and Cup Segmentation From Monocular Color Retinal Images for Glaucoma Assessment', IEEE Transactions On Medical Imaging, Vol. 30, No. 6, June 2011,pp.1192-1205.
- [24] R. Chrastek et al. " Automated segmentation of the optic nerve head for diagnosis of glaucoma" in Medical Image Analysis, Vol.9(2005), pp.297-314.