



AN OVERVIEW OF DEEP VEIN THROMBOSIS, IT'S TREATMENTS AND PREVENTIONS

PRIYANKA NALLOLLA*¹

JEMIMAH GERA²

STUDENT OF JOGINPALLY B.R. PHARMACY COLLEGE¹.

FACULTY OF JOGINAPPLY B.R. PHARMACY COLLEGE, DEPARTMENT OF PHARMACOLOGY².

JOGINPALLY B.R. PHARMACY COLLEGE, YENKAPALLY, MOINABAD, HYDERABAD, TELANGANA, INDIA.

ABSTRACT:

Deep vein thrombosis (DVT) is a form of blood clot that develops in the leg or pelvic deep veins. Deep vein thrombosis (DVT) is a clinical condition that affects a lot of people and has a high fatality rate. The most serious DVT consequence, acute pulmonary embolism (PE), requires prompt care. DVT is a significant global source of morbidity and mortality that can be prevented. An estimated 1 in 1,000 people are affected with venous thromboembolism (VTE), which comprises DVT and pulmonary embolism (PE) and is responsible for 60,000–100,000 deaths each year. For a number of years, the recommended course of treatment was to apply a low molecular weight heparin (LMWH) or fondaparinux subcutaneously, followed by a vitamin K antagonist (VKA). In practical, the so-called direct oral anticoagulants (DOAC) for the treatment of VTE were just recently launched. Oral anticoagulation is the mainstay of DVT treatment since it slows the growth of the thrombus and lowers the risk of pulmonary embolism. Depending on the symptoms, more aggressive procedures may be used to remove the iliofemoral thrombus. The Virchow's triad, three mechanisms is how venous thrombosis happens. The blood flow is reduced, the blood artery wall is damaged, and the likelihood that the blood may clot is raised. The choice of anticoagulant medication, dose, and duration of treatment must take the unique circumstances of each DVT patient into consideration. Several therapeutic alternatives are available for DVT treatment.

Key Words: Thrombosis, Venous thrombosis, Arterial thrombosis, Deep vein thrombosis, Pulmonary embolism, Thrombolytic therapy, Vena cava filter.

INTRODUCTION:

The growth of an abnormal mass made of blood components within the circulatory system of a living animal is referred to as "thrombosis". Deep vein thrombosis is the term used to describe this phenomenon when it happens in the deep veins (DVT). To avoid the potentially deadly acute complication of pulmonary embolism (PE), as well as the long-term repercussions of post phlebitis syndrome and pulmonary hypertension, an accurate diagnosis of DVT is crucial. ⁽¹⁾ The development of post-thrombotic syndrome, which affects up to

50% of patients within two years of DVT and includes symptoms like leg discomfort, swelling, and in severe cases, venous ulcers, is largely responsible for the morbidity of DVT. ^(2,3)

Venous stasis, vascular damage, and hypercoagulability are the three contributory variables identified by Virchow's Triad, which was initially introduced in 1856. Venous stasis is the most important of the three elements, yet stasis by itself does not seem to be enough to result in thrombus development. ⁽⁴⁾ The National Heart, Lung, and Blood Institute and former U.S. Surgeon General Richard H. Carmona held the Surgeon General's Workshop on Deep Vein Thrombosis in May 2006. (DVT). This meeting's objectives were to increase knowledge of deep vein thrombosis (DVT) and pulmonary embolism (PE), as well as to pinpoint potential new research avenues in these fields. ⁽⁵⁾ Each year, DVT and PE cause numerous avoidable fatalities. According to estimates, at least 100,000 deaths could be caused directly or indirectly by DVT and PE each year, and 350,000 to 600,000 Americans could die from these conditions. ⁽⁶⁾

WHAT IS THROMBOSIS?

A blood clot can form in the vasculature as a result of thrombosis, which can affect both the arterial and venous systems. Myocardial infarction, stroke, pulmonary embolism (PE), and limb ischemia are just a few of the disorders it affects. This specialist issue will address thrombosis-related subjects, with a strong emphasis on venous thrombotic disorders.

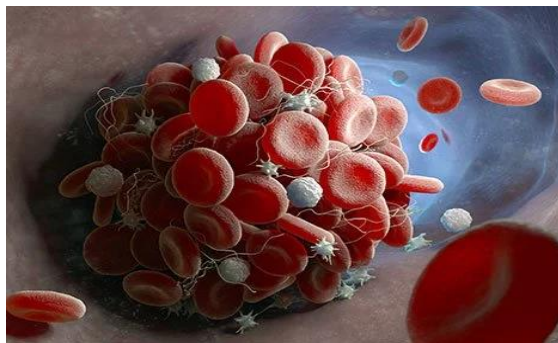


Figure-1: **Clotting of blood with blood vessels.**

There are 2 main types of thrombosis:

1. **Venous thrombosis:** Venous thrombosis is when the blood clot blocks a vein. Veins carry blood from the body back into the heart.
2. **Arterial thrombosis:** Arterial thrombosis is when the blood clot blocks an artery. Arteries carry oxygen-rich blood away from the heart to the body.

Blood flow can be obstructed by thrombosis in both veins and arteries. Depending on where the thrombosis occurs, there may be complications. The most serious problems include stroke, heart attack, and serious breathing problems.

1. VENOUS THROMBOSIS:

Blood clots in the veins are referred to as venous thromboembolism (VTE), which is a serious but avoidable medical illness that can result in disability and even death. In general, Deep vein thrombosis (DVT) and pulmonary embolism are the two sub types (PE). Numerous inherited or acquired disorders that affect coagulation, such as genetic coagulopathies, advanced age, obesity, trauma, surgery, infection, cancer, or pregnancy, can result in VTE.

Management of venous thromboembolism includes using different anticoagulant medications that have the biggest procoagulant elements. Although arterial thrombosis management involves antiplatelet medications as single- or dual-antiplatelet therapy. ⁽²⁵⁾

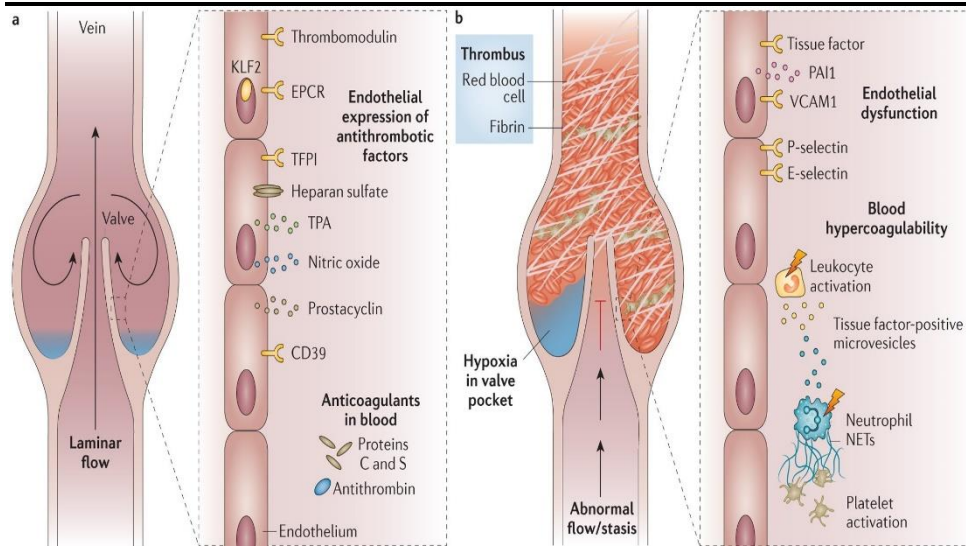


Figure-2: a & b represents difference between normal and effected veins by thrombosis

(A) DEEP VEIN THROMBOSIS:

When a blood clot develops in a deep vein, a condition known as deep vein thrombosis (DVT) takes place. These clots can form in the arm, although most typically form in the lower leg, thigh, or pelvis. DVT is something that everyone should be aware of because it can result in significant disease, disability, and in very extreme situations, death. The good news is that DVT can be treated and prevented if caught early. Venous thromboembolism (VTE), which includes deep vein thrombosis (DVT), is a leading global cause of morbidity and mortality that can be easily avoided. DVT accounts for around two-thirds of the annual incidence of VTE, which is estimated to be 1 per 1,000 persons. ^(7,8)

DVT is most commonly found in the calf portion of the leg. The majority of thrombi originate in the deep veins below the popliteal trifurcation (distal DVT), which are most likely to dissolve spontaneously without causing any symptoms. Deep-vein thrombosis forms when there is clot in arm, leg or pelvis. PE occurs when part of DVT breaks off and travels through blood stream to the lungs, causing a blockage in the blood vessel of the lungs. A frequent and dangerous disorder is deep vein thrombosis (DVT). It is a sign of venous thromboembolism, which, after heart attacks and strokes, is the third most common cause of mortality from cardiovascular disease. ^(26,27)

Deep Vein Thrombosis

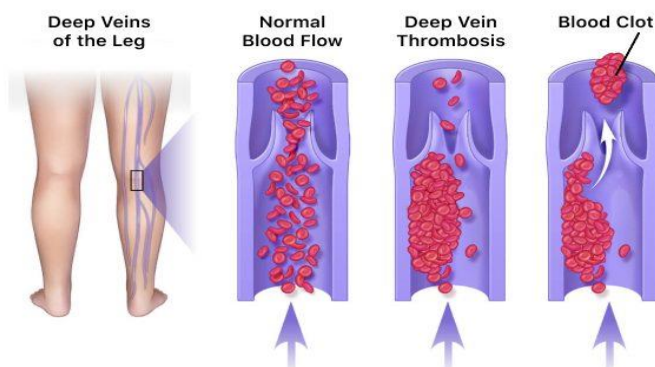


Figure-3: Formation of Deep vein thrombosis

(B) PULMONARY EMBOLISM:

A blood clot in a lung artery blocks blood flow to a portion of the lung, resulting in a pulmonary embolism (PE). Most frequently, blood clots begin in the legs, move through the right side of the heart, and enter the

lungs. Pulmonary embolism is caused when a thrombus that originates elsewhere obstructs blood flow in the pulmonary artery or one of its branches (PE).

Acute and potentially fatal disorder known as pulmonary embolism (PE) occurs when embolic material, typically a thrombus from a deep pelvic or leg vein, plugs one or more pulmonary arteries, impairing blood flow and increasing pressure in the right cardiac ventricle. ⁽⁹⁾

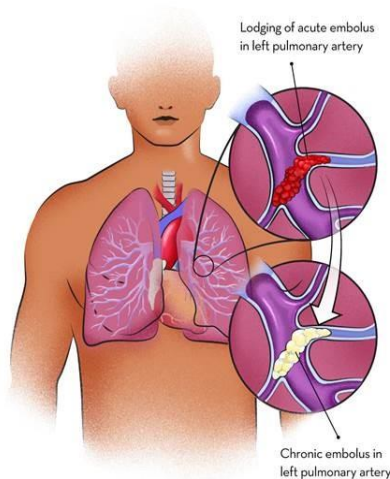


Figure-4: Pulmonary embolism

ARTERIAL THROMBOSIS:

Atherosclerosis is most frequently linked to arterial thrombosis. An anatomic source, most frequently a cardioembolic one like an intracardiac thrombus, atrial appendage thrombus, patent foramen ovale with paradoxical embolus, or valve vegetation, may be the cause of arterial thrombosis in cryptogenic cases. ⁽¹⁰⁾

Arterial thrombosis can present as an acute stroke, myocardial infarction, or acute on the chronic peripheral arterial disease. Other less common sites can include renal arteries, mesenteric arteries, and retinal arteries. In addition to acute management (not reviewed here), secondary prevention focuses on reducing cardiovascular risk factors such as obesity, high cholesterol, diabetes, high blood pressure, and encouraging lifestyle modification such as smoking cessation. The increased incidence of obesity, hypertension, and hypercholesterolemia all contribute to the risk of acquiring an arterial thrombosis.

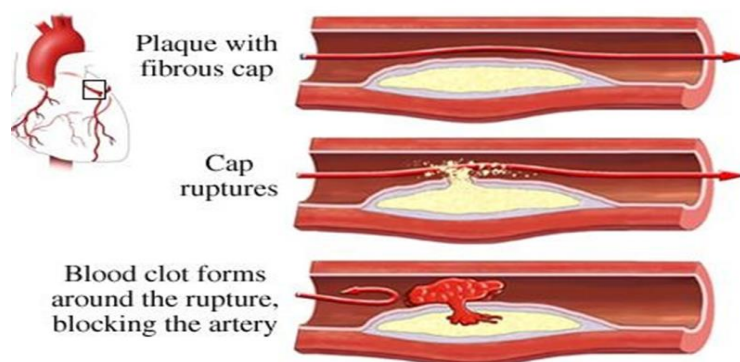


Figure-5: Formation of arterial thrombosis due to rupture of cap.

This involves an artery forming a thrombus. Blood veins called arterials transport oxygenated blood from the heart to different parts of the body. Depending on the extent of the thrombosis and the artery in which it occurs, arterial thrombosis cases can range from mild to severe. Deficits in protein C, protein S, and antithrombin are uncommon but important risk factors for venous thrombosis, but they have little to no effect on arterial thrombosis. ⁽²⁸⁾

DIAGNOSIS:

The use of diagnostic imaging to confirm DVT is common. Due to its safety, accessibility, affordability, and dependability, US is the primary imaging modality for the diagnosis of proximal DVT. Conventional contrast venography, computed tomography (CT) venography, and magnetic resonance (MR) venography are further diagnostic imaging techniques for DVT. ⁽¹¹⁾

It can effectively gauge a thrombus's size, chronicity, and degree of blockage, which helps guide decisions about whether to seek medical therapy or interventional procedures. An US probe is utilised during the examination to gently squeeze the vein of interest. DVT is diagnosed when the vein cannot be compressed. The Wells scoring criteria and D-dimer assay are added to US. US is not required in patients with a negative D-dimer who are "unlikely" to have DVT. US is advised in similarly stratified patients with a positive D-dimer. Finally, US is preferable instead of D-dimer in individuals who have a concomitant disease linked to an increased D-dimer. Conventional contrast venography, computed tomography (CT) venography, and magnetic resonance (MR) venography are further diagnostic imaging modalities for DVT. The gold standard for treating lower extremity DVT is contrast venography, although it has its limitations due to factors like patient discomfort, user dependency, poor vision, and patient-specific issues like contrast allergy and renal failure. ⁽²⁹⁾

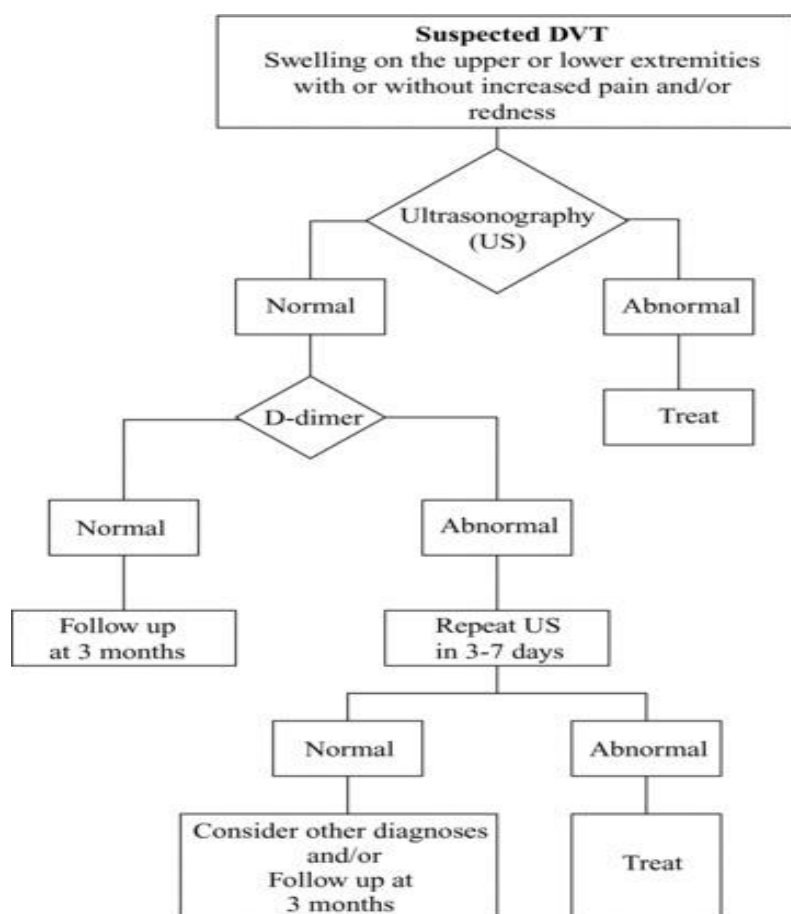


Figure-6: **Diagnosis of deep vein thrombosis**

- **D-dimer test:** After a blood clot is broken down by fibrinolysis, a protein fragment known as D-dimer is released into the blood. A probable blood clot is indicated by a test result that contains more D-dimer than a particular threshold. However, people with certain inflammatory disorders and those recovering from surgery may find that this test is not accurate.
- **Ultrasound:** This sort of imaging can identify whether a blood clot is acute or chronic, as well as changes in blood.

- **Flow Venogram:** A physician may order this scan if the results of the ultrasound and D-dimer tests are insufficient. The doctor injects a dye into a vein in the foot, knee, or groin. X-ray scans can track the moving dye to find a blood clot.
- **Other imaging examinations:** CT and MRI scans can reveal the presence or absence of a clot. These scans could find blood clots while checking for numerous medical issues.

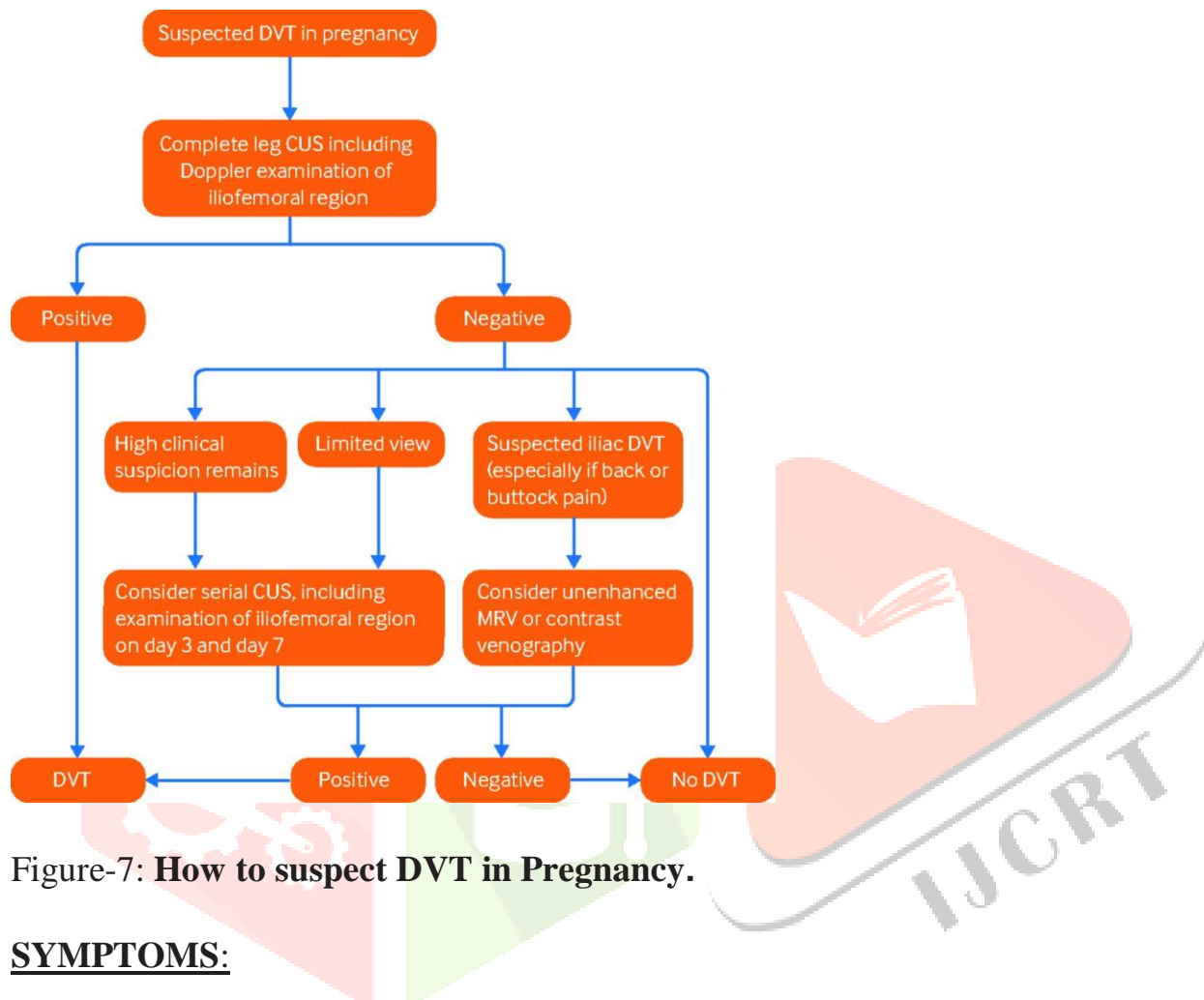


Figure-7: **How to suspect DVT in Pregnancy.**

SYMPTOMS:

Deep vein thrombosis (DVT) symptoms can include:

- Swollen legs.
- Leg cramps, soreness, or pain that frequently begins in the calf.
- A change in skin tone on the leg, maybe appearing red or purple depending on your skin tone.
- Warmth on the leg that is being affected.

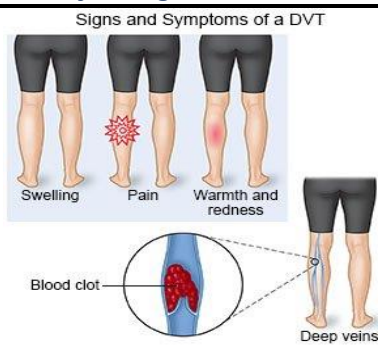


Figure-7: Symptoms of a Deep vein thrombosis

TREATMENTS:⁽¹²⁾

The aims of treatment are:

- To stop the clot from growing and spreading further up the vein.
- This may stop a significant embolus from separating and travelling to the lungs (a PE).
- To minimise the likelihood that post-thrombotic syndrome will develop. to lessen the chance of developing leg venous ulcers in the future. Post-thrombotic syndrome sufferers may experience this.
- To lower the chance of developing another DVT later.

Thrombolytic therapy:

Rarely is this suggested. The advantages of a full and speedy lysis of thrombi should be evaluated against the danger of serious bleeding, including cerebral haemorrhage. It should be suspected in cases of severe DVT that result in phlegmasia cerulea dolens and possible limb loss. In recent years, endovascular thrombolytic techniques have advanced significantly. As a supplement to conventional therapy, catheter-directed thrombolysis (CDT) can be used to treat DVTs. 106 Comparing CDT to systemic anticoagulation, current research indicates that CDT can lessen clot load and DVT recurrence and, as a result, decrease the development of post-thrombotic syndrome.⁽¹³⁾

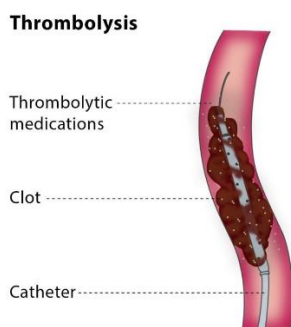


Figure-8: Thrombolytic therapy

Vena cava filters:

Very few situations call for vena cava filters. Absolute contraindication to anticoagulation, life-threatening bleeding while anticoagulating, and insufficient anticoagulation are a few of them. 108 Central nervous system (CNS) haemorrhage, overt gastrointestinal bleeding, retroperitoneal haemorrhage, extensive haemoptysis, cerebral metastases, massive cerebrovascular accident, CNS trauma, and substantial thrombocytopenia ($<50,000/L$) are all absolute contraindications to anticoagulation.⁽¹⁴⁾ They can be recovered or not, with the majority of recently produced ones being recoverable. There were significantly

fewer PE patients in the near term, but no meaningful influence on PE, according to studies evaluating the effectiveness of filters. In the long run, there was a greater rate of recurring DVT.⁽¹⁵⁾

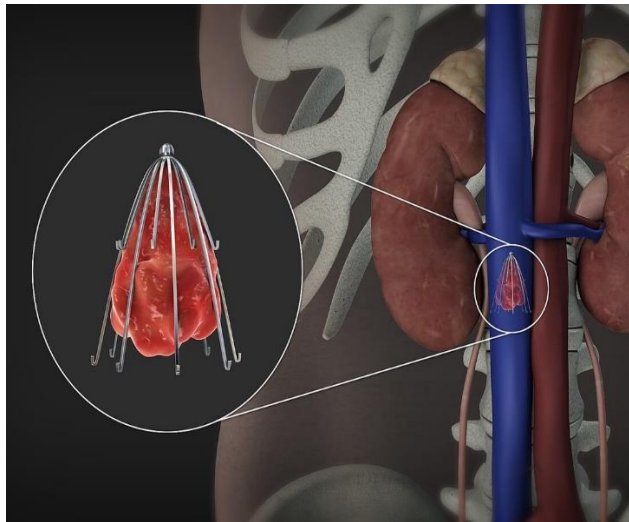


Figure-9: Inferior Vena cava filter.

Surgical Removal:

Since acute recurrence frequently complicates thrombectomy despite postoperative anticoagulant medication, it is only marginally beneficial and leaves a highly thrombogenic deendothelialized venous surface.⁽¹⁶⁾

In patients with phlegmasia cerulea dolens and approaching venous gangrene, it is recommended to remove venous blockage as quickly as possible. Although pulmonary embolectomy may be a life-saving therapy for a patient with a severe embolism, this type of surgery is rarely performed in hospitals due to a lack of equipment, staff, or facilities. Furthermore, some candidates for emergency pulmonary embolectomy survive and respond well to medical therapy, but the majority of patients who are likely to benefit from pulmonary embolectomy pass away before they can be identified and treated. On the other hand, in some individuals with persistent large-vessel thromboembolic pulmonary hypertension, an elective pulmonary thromboendarterectomy can be extremely beneficial and life-saving.^(17,18)

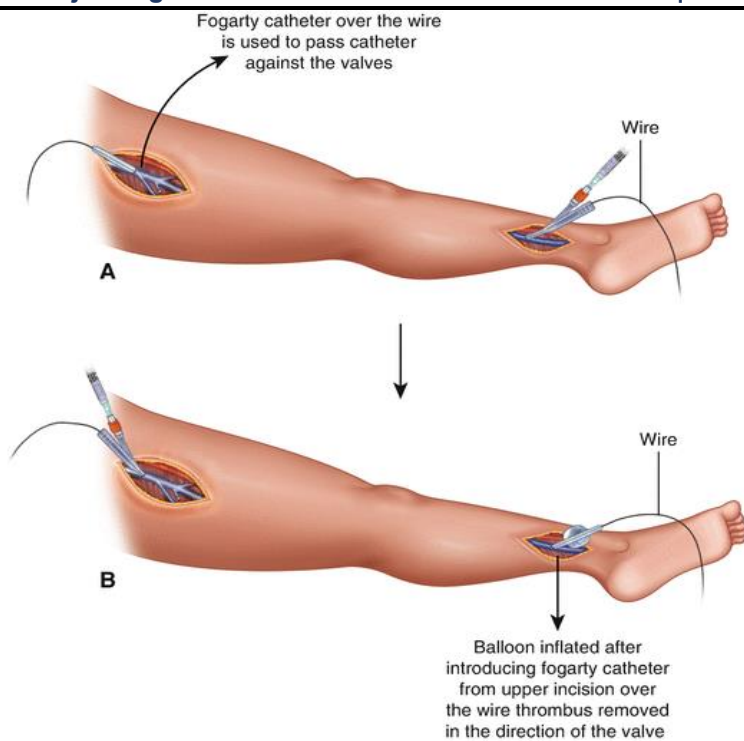


Figure-10: Surgical removal of Deep vein thrombosis

DRUGS USED:

- ❖ APIXABAN(ELIQUIS)
- ❖ BETRIXABAN(BEVYXXA)
- ❖ DABIGATRAN(PRADAXA)
- ❖ EDOXABAN(SAVAYSA)
- ❖ FONDAPARINUX(ARIXTRA)
- ❖ HEPARIN
- ❖ RIVAROXABAN(XAREITO)
- ❖ WARFARIN

Oral Rivaroxaban:

The short-term and ongoing treatment of venous thrombosis with rivaroxaban is straightforward and only requires one medication, potentially enhancing the benefit-to-risk ratio of anticoagulation. because using a vitamin K antagonist for treatment necessitates lab monitoring, dose modification, and may be confounded by drug and dietary interactions. The annual risk of serious bleeding caused by vitamin K antagonists is 1 to 2% after the first year. Consequently, despite the substantial long-term risk of recurrent venous thromboembolism, the relative merits of continuing medication are still up for debate. Administration of an oral anticoagulant that is effective as a single drug for the treatment of acute venous thromboembolism and for continuing treatment but does not require laboratory monitoring could be a straightforward answer to some of these problems. ⁽¹⁹⁾

Warfarin:

Warfarin should be used as an initial treatment along with an immediate-acting medication, such as LMWH, for at least 5 days or until the INR reaches 2.0. Although the therapeutic dose is widely varied, the first treatment is typically 5 mg once daily. People who are low in body weight, aged, or infirm often need a lesser dose. In such people, a starting dose of 2-3 mg should be taken into consideration. Prior to achieving a stable, in-range INR, frequent monitoring is necessary. Thereafter, testing should occur less frequently. There are numerous pharmacological and food interactions involving warfarin that have an impact on INR. INR testing

should be connected to changes in concurrent drugs and new concurrent illnesses. Patients should maintain a constant, balanced diet rather than being urged to consume fewer foods high in vitamin K.

Dabigatran Etxilate: A New Oral Thrombin Inhibitor.

The thrombin clotting time (TT), which directly evaluates the activity of thrombin in a plasma sample, the activated partial thromboplastin time (aPTT), which targets the intrinsic pathway of coagulation, and the ecarin clotting time, which is a specific assay for thrombin generation, are all prolonged by dabigatran. Dabigatran, which targets the extrinsic coagulation pathway, has comparatively little impact on the prothrombin time and INR at clinically relevant plasma concentrations. The TT assay, ecarin clotting time, and [aptt] are the tests that are most sensitive to dabigatran's ability to prolong them. Maximum blood coagulation times are prolonged (by about two hours) at dabigatran peak plasma concentrations. At 12 hours following injection, the impact is reduced to 50% of the peak inhibition, which reflects the drug's half-life. (20)

EDOXABAN:

Edoxaban is a factor Xa direct oral inhibitor that can bind to and inhibit both free and unbound factor Xa. At the HOKUSAI-VTE study, a sizable randomised double-blind non-inferiority study with 8292 patients recruited in 439 centres in 37 countries, edoxaban and warfarin were compared in the treatment of VTE. (21)

ANTICOAGULANTS:

- The drugs most frequently used to treat DVT or PE are anticoagulants, also known as "blood thinners." Despite being referred to as blood thinners, these drugs do not really thin the blood. They lessen the blood's capacity to clot, which lowers the chance of creating more clots and prevents the clot from growing larger as the body gradually reabsorbs it.
- Anticoagulants that are taken orally (swallowed) include
 - Warfarin,
 - Dabigatran,
 - Rivaroxaban,
 - Apixaban, and
 - Edoxaban.

RISK FACTORS:

Following are the risk factors and are considered as causes of deep venous thrombosis:

- Blood flow is decreased: immobility (bed rest, general anaesthesia, operations, long flights)
- Mechanical compression or a functional issue that restricts vein flow (e.g., neoplasm, pregnancy, varicose veins)
- Mechanical damage to the vein, such as trauma, surgery, peripherally placed venous catheters, a history of DVT, or usage of intravenous drugs
- Increased blood viscosity, such as from dehydration or thrombocytosis
- Thrombosis may be facilitated by anatomical variances in venous architecture.

Antithrombin, protein C or S deficiency, and antiphospholipid syndrome studies for thrombophilia were left to the treating physicians' discretion and were carried out either before to starting oral anticoagulant therapy or at least three weeks after it was finished. To establish the presence of thrombophilia, every abnormal test performed during the acute VTE stage had to be redone. The Sapporo criteria, which required repeating the abnormal tests at least 12 weeks apart in every case, were used to determine the diagnosis of antiphospholipid syndrome. (22)

The interquartile range of the median age was 32 to 60 years, and 72.84% of the population was female. The most common risk factors, accounting for 51.85% and 35.60% respectively, were found to be HIV and TB. Other

risk factors were smoking (25.93%), having recently been hospitalised (34.57%), having previously experienced DVT (19.75%), and having congestive heart failure (18.52%).⁽²³⁾

The presence of central venous lines, malignancy, and chemotherapy are the most significant triggering risk factors for development of thromboembolism in the paediatric age range. Clinical diseases linked to hypercoagulability states include severe infections, sickle cell disease, trauma, and antiphospholipid syndromes.⁽²⁴⁾

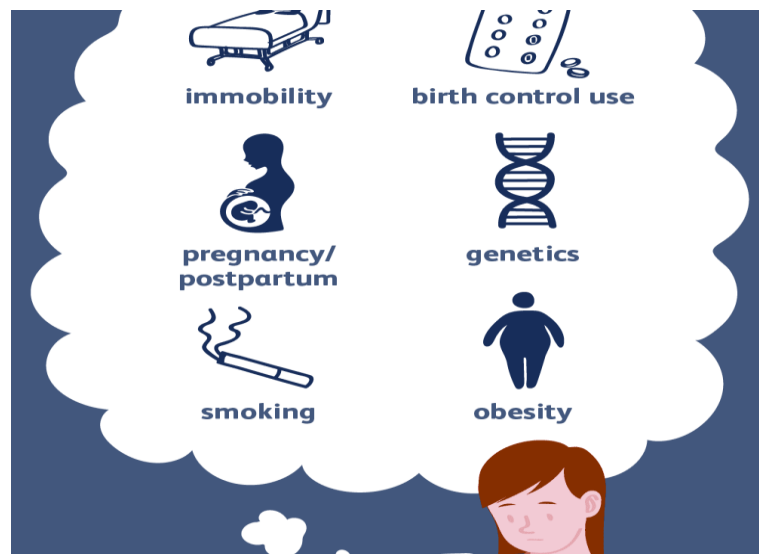

Figure-11: Risk factors of Deep vein thrombosis.

PREVENTION:

DVT preventive methods include preventing stasis and reversing blood coagulability alterations that cause thrombi to develop.

Drugs have proved successful in lowering the prevalence of pulmonary embolism and DVT. For individuals who have had surgery, low-dose subcutaneous heparin is regarded as a practically perfect DVT preventive. The biggest drawback of using subcutaneous anticoagulants for DVT on a regular basis is the potential of bleeding, but this risk can be reduced by careful patient selection. Oral warfarin is the medicine of preference for maintenance anticoagulation to avoid DVT recurrence after anticoagulant therapy with heparin, often for 7 to 10 days. Heparin is used as an initial anticoagulant, followed by warfarin for maintenance, in the same way that it is used to treat DVT in the treatment of pulmonary embolism.

CONCLUSION:

DVT is a potentially dangerous clinical condition that can lead to preventable morbidity and mortality. A diagnostic pathway involving pre-test probability, D-dimer assay, and venous ultrasound serves as a more reliable way of diagnosing DVT. Prevention consists of both mechanical and pharmacological modalities and is encouraged in both inpatients and outpatients who are at risk of this condition. The goal of therapy for DVT is to prevent the extension of thrombus, acute PE, recurrence of thrombosis, and the development of late complication such as pulmonary hypertension and post-thrombotic syndrome.

Prophylaxis is very important and can be mechanical and pharmacological. The mainstay of treatment is anticoagulant therapy. Low-molecular-weight heparin, unfractionated heparin, and vitamin K antagonists have been the treatment of choice. Currently anticoagulants specifically targeting components of the common pathway have been recommended for prophylaxis. These include fondaparinux, a selective indirect factor Xa inhibitor and the new oral selective direct thrombin inhibitors (dabigatran) and selective factor Xa inhibitors (rivaroxaban and apixaban).

REFERENCES

1. Emeka Kesieme,¹ Chinenye Kesieme,² Nze Jebbin,³ Eshiobo Irekpita,¹ and Andrew Dongo¹ Deep vein thrombosis: a clinical review. *J Blood Med.* 2011; 2: 59–69. Published online 2011 Apr 29.
2. Galanaud JP, Kahn SR. Post thrombotic syndrome: a 2014 update. *Curr Opin Cardiol* 2014; 29:514-9.
3. Kahn SR, Shrier I, Julian JA, et al. Determinants and time course of the post thrombotic syndrome after acute deep venous thrombosis. *Ann Intern Med* 2008; 149:698-707. 10.7326/0003-4819-149-10-200811180-00004.
4. Wessler S, Reimer SM, Sheps MC. Biologic assay of a thrombosis-inducing activity in human serum. *J Appl Physiol* 1959; 14:943-6.
5. Steven K. Galson, MD, MPH RADM. Prevention of deep vein thrombosis and pulmonary embolism. *Public Health Rep.* 2008 Jul-Aug; 123(4): 420–421.
6. Census Bureau (US) Nation's population to reach 300 million on Oct. 17. U.S. Census Bureau News. *Department of Commerce (US)* 2006. Oct 12, [cited 2008 Mar 14].
7. Beckman MG, Hooper WC, Critchley SE, et al. Venous thromboembolism: a public health concern. *Am J Prev Med* 2010;38: S495-501. 10.1016/j.amepre.2009.12.017.
8. White RH. The epidemiology of venous thromboembolism. *Circulation* 2003;107: I4-8. 10.1161/01.CIR.0000078468.11849.66
9. White RH: The epidemiology of venous thromboembolism. *Circulation.* 2003, 107: i4-i8.
10. Matthew O'Donnell, Joseph J. Shatzel, Sven R. Olson, Molly M. Daughety, Khanh P. Nguyen, Justine Hum, Thomas G. DeLoughery. Arterial thrombosis in unusual sites: A practical review. First published: 21 August 2018.
11. Min SK, Kim YH, Joh JH, et al. Diagnosis and Treatment of Lower Extremity Deep Vein Thrombosis: Korean Practice Guidelines. *Vasc Specialist Int* 2016; 32:77-104. 10.5758/vsi.2016.32.3.77.
12. Li Li, Jia Zhou, Liquan Huang, Junhai Zhen, Lina Yao, Lingen Xu, Weimin Zhang, Gensheng Zhang, Qijiang Chen, Bihuan Cheng, Shijin Gong, Guolong Cai, SRonglin Jiang, Jing Yan & (Zhejiang Provincial Critical Care Clinical Research Group) Prevention, treatment, and risk factors of deep vein thrombosis in critically ill patients in Zhejiang province, China: a multicenter, prospective, observational study. Pages 2236-2247 | Received 05 Aug 2021, Accepted 08 Nov 2021, Published online: 19 Nov 2021
13. Patterson BO, Hinchliffe R, Loftus IM, Thompson MM, Holt PJ. Indications for catheter-directed thrombolysis in the management of acute proximal deep venous thrombosis. *Arterioscler Thromb Vasc Biol.* 2010;30(4):669–674.
14. Streiff MB. Vena caval filters: a comprehensive review. *Blood.* 2000;95(12):3669–3677.
15. Decousus H, Leizorovicz A, Parent F, et al. A clinical trial of vena caval filters in the prevention of pulmonary embolism in patients with proximal deep-vein thrombosis. Prévention du Risque d'Embolie Pulmonaire par Interruption Cave Study Group. *N Engl J Med.* 1998; 338(7):409–415.
16. Lansing AM, Davis WM. Five-year follow-up study of iliofemoral venous thrombectomy. *Ann Surg.* 1968; 168:620-628.
17. Moser KM, Daily PO, Peterson K, Dembitsky W, Vapnek JM, Shure D, Utley J, Archibald C. Thromboendarterectomy for chronic, major-vessel thromboembolic pulmonary hypertension: immediate and long-term results in 42 patients. *Ann Intern Med.* 1987; 107:560-565.
18. Moser KM, Auger WR, Fedullo PF. Chronic major-vessel thromboembolic pulmonary hypertension. *Circulation.* 1990; 81:1735-1743.
19. Kearon C, Kahn SR, Agnelli G, Goldhaber S, Raskob GE, Comerota AJ. Antithrombotic therapy for venous thromboembolic disease: American College of Chest Physicians Evidence-Based Clinical Practice Guidelines (8th edition). *Chest* 2008;133: Suppl:454S-545S
20. Liesenfeld K-H, Schäfer HG, Troconiz IF, Tillmann C, Eriksson BI, Stangier J. Effects of the direct thrombin inhibitor dabigatran on ex vivo coagulation time in orthopedic surgery patients: a population model analysis. *Br J Clin Pharmacol.* 2006; 62:527–537.

21. Investigators Hokusai-VTE, Buller HR, Decousus H, et al. Edoxaban versus warfarin for the treatment of symptomatic venous thromboembolism. *N Engl J Med*. 2013;369(15):1406–1415. doi: 10.1056/NEJMoa1306638.
22. Miyakis S, Lockshin MD, Atsumi T, et al. international consensus statement on an update of the classification criteria for definite antiphospholipid syndrome (APS). *J Thromb Haemost*. 2006; 4:295–306.
23. Damilola Awolesi¹ Mergan Naidoo¹ Mohammed H. Cassimjee¹. The profile and frequency of known risk factors or comorbidities for deep vein thrombosis in an urban district hospital in KwaZulu-Natal. *Southern African Journal of HIV Medicine* ISSN: (Online) 2078-6751, (Print) 1608-9693. Published: 13 May 2016.
24. Gertzias GT. Risk factors for venous embolism in children. *Int Angiol*. 2004;**23**(3):195–205.P
25. Alisa S Wolberg, Frits R Rosendaal, Jeffrey I Weitz, Iqbal H Jaffer, Giancarlo Agnelli, Trevor Baglin, Nigel Mackman., Venous thrombosis, *Nat Rev Dis Primers*. 2015 May 7; 1:15006.
26. Fatemeh Moheimani and Denise E. Jackson., Venous Thromboembolism: Classification, Risk Factors, Diagnosis, and Management, *ISRN Hematol*. 2011; 2011: 124610.
27. Sheikh M. Waheed¹; Pujitha Kudaravalli; David T. Hotwagner²., *Deep Vein Thrombosis, Books*, Last Update: August 11, 2021.
28. Seligsohn U, Lubetsky A. Genetic susceptibility to venous thrombosis. *N Engl J Med*. 2001; 344:1222–31.
29. Guyatt GH, Norris SL, Schulman S, et al. Methodology for the development of antithrombotic therapy and prevention of thrombosis guidelines: Antithrombotic Therapy and Prevention of Thrombosis, 9th ed: American College of Chest Physicians Evidence-Based Clinical Practice Guidelines. *Chest* 2012; 141:53S–70S.

