



A RARE DISEASE DYKE-DAVIDOFF MASSON SYNDROME-CASE SERIES

¹Dr. Manashwini Jageer, ²Dr. Himaja Siripuram, ³Dr. Shaik Abdullah, ⁴Dr. Vidya Rachakonda

¹Masters in Public Health, ²MD General Medicine, ³MBBS, ⁴Masters in Health informatics

¹Master in Public Health,

¹University of Southern Mississippi, Mississippi, USA

ABSTRACT:

Dyke-Davidoff-Masson Syndrome (DDMS) is a rare condition characterized by seizures, facial asymmetry, contralateral hemiplegia, learning difficulties,^[1] and mental retardation caused by an injury to the developing brain during prenatal or postnatal development. In addition, MR imaging reveals cerebral hypertrophy with ipsilateral sinus hypertrophy. This study reports two cases presenting recurrent seizures and classic imaging features, which were subsequently diagnosed as DDMS based on a cross-sectional CT and MRI study.

KEYWORDS: Cerebral Hemiatrophy, Recurrent seizures, Calvarial thickening, Dyke-Davidoff-Masson Syndrome.

INTRODUCTION:

Dyke-Davidoff-Masson syndrome (DDMS) is characterized by cerebral hemiatrophy, calvarial thickening, hyperpneumatization of the frontal sinuses, and facial asymmetry.^[2] Some patients can also present with sensory symptoms and psychiatric disorders like schizophrenia. Cerebral hemiatrophy or DDMS is characterized by seizures, hemiplegia or hemiparesis, and mental retardation, usually due to an insult to the developing brain in fetal or early childhood. The clinical features are variable and depend on the patient's age and the extent of brain injury. It is usually secondary to trauma to the developing brain in utero or early childhood. Trauma to the developing brain results in the loss of neurons that comprise the growth of the developing brain, leading to mental retardation, seizures, and learning disabilities. The presentation of classically observed characteristics depends on the age of trauma to the developing brain. Childhood presentation may differ from that of adults if the trauma to the brain presents later in life. Although the etiology of DDMS is still debated, trauma, infection, intracranial bleeding, congenital vascular anomalies, and peritoneal hypoxia are the leading causes of this syndrome. Early neuroimaging in patients with intractable epilepsy will make early diagnosis and better outcomes.

CASE-1

An 18 years male, born full-term vaginal delivery, to non-consanguineous marriage, without any family history, presented with recurrent episodes of generalized tonic-clonic seizures(9-10 episodes/day). The seizures episode was followed by decreased movement of the left side of the body and drooling of saliva from the mouth for 5-10mins after each episode, and the patient had involuntary micturition during each seizure episode; in view of the above condition, he was admitted to the Intensive care unit at a renowned multispeciality hospital, Telangana, India.

The patient had a past history of febrile seizures at three years of age, with recurrent episodes occurring at least 2-3 times a year. There was no history of head trauma, but he had delayed development of milestones, unable to stand or walk. He did not attend school, and on examination, the child was undernourished with poor cognitive function and delayed psychomotor development. He denied any history of central nervous system infections, head injury, status epilepticus, or skin lesions. However, his parents noticed behavioral problems like disturbed sleep, irritability, anger outbursts, suspiciousness, and irrelevant talk. At eight years of age, the patient was started on antiepileptic treatment oral Clobazam 10mg and Tab Levipil 250mg; he responded well to the drugs, followed by physiotherapy. Since then, he was seizure free for the next two years but unfortunately developed seizures again.

On examination, Vitals were normal. Positive clinical findings were severe mental retardation, poor intelligence, and left-sided facial palsy. Examination of other systems was unremarkable; No neuro-cutaneous markers were present.

Laboratory investigations of the patient reveal that Complete blood count, Renal and liver function tests were normal. Radiographs of the skull illustrate the thickening of the calvarium and dilatation of the ipsilateral frontal and ethmoid sinuses. Magnetic resonance imaging (MRI) revealed unilateral atrophy of the right cerebral hemisphere and ex-vacuo dilatation of the ipsilateral lateral ventricle with the prominence of sulci. Computerized Tomography of the brain shows a chronic infarct in the right cerebral hemisphere, atrophic changes in the right cerebral hemisphere, and hyper pneumatization of the right frontal sinus.

CASE-2

A 29-year-old right-handed female of Warangal resident presented with complaints of focal seizures involving left upper and lower limbs, tonic-clonic type, sudden onset, with four episodes lasting for 3 minutes each and a gap of 3-5 minutes between them, not preceded by any aura, associated with the history of uprolling of eyeballs during the seizure. History of loss of consciousness after the first attack with no regain of consciousness in between the seizures-no history of tongue bite/frothing from the mouth, and no evidence of bowel and bladder incontinence. The patient was immediately rushed to a local doctor and was given intravenous fluids, and the patient regained consciousness 3 hrs after the last bout, accompanied by postictal confusion for one hour.

After regaining consciousness, the patient suddenly noticed difficulty in getting up from a sitting position, associated with difficulty in walking, but she was able to walk with the support of her mother; the patient also noticed a problem in wearing and holding slippers with her left foot. At the same time, the patient noticed difficulty grasping objects with the left hand associated with easy slippage of things and a history of difficulty raising the arm overhead.

Weakness in the left upper and lower limbs was simultaneous and non-progressive, and there was no improvement in the weakness later. Occasionally it is associated with stiffness in the left upper and lower limbs. The patient could feel clothes and hot and cold sensations over the body. History of burning sensations(paresthesias) over the left half of the body has been present since then.

The patient had also developed recurrent attacks of left focal seizures involving the left upper limb and lower limb in the form of tonic-clonic movements preceded by aura in the form of dizziness at a frequency of 1-2 times in a month, 3-4 times during each episode with LOC for 30 minutes to 1 hour despite taking medication from a local doctor. In addition, weakness of the left upper and lower limbs and burning sensations persisted.

Now, the patient presented to our hospital with left focal seizures four days back, three episodes for 20 minutes with LOC for 4 hours, and no regain of consciousness between the seizures associated with postictal confusion for 2 hours. No history of tongue bite or bowel and bladder incontinence.

The birth history of the patient includes that she is a product of non-consanguineous marriage, 3rd in the birth order. Normal vaginal delivery at nine months of gestational age, no history of developmental delay/mental retardation. Her menstrual history reveals she attained menarche at 12 years with regular cycles on 5/30. No similar complaints in the family.

On examination, the patient is conscious, coherent, and comfortably sitting on the chair, moderately built and nourished. Skull and spine are normal with no facial asymmetry/ rash over the face or body/ neurocutaneous markers/ pallor/ icterus/ cyanosis/ koilonychia/ lymphadenopathy/ pedal edema/ thyromegaly.

Anatomical localization data reveals Motor – a left UMN type of weakness with left focal seizures - involves the right cerebral cortex (frontal lobe motor cortex). Sensory – paresthesias over the left side of the body with intact pain, touch, and temperature – the right cerebral cortex - parietal lobe. MMSE scores 28/30 with normal lobar functions.

Complete blood count, serum electrolytes, and renal and liver function tests are normal. Electroencephalogram of the brain reports continuous irregular theta slow wave activity and reduced amplitude over the right hemisphere, more over the parietal cortex.

MRI shows -Dilated sulcal spaces and volume loss involving the right cerebral parenchyma more over the parietal cortex with ipsilateral thickening of frontal bone and enlargement of the right frontal sinus, Ex-Vacuo dilatation of the right lateral ventricle, and Areas of leukoencephalomalacia involving the right perisylvian cortex. The features are likely to be those of the **DYKE DAVIDOFF MASSON SYNDROME**.

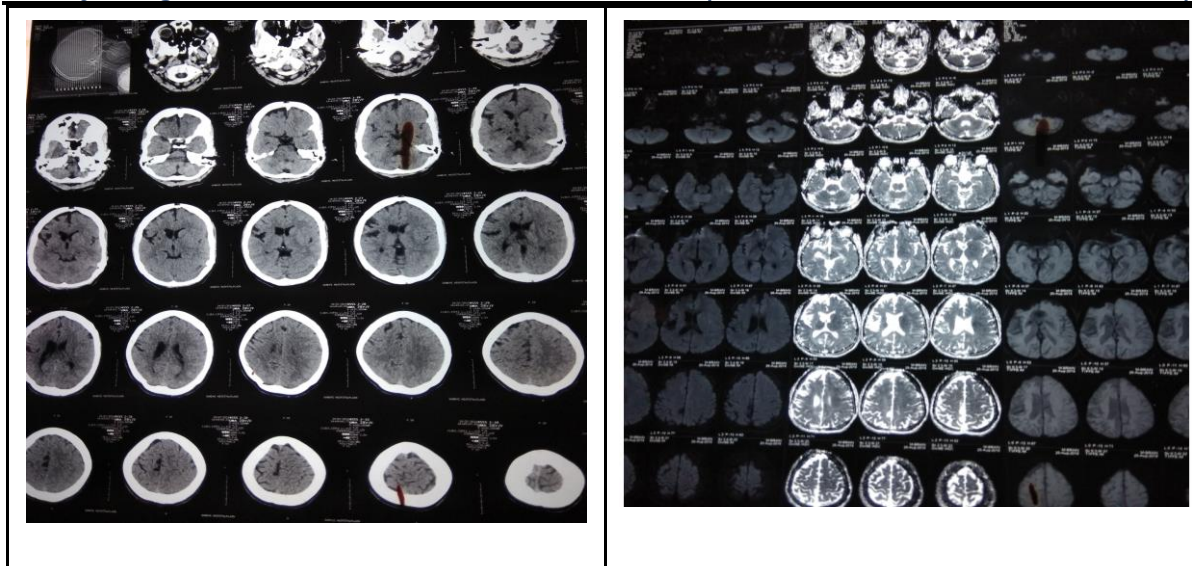


Figure 1. MRI shows -Dilated sulcal spaces and volume loss involving the right cerebral parenchyma more over the parietal cortex with ipsilateral thickening of frontal bone and enlargement of the right frontal sinus.

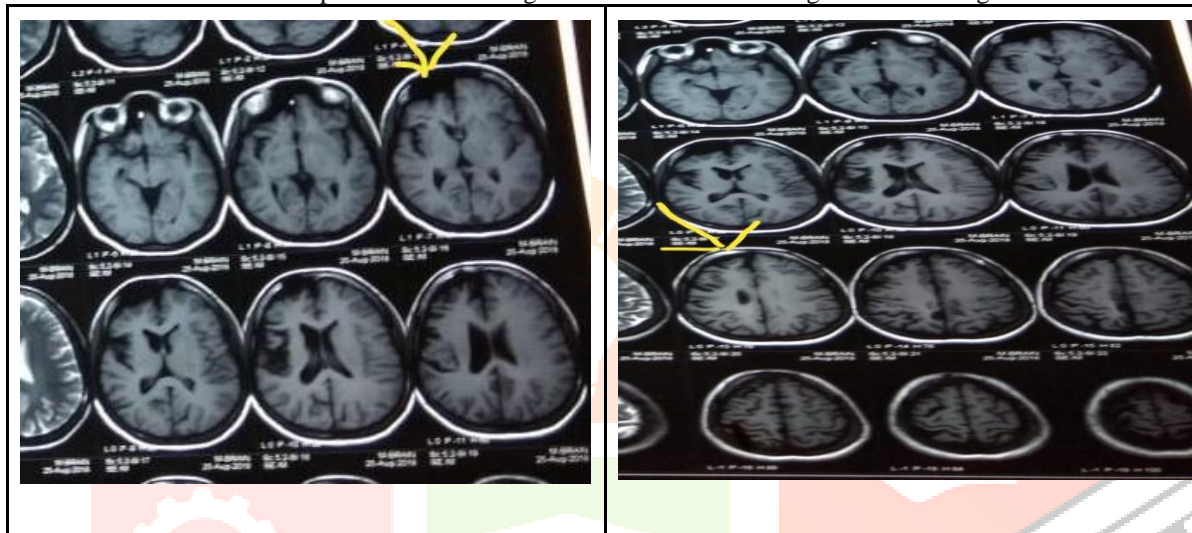


Figure 2. MR Images showed right cerebral hemispheric atrophy with mild dilatation of the right lateral ventricle.

DISCUSSION:

Dyke-Davidoff-Masson syndrome is a rare syndrome characterized by cerebral hemiatrophy /hypoplasia secondary to brain insult in the fetal or early childhood, thickening of the skull vault, Ipsilateral falcine displacement, capillary malformations, and enlargement of the frontal sinus. Clinically characterized by seizures, facial asymmetry, contralateral hemiparesis, and mental retardation with learning disabilities. DDMS is sometimes seen in clinical practice but is one of the important causes of recurrent and refractory seizures.^[3] This syndrome refers to atrophy or Hemi-atrophy of one cerebral hemisphere, secondary to brain insult in the fetal or early childhood. The clinical presentations and radiological features can vary depending on the extent of cerebral damage and the patient's age.^[3] Predominantly, there is no sex predilection or any particular cerebral hemisphere involvement. Both sexes and any of the hemispheres may be affected, but male gender and left-side involvement are more common.

DDMS results from a cerebral insult that occurs in utero when the calvarium has not fully matured or during early childhood due to damage to the brain. The brain sulci formation occurs between the fourth to end of the eighth month of fetal life.^[3] Prenatal causes include congenital abnormalities, cerebral infarction, vascular malformations, infections, and gestational vascular occlusion, primarily involving the middle cerebral vascular territory. In addition, birth trauma, hypoxia, intracranial hemorrhage, tumors, infections, and prolonged febrile seizures after birth corresponds to peri- and postnatal causes. Whenever the brain is subjected to injury of any kind before three years of age, the bony skull overlying the brain grows inward, resulting in an increased width of the diploic spaces, para nasal sinuses, and elevation of the petrous ridge, and orbital roof, which are tell-tale features of this disorder.^[3]

Cerebral hemiatrophy can be of two types, infantile (congenital) and acquired form, which becomes symptomatic in the infancy or perinatal period and results from fetal vascular occlusion involving unilateral cerebral arterial circulation, concretely middle cerebral artery territory anomalies, coarctation of the mid aortic arch culminating in mesencephalon hypoplasia and Wallerian degeneration. The infantile variety results from numerous etiologies such as infections, neonatal or gestational vascular occlusions, unilateral cerebral arterial circulation abnormalities, and mid-aortic arch coarctation. The perinatal period or infancy is when patients become symptomatic. The leading causes of acquired type are trauma, tumor, infection, ischemia, hemorrhage, and prolonged febrile seizure.^[4] The age of presentation of this

condition depends on the time of insult, and characteristic changes may be seen only in adolescence or adulthood.^[5] It is mainly due to several ischemic episodes resulting from variable causes, reducing brain-derived neurotrophic factors production, which finally ends in cerebral atrophy.

Congenital form	Acquired form
Cerebral damage occurs during intrauterine life	During the perinatal period
Symptoms appear at birth or shortly after birth	Symptoms appear in childhood or rarely in adults
Causes include birth trauma, neonatal infections, febrile seizures or vascular anomalies	Ischemia or hemorrhage or infection
Vascular insult during embryogenesis when the formation of gyri and sulci are incomplete. Hence no prominent sulci. Encephalomalacia, gliosis, and loss of gray and white matter substance seen.	Vascular insult after sulcation is complete. Prominent sulcal spaces along with compensatory skull changes are present.

To differentiate the congenital form from an acquired type of DDMS, a thorough clinical history from the parents and features of CT or MRI are two keys to unlocking the diagnosis.^[6] In a patient with cerebral Hemi-atrophy, Rasmussen encephalitis, Sturge-Weber syndrome, and Silver-Russell syndrome are common differential diagnoses.^[3] These three can be differentiated from each other by clinical examination and cross-sectional neuroimaging. Specific imaging findings of cerebral hemiatrophy include unilateral brain volume loss, ventriculomegaly, and compensatory bone hypertrophy.^[7]

Management consists of control of seizures with appropriate anticonvulsants, as most patients with this disorder present with refractory seizures. Additionally, domiciliary physiotherapy and occupational and speech therapies have a crucial role. Hemispherectomy is indicated in patients with hemiplegia and intractable disabling seizures and is successful in 85% of the cases.^[8] Sometimes multiple anticonvulsants are to be used.

Along with drugs, physiotherapy, occupational and speech therapies play a significant role in the long-term management of the child.^[8] The prognosis is better if hemiparesis occurs after two years without prolonged or recurrent seizures.^[9] Children with intractable disabling seizures and hemiplegia are best treated with hemispherectomy, which has an 85% success rate.

CONCLUSION:

Refractory seizures remain the usual concern for DDMS cases presenting in early childhood, as in our first case. Hemispherectomy is the treatment of choice in such patients.

If the presentation is late, as in our second case, the patient can be kept on antiepileptic medications and supportive therapies like physiotherapy and occupational and speech therapies.

CONSENT TO PARTICIPATE: Patient representatives have been explained about their medical condition as the patients are mentally unstable and permission has been taken from the patient attendants in order to publish the article and assured that their identity will not be revealed.

ETHICAL CONSENT: IRB Approval is not obtained as it is a case series and the patients are not a part of the clinical trial.

CONSENT FOR PUBLICATION: Written and signed consent form is collected from the patient's representatives after a proper explanation.

FUNDING: No funding is provided for the study.

DECLARATIONS: Not applicable.

CONFLICT OF INTERESTS: The authors declare that they have no conflict of interest.

ACKNOWLEDGMENT: Not applicable.

REFERENCES:

- 1) Naveen J, Nongthombam Roshan Singh, Rimiki Challam, and W. Jatishwor Singh. "Dyke-Davidoff-Masson Syndrome: A Case Report | International Journal of Research in Health Sciences." *Dyke-Davidoff-Masson Syndrome: A Case Report | International Journal of Research in Health Sciences*, 1 Jan. 2015, ijrhrs.org/article/2015/3/1-12.
- 2) Acharya S, Andale A, Shukla S, et al. (September 06, 2022) Dyke-Davidoff-Masson Syndrome as a Predecessor of Recurrent Seizures in an Adult Male: A Report of a Rare Case. *Cureus* 14(9): e28838. doi:10.7759/cureus.28838
- 3) Kumar, T. Seetam, et al. "Dyke-Davidoff-Masson Syndrome: A Delayed Diagnosis of an Acquired Variant." *Dyke-Davidoff-Masson Syndrome: A Delayed Diagnosis of an Acquired Variant | Journal of Medical Research and Innovation*, 3 July 2018, jmrionline.com/jmri/article/view/121.
- 4) Shyama Choudhary, et al. "Indian Journal of Neurosciences." Acute Hemiplegia of Childhood, Cerebral Hypoplasia and Homolateral Hypertrophy of the Skull and Sinuses: Case Report and Review, Apr. 2016, ijnonline.org/article-download/full-text/2319.
- 5) Güner Menekşe, et al. "BALKAN MEDICAL JOURNAL." Dyke-Davidoff-Masson Syndrome Associated With Epidermoid Tumour and Arachnoid Cyst: A Case Report, Sept. 2013, pdfs.semanticscholar.org/d58b/522c4e5296d00b33df77c6f402a5d5f929c4.pdf.
- 6) Younas, Amna, et al. "Dyke-Davidoff-Masson Syndrome: A Case Report and Review of Literature." *Cureus | Dyke-Davidoff-Masson Syndrome: A Case Report and Review of Literature*, 5 Dec. 2020, cureus.com/articles/46130-dyke-davidoff-masson-syndrome-a-case-report-and-review-of-literature.
- 7) Duncan, M. A., et al. "Dyke-Davidoff-Masson Syndrome: A Case Study | Medicina Universitaria." *Dyke-Davidoff-Masson Syndrome: A Case Study | Medicina Universitaria*, www.elsevier.es/en-revista-medicina-universitaria-304-articulo-dyke-davidoff-masson-syndrome-a-case-study-X1665579614365482. Accessed 3 Nov. 2022.
- 8) Thakkar, Pareshkumar A., and Reema Haresh Dave. "Dyke-Davidoff-Masson Syndrome: A Rare Cause of Cerebral Hemiatrophy in Children Thakkar PA, Dave RH - J Pediatr Neurosci." *Dyke-Davidoff-Masson Syndrome: A Rare Cause of Cerebral Hemiatrophy in Children Thakkar PA, Dave RH - J Pediatr Neurosci*, 1 July 2016, www.pediatricneurosciences.com/article.asp?issn=1817-1745;year=2016;volume=11;issue=3;spage=252;epage=254;aulast=Thakkar.
- 9) Roy, Ujjawal, et al. "Adult Presentation of Dyke-Davidoff-Masson Syndrome: A Case Report." *Adult Presentation of Dyke-Davidoff-Masson Syndrome: A Case Report - FullText - Case Reports in Neurology* 2016, Vol. 8, No. 1 - Karger Publishers, 16 Jan. 2016, www.karger.com/Article/FullText/443521.

