



## An outline of Potter Syndrome

Mr. Justin V Sebastian<sup>1</sup>, Dr. Neenumol K Jose<sup>2</sup>, Dr. Shanti Joy<sup>3</sup>, Ms. Towar Shilshi Lamkang<sup>4</sup>, Ms. Penina Langhu<sup>5</sup>

1. Associate Professor, Jagannath Gupta Institute of Nursing Sciences, India, Kolkata-700137
2. Associate Professor, Jagannath Gupta Institute of Nursing Sciences, India, Kolkata-700137
3. Principal, Bodhini Devi Nursing Institute, India, Jagdalpur-494001
4. Ph.D Scholar, IES University, India, Bhopal-462044
5. Ph.D Scholar, IES University, India, Bhopal-462044

### Abstract

A group of abnormalities known as Potter syndrome and Potter phenotype are connected to an unborn child's lack of amniotic fluid and renal failure. Oligohydramnios, or having insufficient amniotic fluid during pregnancy, is different from anhydramnios, which has no amniotic fluid. A developing foetus is supported, padded, and safeguarded by amniotic fluid. It is possible for the foetus to develop physical characteristics like unusual facial traits or skeletal defects when there is insufficient amniotic fluid. The lungs are also underdeveloped (pulmonary hypoplasia) when oligo-anhydramnios is prevalent early in pregnancy, which can cause serious breathing problems. This illness is typically brought on by the loss of both kidneys (bilateral renal agenesis). This is referred to as the "classic Potter syndrome" at times. Polycystic kidney disease, dysplastic or hypoplastic kidneys, and obstructive uropathy, which prevents urine from leaving the bladder and accumulates in the kidneys, can also lead to Potter syndrome. There could occasionally be amniotic fluid leaks later in the pregnancy, but this won't cause Potter syndrome. Due mostly to pulmonary hypoplasia, Potter syndrome is an extremely dangerous disorder that frequently results in infant death at or soon after birth.

**Index Terms:** Potter syndrome; oligohydramnios; anhydramnios; uropathy

### Introduction

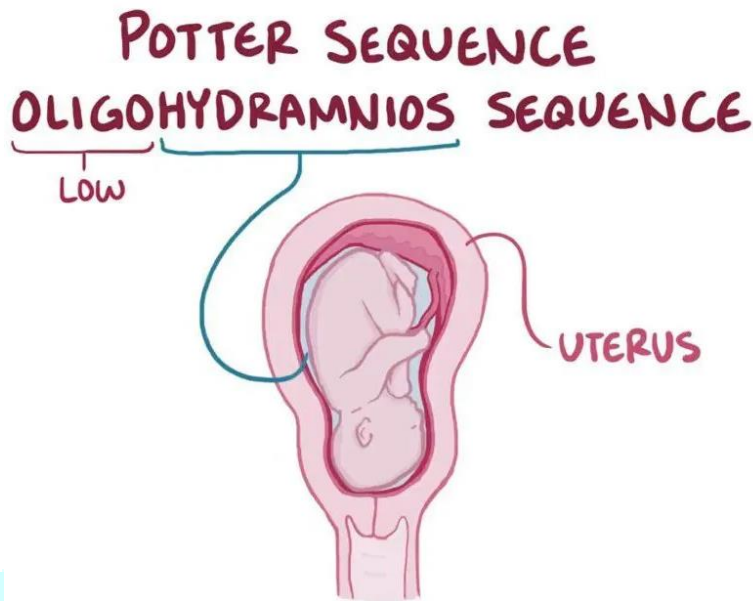
A rare disorder called Potter syndrome, commonly referred to as the Potter sequence, alters how a foetus grows inside the uterus. The kidneys and other internal organs of a newborn are affected by Potter syndrome, an uncommon illness. The symptoms of this disorder are brought on by a lack of amniotic fluid in the uterus, though there are other possible causes as well. The baby's life is in danger due to this ailment, and many newborns have a short lifespan. The disorder is fatal if the baby's body lacks kidneys at the time of diagnosis. Even though children with minor symptoms or low amniotic fluid (oligohydramnios tetrad) may survive, they run the risk of growing up with chronic lung and kidney issues.

### History

In Chicago, Edith Louise Potter, who lived from 1901 to 1993, taught pathology. She received her certification in Minnesota in 1925, but from 1956 until her retirement in 1967, she worked at the Chicago lying-in hospital. In a series of 5,000 prenatal and neonatal autopsies, she described a group of 17 male and 3 female neonates with characteristics that have come to be known as Potter's syndrome. Prior to this study, the illness was believed to be extremely unusual, despite a few isolated reports of infants with the condition, some of which date as far back as the 17th century. She focused on total renal agenesis, but the term has since come to refer to any disorder in which the kidneys do not fully mature. She then cited 50 other examples that she had seen firsthand. She contributed to the classification of polycystic kidney disease as well.

## Definition

Potter's syndrome describes the typical physical appearance caused by pressure in utero due to oligohydramnios, classically due to bilateral renal agenesis (BRA) but it can occur with other conditions, including infantile polycystic kidney disease, renal hypoplasia and obstructive uropathy.



## Incidence

- According to estimates, unilateral renal agenesis (URA), which affects roughly 1 in 1,000 newborns, is more common than bilateral renal agenesis, which is thought to occur in 1 in 5,000 births.
- Mostly male babies exhibit it.

## Types of Potter syndrome

- **Classic Potter's syndrome - due to BRA.** BRA typically occurs alone, although it can also be a component of "VATER" or branchio-oto-renal syndrome. A non-random collection of birth abnormalities known as VATER syndrome has no recognised aetiology:
  - Vertebral and vascular anomalies.
  - Anal atresia.
  - Tracheo-oesophageal fistula.
  - (O)Esophageal atresia.
  - Renal anomalies.
  - L is often added at the end because of associated limb abnormalities (radial dysplasia).
- Type I- polycystic kidney disease is caused by an autosomal recessive gene.
- Type II-typically brought on by inherited renal adysplasia or renal agenesis. Extreme phenotypic variation is known as BRA.
- Type III- Polycystic kidney disease caused by autosomal dominant genetics.
- Type IV- hydronephrosis or kidney cysts as a result of a prolonged obstruction of the ureter or kidneys.

## Causes

Potter syndrome may be brought on by a number of things, such as:

- Underdeveloped or absent kidneys.
- Renal polycystic disease
- Pruned-belly disease (Eagle-Barrett syndrome).
- Obstructions in the urinary system.
- Amniotic fluid leakage brought on by torn membranes
- Untreated medical problems, such as Type 1 diabetes, in the expectant parent.

## Symptoms

Each newborn is affected differently by the symptoms of Potter syndrome, which range in severity. The length of pregnancy may be impacted by symptoms, which could result in a premature birth for child.

**Mnemonic**

- P:** pulmonary hypoplasia
- O:** oligohydramnios
- T:** twisted skin (wrinkly skin)
- T:** twisted face (Potter facies: low set ears, retrognathia, hypertelorism)
- E:** extremity deformities (limb deformities: club hands and feet, joint contractures)
- R:** renal agenesis (bilateral); restricted growth (IUGR)

**Facial and physical characteristics**

Parts of the foetus may develop differently as a result of pressure from the absence of amniotic fluid. This results in distinctive facial traits known as "Potter facies," such as:

- Front-facing chin that doesn't grow (recessed chin).
- A crease below the bottom lip.
- Eyes widely apart in the distance.
- The bridge is flat.
- Ears that are low-set and have little cartilage.
- Creases in the skin around the eyes.

The pressure can also affect the growth of other parts of the fetus including:

- Slender legs and arms.
- Joints that have contractures or have trouble fully stretching.
- Small for gestational age.

**Diagnosis**

A comprehensive evaluation of the patient's medical history and a physical examination of both the pregnant woman and the foetus are the first steps in the diagnosis of Potter syndrome. Abdominal or transvaginal ultrasound imaging is required to find the syndrome during the evaluation. An ultrasound uses sound waves to create an image of the developing foetus and allows the doctor to see specific organs like the kidneys and how much amniotic fluid is present.

Additional imaging, such as magnetic resonance imaging (MRI), may also be useful in diagnosing renal abnormalities if ultrasound results are ambiguous. Amnioinfusion, the injection of extra fluid inside the amniotic cavity, may be necessary in situations with insufficient amniotic fluid in order to improve vision. Amniocentesis, in which amniotic fluid is removed from the uterus for examination, could provide important information for the diagnosis if other chromosomal abnormalities are detected. However, if the fetus's amniotic fluid level is already low, this treatment could be particularly challenging and hazardous.

Different signs may help diagnose Potter syndrome if it is not found before delivery. The physical characteristics mentioned above and very little urine production for a newborn are the main symptoms of Potter syndrome. Blood tests may also be used by medical professionals to detect electrolyte abnormalities such as excessive blood potassium and sodium concentrations (hyperkalemia and hypernatremia, respectively), low calcium levels (hypocalcemia), and metabolic acidosis brought on by renal failure. To test renal function, the infant's serum creatinine levels may also be measured. A newborn's underdeveloped lungs on an X-ray may also be a sign of Potter syndrome.

**Treatment**

Due to the bilateral loss of the kidneys, which is incompatible with life, there is no cure for Potter syndrome. Efforts should be made to guarantee that bereavement counselling and coping assistance are provided to the entire family. Counseling on genetic matters is advised. Additionally important is the need for family-wide psychosocial support.

Potter syndrome-affected newborns typically require oxygen support for breathing (mechanical ventilation). Additionally, resuscitation may be required. Parents, doctors, and the rest of the medical staff are closely consulted before deciding whether to perform CPR.

Dialysis, an extensive and challenging therapy for infants, may be required in certain newborns with partially functional kidneys and adequate lung function.

**Prognosis**

Rarely does a baby with Potter syndrome survive. The underlying reason has a significant impact on the survival rate. Classic Potter syndrome typically results in death. The other forms of Potter syndrome frequently result in birth-related or postpartum death. The majority of infants who do survive suffer from severe long-term effects such as respiratory distress and chronic renal failure.

**Reference**

1. Shastry SM, Kolte SS, Sanagapati PR; Potter's Sequence. J Clin Neonatol. 2012 Jul1(3):157-9. doi: 10.4103/2249-4847.101705.
2. Garne E, Loane M, Dolk H, et al; Prenatal diagnosis of severe structural congenital malformations in Europe. Ultrasound Obstet Gynecol. 2005 Jan25(1):6-11.
3. Dunn PM; Dr Edith Potter (1901 1993) of Chicago: pioneer in perinatal pathology. Arch Dis Child Fetal Neonatal Ed. 2007 Sep92(5):F419-20.
4. Sinha S, Miall L, Jardine L, et al. Eds. Essential Neonatal Medicine. 6th ed. Wiley-Blackwell. John Wiley & Sons. Hoboken, NJ; 2018:204.
5. Gupta S, Araya CE. Potter syndrome. Emedicine Journal, Jan 21, 2015. Available at: <https://emedicine.medscape.com/article/983477-overview>.
6. Genetic and Rare Diseases Information Center. Potter Sequence. November 22, 2017. Available at: <https://rarediseases.info.nih.gov/diseases/4462/potter-sequence>.
7. Mayo Clinic Staff. (2020, November 12). Amniocentesis. In Mayo Clinic: Patient care & health information. Retrieved May 5, 2021, from <https://www.mayoclinic.org/tests-procedures/amniocentesis/about/pac-20392914>.
8. National Organization for Rare Disorders (NORD), Kaskel, F., & Schreuder, M.. (2019). Potter syndrome. In NORD: Rare Disease Database. Retrieved January 24, 2021, from <https://rarediseases.org/rare-diseases/potter-syndrome/>
9. Dias T, Sairam S, Kumarasiri S; Ultrasound diagnosis of fetal renal abnormalities. Best Pract Res Clin Obstet Gynaecol. 2014 Apr28(3):403-15. doi: 10.1016/j.bpobgyn.2014.01.009. Epub 2014 Jan 29.
10. Shastry, S., Kolte, S., & Sanagapati, P. (2012). Potter's [sic] sequence. Journal of Clinical Neonatology, 1(3): 157-159. DOI: 10.4103/2249-4847.101705

