



Bilateral Retrobulbar Optic Neuropathy Revealing Devic Neuromyelitis Optica

Auteur : Dr Hjira Fatima Ezahra,

Co- Auteurs : Dr Hnich Hajar, Dr Er-radi Afaf, Dr Skalli amine, Dr Tazi Habiba, Pr Serghini louai, Pr Abdallah El Hassan, Pr Berraho Amina

Hôpital des spécialités de Rabat

Mots clés : Bilateral, retrobulbar, optic neuropathy, Devic Neuromyelitis optica

Abstract :

We report the observation of a 46-year-old man admitted to the emergency room for a sudden bilateral decrease in visual acuity limited to light perception with an ophthalmological examination and in particular of the normal fundus. Visual evoked potentials showed a lengthening of latencies, consistent with bilateral retrobulbar optic neuritis. Magnetic resonance imaging (MRI) revealed spinal cord and periventricular signal abnormalities in favor of Devic's neuromyelitis optica. The patient received a bolus of methylprednisolone for 5 days, followed by immunosuppressive treatment: antiCD20. The evolution was favorable with correction of visual acuity in both eyes

Introduction :

Devic's neuromyelitis optica is a rare clinical syndrome associating unilateral or bilateral optic neuritis with transverse myelitis. Clinically close to multiple sclerosis, with nevertheless a faster and more severe evolution, it constitutes a distinct anatomo-clinical entity. Seropositivity for anti-NMOs and longitudinally extensive spinal cord lesions are very characteristic of Devic's disease. The visual and neurological prognosis of the disease appears more pejorative, justifying early and very aggressive therapeutic options.

A case report :

This is a 46-year-old patient, farmer by profession, father of 3 children, chronic cannabis smoker, with no other particular personal or family history, apart from recent anti-covid 19 vaccination.

He consulted urgently for a sudden and bilateral decrease in visual acuity, limited to light perception in both eyes, with an abolished photomotor reflex, an ophthalmological examination and normal fundus.

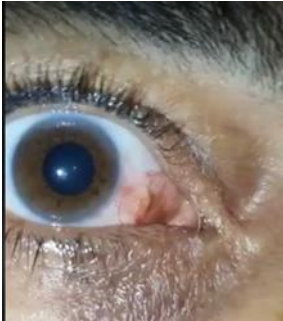

Figure 1: Abolished RPM with areflexic semi-mydriasis

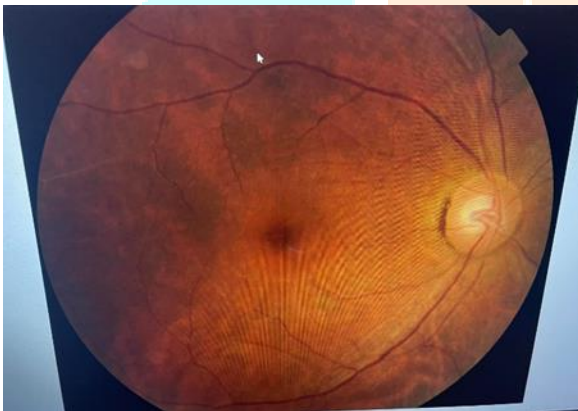

Figure 2: Retinography of the right eye

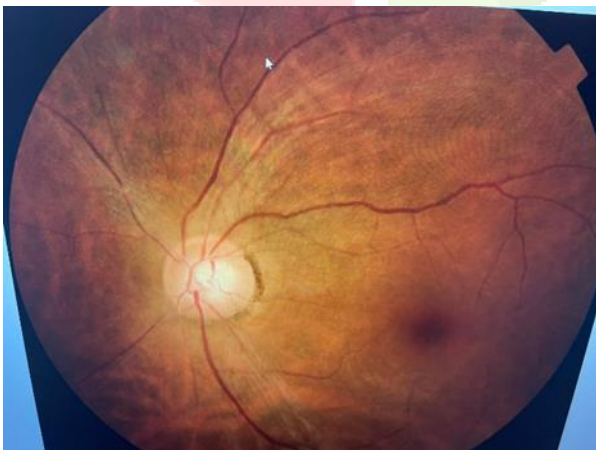


Figure 3: Retinography of the left eye

In addition, the objective neurological examination of myoclonus and depressed osteo-tendinous reflexes.

The collapsed visual acuity did not allow the visual field or the color test to be carried out, but the other ophthalmological explorations, in particular the optical coherence tomography and the ocular angiography, returned to normal.

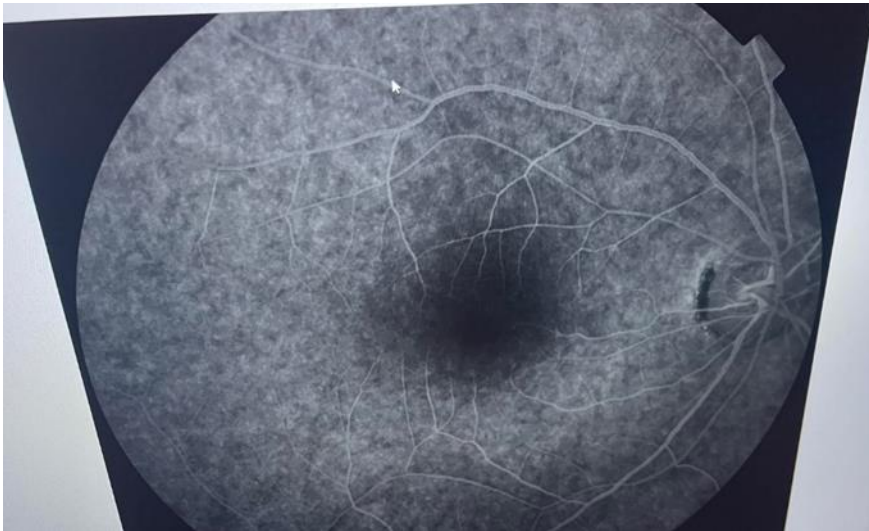


Figure 4: Late angiographic sequence of the right eye

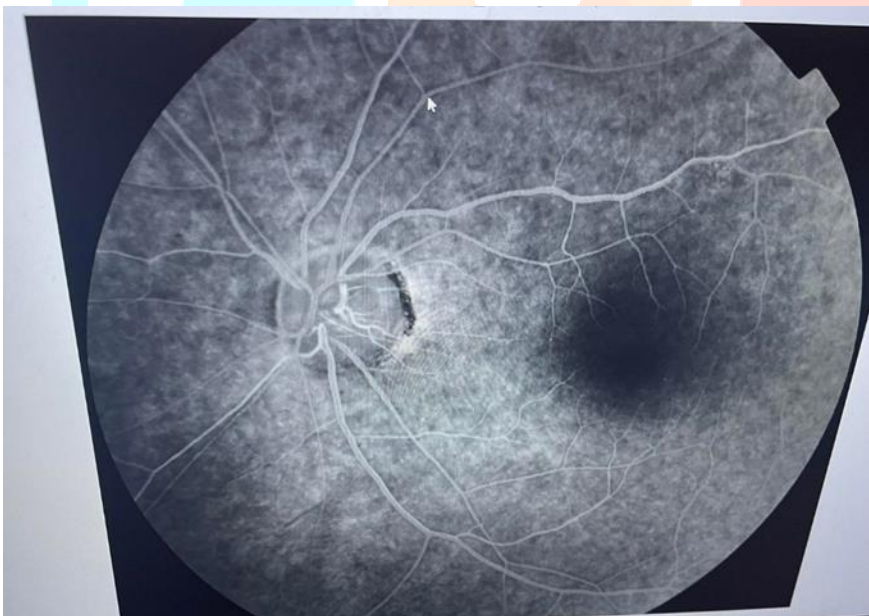

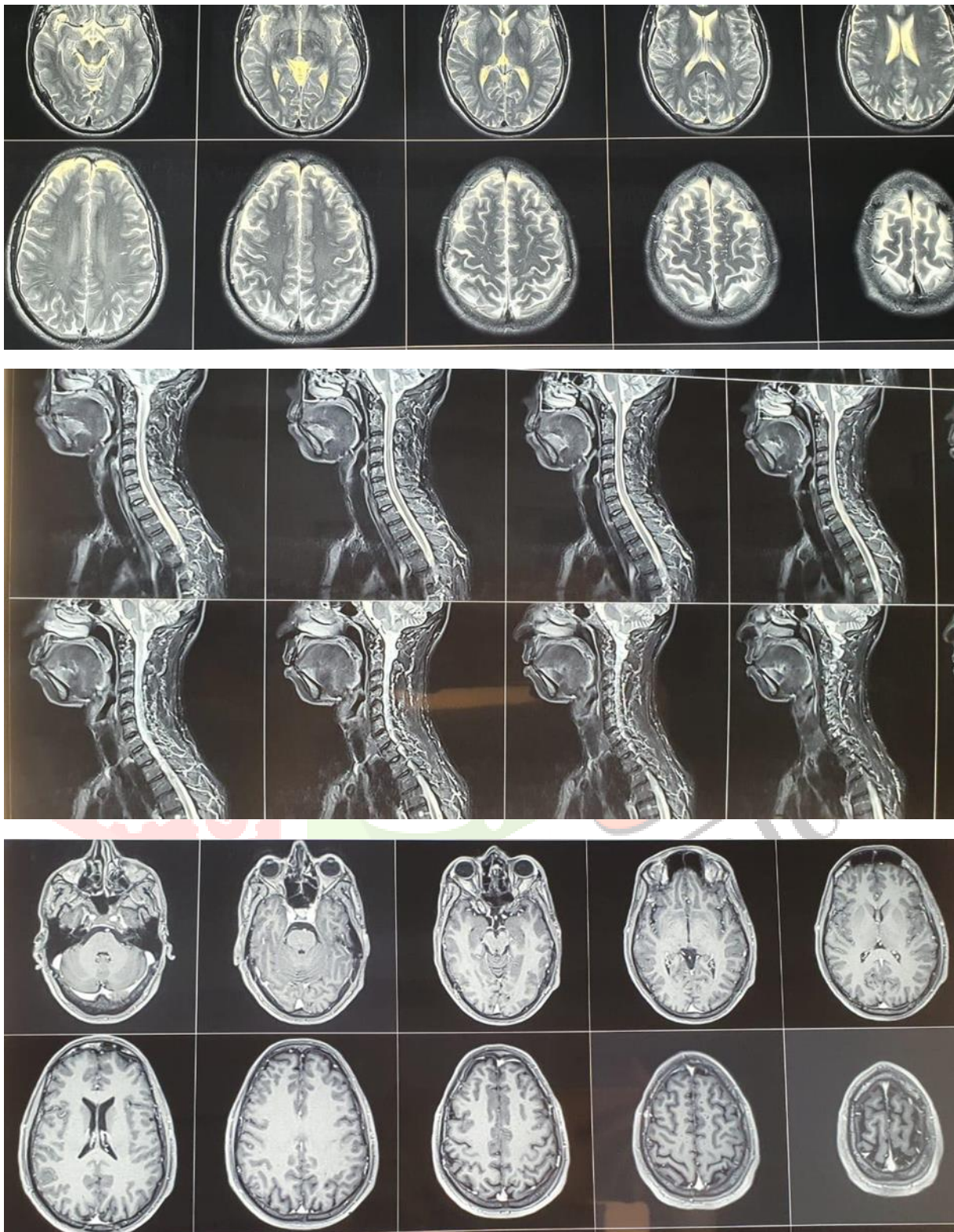
Figure 5: Late angiographic sequence of the left eye

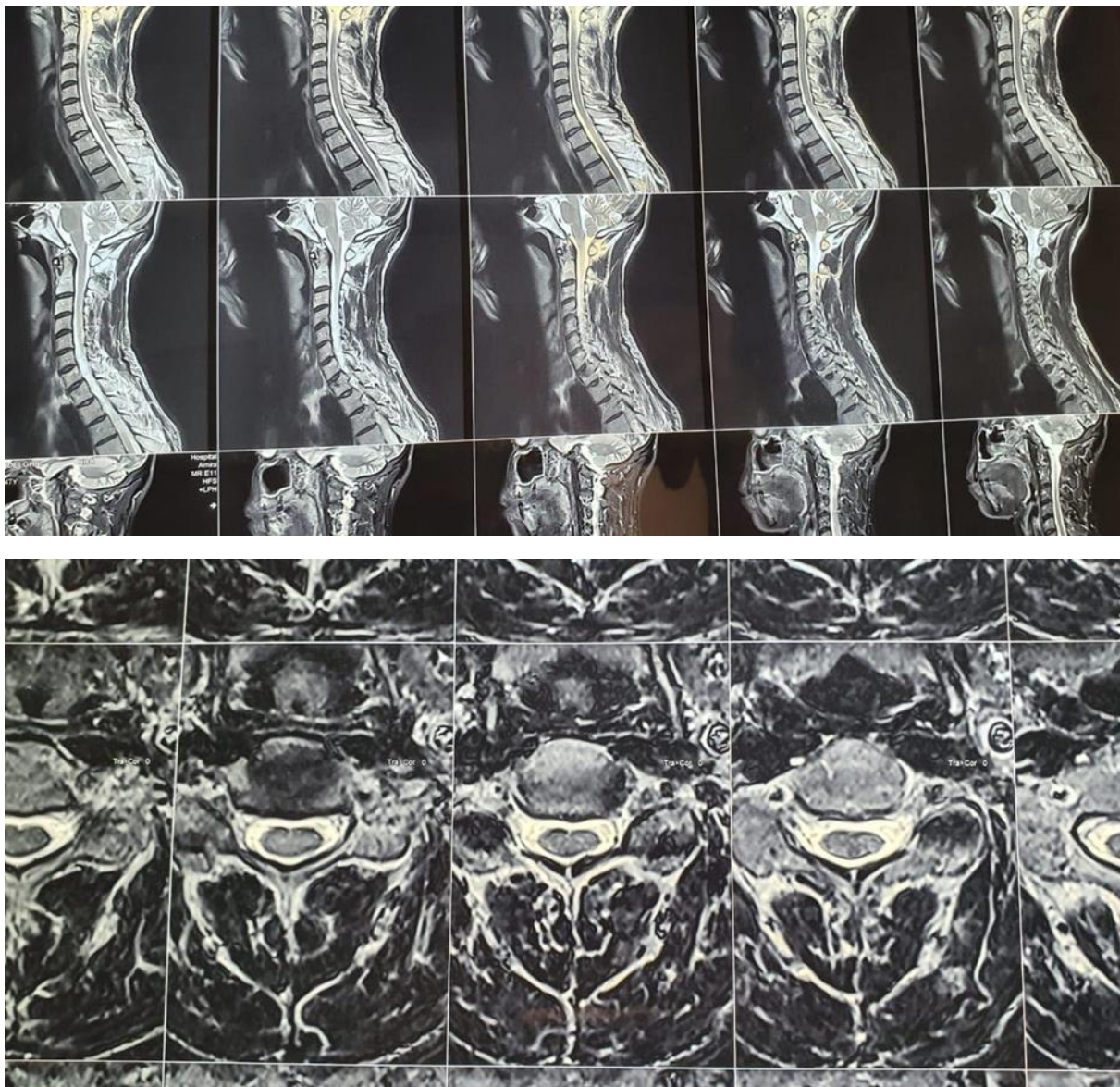
However, physiological exploration reveals elongated visual evoked potentials.

And the diagnosis of bilateral retrobulbar optic neuritis was retained.

Inflammatory NORB was mentioned first, the patient benefited from a complete inflammatory and infectious assessment, which returned to normal, in particular the physiological and viral assessment (HIV, Hepatitis B and C, CMV serologies, etc.), syphilitic serology, etc. all returned negative

Cerebro-medullary MRI was performed which objectified periventricular and medullary demyelinating lesions.





MRI : inflammatory demyelinating lesions in the brain and cervical spinal cord evoking an NMO spectrum

The patient also benefited from a lumbar puncture but the study of the cerebrospinal fluid did not objectify an oligoclonal peak with a normal cytochemical and microbiological analysis.

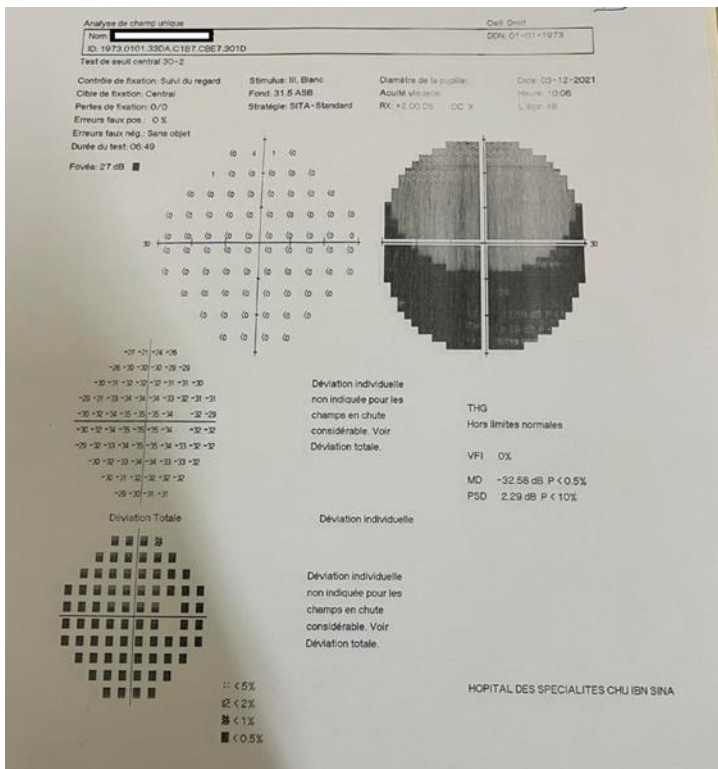
And an immunological assessment revealing the presence of anti-NMO antibodies

The diagnosis of Devic's disease is then retained.

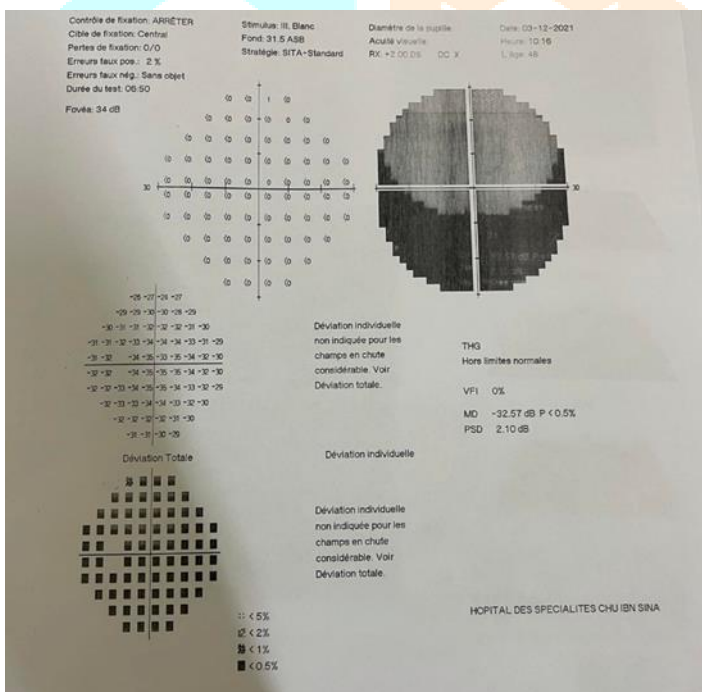
The patient received a bolus of methylprednisolone (Solumédrol®) at a dose of 1 g/d per day for 5 days, and from the 6th day, we administered an immunosuppressant: antiCD20 (rituximab®) at a dose of 1g passed over 12 hours then a 2nd cure on D15 then every 6 months.

The evolution was spectacular for the left eye with correction of visual acuity which went from light perception to 10/10 but less good for the right eye which rose to only 1/10

Faced with the improvement in visual acuity, a visual field was performed which objectified a lower altitudinal deficit at the level of both eyes



Visual field right eye



visual field Left eye

A rather exhaustive clinical and paraclinical exploration, in search of other autoimmune diseases, was negative.

Currently, the patient is stabilized on immunosuppressant (rituximab).



Discussion :

Devic's neuromyelitis optica (NMO) is an inflammatory demyelinating pathology of the central nervous system characterized by the association of episodes of extensive myelitis and optic neuritis. It was described for the first time by Eugène Devic in the 19th century and considered as a pathology in its own right. Then it was classified as a subtype of multiple sclerosis (MS). But the discovery of anti-NMO antibodies (immunoglobulin G) with aquaporin 4 (AQP4) as antigenic target has made it an inflammatory pathology of the central nervous system different from MS. Anti-NMO antibodies have a diagnostic sensitivity and specificity of 54–76% and 85–99%, respectively. In addition, analysis of central nervous system (CNS) lesions suggests a humoral-mediated immune pathophysiological mechanism due to complement activation, eosinophil infiltration and vascular fibrosis.

Orbito-cerebro-medullary MRI shows extensive hypersignal of the optic nerve associated with extensive hypersignal of the spinal cord.

CSF analysis can find pleocytosis and hyperproteinorachia, without oligoclonal bands.

Devic's neuromyelitis optica is a therapeutic emergency. The earlier and more intense the initial management of the push, the greater the chance of recovery. This emergency management is based on high-dose intravenous corticosteroid therapy (1g/day for 5 days).

The second concern is relapse prevention. Azathioprine (2.5–3mg/kg/day), combined or not with oral corticosteroid therapy may be proposed. For patients who do not respond to the latter, mitoxantrone and rituximab can promote clinical remission.

Conclusion :

A rare demyelinating condition with a poor prognosis, Devic's disease has long been considered a form of multiple sclerosis, a source of diagnostic delay. The discovery of Anti NMO antibodies (IgG) has increased the specificity of the diagnostic criteria for Devic's disease and has made it possible to establish an early diagnosis and initiate early treatment.

References :

1. Neuromyérite optique/syndrome de Devic: avancées et perspectives
Patrice H. Lalive Michel Chofflon Perrin Luc
Revue médicale suisse 11 Avril 2007
2. Neuromyérite optique de Devic (NMO) (à propos d'un cas)
Soufiane Afkiri, Rhizlen Abdil, Siham Charibal, Asmae Maadanl, Rachid Sekhsoukh1, 2,
1Service d'Ophthalmologie, CHU Mohamed VI d'Oujda, Faculté de Médecine et de Pharmacie d'Oujda, Université Mohammed Premier, Oujda, Maroc,
2Laboratoire d'Epidémiologie de Recherche Clinique et de Santé Publique, Oujda, Maroc

3. NEUROMYELITE OPTIQUE DE DEVIC

CHTAOU Naima 1, SOUIRTI Zouhair 1, BELFKIH Rachid 1, CHARAI Nadia 1, TRAIBI Imane 1, MESSOUAK Oufae 1, BELAHSEN Mohamed Faouzi 1

1Service de Neurologie, CHU Hassan II, Fès, Maroc

AFRICAN JOURNAL OF NEUROLOGICAL SCIENCES

4. A role for humoral mechanisms in the pathogenesis of Devic's neuromyelitis optica

Claudia F. Lucchinetti, Raul N. Mandler, Dorian McGavern, Wolfgang Bruck, Gerald Gleich, Richard M. Ransohoff, Corinna Trebst, Brian Weinshenker, Dean Wingerchuk, Joseph E. Parisi

Brain, Volume 125, Issue 7, July 2002, Pages 1450–1461,

5. Neuromyéélite optique de Devic, troubles cognitifs et imagerie cérébrale par résonance magnétique - 23/02/11

Doi : 10.1016/S0035-3787(11)70006-6

F. Blanc a, b, c, V. Noblet d, B. Jung a, c, F. Rousseau d, F. Renard b, d, B. Bourre a, b, N. Longato a, c, N. Cremel a, c, L. Di Bitonto a, c, C. Kleitz a, c, N. Collongues a, b, J. Foucher e, S. Kremer b, f, J.-P. Armspach b, J. de Seze a, b

a Service de Neuropsychologie, département de Neurologie, Hôpitaux Universitaires de Strasbourg, France

b LINC (Laboratoire d'imagerie et de Neurosciences cognitives) Université de Strasbourg et CNRS, Strasbourg, France

c CMRR, département de Neurologie, Hôpitaux Universitaires de Strasbourg, France

d LSIIT (Image Science, Computer Science and Remote Sensing Laboratory), UMR 7005, Université de Strasbourg et CNRS, Strasbourg, France

e INSERM U666, Hôpitaux Universitaires de Strasbourg, France

f Service de Neuroradiologie, Hôpitaux Universitaires de Strasbourg, France

6. NMO-IgG and Devic's neuromyelitis optica: a French experience

Romain Marignier, Jérôme De Sèze, Sandra Vukusic,

First Published January 21, 2008

<https://doi.org/10.1177/1352458507084595>