



A Compendious Review On Rare Congenital Syndrome MERMAID: Current Findings And Understanding

¹Rushi Darji, ²Diya Patel, ³Deep P. Joshi, Ravi R. Shah

Shree swaminarayan college of pharmacy, kalol, 382721, Gujarat, India

Corresponding author:

Rushi darji*

ORCID IDs:

Mr. Rushi Darji: <https://orcid.org/0000-0002-3852-7161>

Mr. Deep Joshi: <https://orcid.org/0000-0001-9150-6581>

Mr. Ravi Shah: <https://orcid.org/0000-0003-4556-7652>

Abstract: Sirenomelia is very rare congenital deformity syndrome, it's alternatively known as "mermaid syndrome" and "Caudal regression syndrome" (CRS). In this syndrome the legs fused together and it's appear like a tail such as mermaid. The babies born with mermaid syndrome are born die or shortly die after birth. In mermaid syndrome combined lumbosacral with anorectal and urogenital malformations are seen mostly. The molecular mechanism of mermaid syndrome is not yet clear, but some animal model helps to understand it's mechanism. There is a animal model mice with lacking of enzyme cyp26a1 (retinoic acid-metabolizing enzyme) which degrades the retinoic acid (RA) and mice that that developed within abated bone morphogenetic protein (BMP) are seen with sirenomelia. So this mutant animal model suggest that in human sirenomelia occur due to the over concentration of retinoic acid and shortage of bone morphogenetic protein in caudal body. So this review gathers the mechanism, diagnosis and treatment information on sirenomelia with the necessary side information to understand and predetermine that how deviations and irregularity from normal development of the caudal part of embryo may lead to this multisystemic malformation.

Keywords: Sirenomelia, Caudal regression syndrome, mermaid, Retinoic acid

1.INTRODUCTION

The mermaid syndrome was firstly described by Rocheus in 1542 and palfyn in 1553. With a numbers of genitourinary and anorectal defects this anomaly is associated. Maternal having Diabetes mellitus has a strongly associate with relative risk 1;200-250 and 22%. A possible etiological factors has been proposed are intake of haloperidol, and exposure of some teratogen such as cadmium, lead, vitamin A, nutritional deficit, vascular hypoperfusion.[1]

In some cases of caudal dysgenesis syndrome merging of lower limbs led to the use of term mermaid syndrome, this is the concept based on the Greek and Roman mythological monsters. Depend on affected organ this complex affliction presents itself in variable forms such as symphodia is least grave and most variable on other hand the visceral malformations are consistent and contribute to mortality. The occurrence is 1 in 60,000 births, and the frequency is high in twinning and its 100-150 times more

common in monozygotic twins than in dizygotic twins or singletons. There is not any definitive pathogenetic mechanism has been established. By circumventing extraneous variables the genetic and experimentally induced animal models are of great help in identifying the pathogenetic mechanism. [2]

By the sacrococcygeal or lumbosacrococcygeal agenesis the caudal regression syndrome (CRS) is characterized. It also mostly seen by multiple musculoskeletal abnormalities of the pelvis and legs, furthermore other malformalities, vertebral and non-vertebral are occasionally been reported in association with the complex. During the week of 3-7 of fetal development this conditions is occur due to some factors or set of factors. In week 4 of development the formation of lower back/sacrum and corresponding nervous system completion occur. Because of abnormal gastrulation, the mesoderm migration is disturbed, causes of this disturbance severe symptoms may occur such as fusion of lower limbs, this is what also known as sirenomelia or mermaid syndrome. With respect to its etiology and pathogenesis CRS is heterogeneous disorder. It occur due to various gene mutation, its clear that environmental factors and underlying genetic predisposition are involved in CRS.[3]

Retinoids are the chemicals which structurally and functionally similar to the retinol or vitamin A, here retinoic [RA] is a key determinant of the vertebrate embryo patterning and organogenesis. For embryo development and adult body homeostasis its essential biomolecule. Retinoids involve in cellular growth, apoptosis, immune response and epithelial growth by the interaction with the nuclear receptors, retinoic acid receptor (RAR) and retinoic X receptors (RXR). Retinoids are highly oil-soluble and its able to diffuse across cell membrane. Throughout early embryo development, moajor active form of retinoids, all-trans retinoic acid (atRA), which regulates the formation of germ layer, body axis formation, neurogenesis, cardiogenesis, development of pancreas, lung and eye. For the visual function it also a critical element. For the decades extensively study going on the metabolism, regulation and functions of vitamin A because of its wide spectrum function of retinoic acid.[4]

So the this study presents the possible pathogenetic mechanism, common symptoms, diagnostic methods and treatments. Here we summarize current understanding on retinoic acid functions throughout early embryo development and its correlation or direct/indirect connection with mermaid syndrome.

1. Pathogenetic mechanism and direct /indirect connection of Retinoic acid with Mermaid Syndrome [4]

1.1 Conversion of all-trans retinal to (atRAL) to all-trans retinoic acid (atRA)

All trans retinal is transported by cellular retinal binding protein (CRBP) in the cell, and is then oxidized to all-trans retinoic acid (atRA). By various retinaldehyde dehydrogenases (RALDH) the oxidation of atRAL to atRA was mediated. There are 3 RALDHs have identified in mouse, human and xenopus within different physiological functions. Metabolism of all-trans retinoic acid nearly related to retinoid binding protein termed retinoic acid binding proteins (CRABPs), this bind to retinoic acid and prevent it from non-specific degradation, they participate in mediating retinoic acid signaling by transporting retinoic acid to the nucleus to interact with retinoic acid receptors. There are 2 CRABPs identified in which CRABPs-II allows all-trans retinoic acid (atRA) to bind to and activate retinoic acid receptors (RAR), it's a transcription factor responsible for the retinoic acid signaling. As CRABP-II is negatively regulated by all-trans retinoic acid the retinoic acid signaling is tightly regulated by negative feedback mechanism. Changing in retinoic acid signaling suppresses the production of CRABPs which responsible for down regulation of activation or retinoic acid receptors and the retinoic acid signaling. On the hand CRABP-I regulates the rate of retinoic acid metabolism by presenting retinoic acid to its degrading enzyme CYP26A1. [4][5]

1.2 Degradation of all-trans Retinoic acid (atRA)

CYP26 enzymes responsible for degradation of all-trans retinoic acid. This enzyme belongs to cytochrome P450 family. There are numbers of CYP26 family including CYP26A1, B1, C1 and D1 have been characterized and all of them possess the ability to degrade all-trans retinoic acid to the less bioactive retinoid. CYP26A1 promotes the hydroxylation of atRA into 4-hydroxy retinoic acid, 4-oxo retinoic acid and 18-hydroxy retinoic acid. Retinaldehyde dehydrogenase 2 (RALDH2) and CYP26A1 both are regulated by all-trans retinoic acid itself, metabolism of all-trans retinoic acid forms auto-regulatory loop that balance all-trans retinoic acid levels in embryos. [4]

1.3 Retinoic acid receptors

By CRABP-II alltrans-retinoic acid is carried into the nucleus and interacts with retinoic acid receptors (RARs) which itself transcription factors. Retinoic acid receptors belongs to retinoid receptor family which also include other group called retinoid X receptors (RXRs). RARs readily recognize the atRA and 9-cis retinoic acid on other hand RXRs only recognize 9 cis-retinoic acid. RAR and RXR together form heterodimer, which start the gene transcription by binding to the retinoic acid response element (RARE) in promoter region of the target gene. The retinoic acid receptor family consists of RAR $\alpha/\beta/\gamma$ three members

three members which bind to all-trans retinoic acid(atRA). Double knockout of of 2 RAR γ sub type causes growth deficiency, cartilage dysmorphogenesis and vertebrate malformation. Similarly there are 3 type of or subtype of RXRs RXR $\alpha/\beta/\gamma$. [4]

1.4 Different expression and gene regulation of retinoic acid metabolic enzymes

During early embryo development retinoic acid enzymes show distinct differential expression pattern, their expression regulated by the retinoic acid signaling. For retinoic acid biosynthesis retinoic acid signaling itself regulates expression of enzymes. In early embryonic development retinoic acid act as a morphogen. CYP26 enzyme expression can be induced by atRA treatment, when embryos treated with atRA there was a down-regulation seen of RALDH-II, and RDH10. Thus for atRA production RA signaling down-regulates the expression of the enzymes, on other hand up-regulation of enzyme can reduce all-trans retinoic acid levels in embryo. [4]

1.5 Signaling of Retinoic acid throughout early embryonic development

The retinoic acid signaling pathway take part in various developmental processes. Throughout the early embryonic development, retinoids act as key determinant morphogen across different species from invertebrate to metazoan including human. It take part in regulating various biological processes such as apoptosis and differentiation and cell fate specification. On other hand it take part in various embryonic developmental events such as axis formation, neural differentiation, hindbrain patterning, development of pancreas, heart, kidney, lung etc. so in any elevation of retinoic acid signaling this all developmental process can be affect. [4]

From above mentioned all developmental event in which retinoic acid take part the most important for our review article is importance of retinoic acid in axis formation. Abnormal development or elevation in retinoic acid or its pathway can causes a serious problems such as caudal regression syndrome which is also known as sirenomelia or mermaid syndrome.[4][5]

1.5.1 Importance of retinoic acid in axis formation

The retinoic acid participates in the formation of embryonic axis. It seen that it interact with nodal signaling to regulate dorsoventral axis formation. There was a animal model mice, with lacking of all three CYP26 genes shows secondary body axes due to expansion of the nodal expression domain. In dorsoventral axis formation CYP26 is most important for restricting the expression of posterior genes during the anteroposterior patterning. There are are two enzyme namely RALDHs and CYP26s take part in the anteroposterior patterning of the central nervous system by maintaining gradient of all-trans retinoic acid along the axis. Application of all-trans retinoic acid to mouse embryos throughout day 7 gestation caused head deformations such as exencephaly, microcephaly and anencephaly, where open exposure of embryo to all-trans retinoic acid throughout 8 day of gestation led to severe caudal regression syndrome.[4][5]

2. Data collected from the case reports

2.1Cases and common characteristics with neonate present with MERMAID syndrome

There was a mother who has a history of tobacco injection during antenatal period. So the child birth by this maternal didn't survive this lethal abnormality and died after 4 and half week.so here are some characteristics seen with this neonate such as no feet are present and the limbs are totally fused into a single limb 1 femur and 1 tibia is present.2 femur,2tibia,2fibula are present.The fusion of the limbs extends only till the ankle[1] .There was a patient who delivered a preterm baby with weight 1.1 kg with multiple congenital anomalies.This fetus died within 45 minutes. These are some characteristics seen with this neonate the bilateral hypoplastic thumb, birth defect of the lower body characterized by the apparent fusion of the legs into a single lower limb the most serve from only a single bone is present with no indication of leg or feet with absent external genitalia and umbilical cord with single umbilical artery.There are some defects that interact with the formation of notochord which results into abnormal development of caudal structure.This are some commonly seen factors or set of factors which associate with mermaid syndrome such as maternal present with diabetes mellitus, maternal injection or history of injection tobacco . Elevation level of retinoic acid and lack of cyp26a1 enzyme and exposure of heavy metal[6]. During gastrulation period normal level of Retinoic acid is changes which can be sensitive for embryo.so if there is any disturbance or reduce cyp26a1 enzyme expression lead to increase levels of retinoic acid which causes growth defects in tail area(caudal area) which result into sirenomelia or mermaid syndrome. So these are the characteristics present in individual new born baby with mermaid syndrome absence of fibular bone in the legs ,The fetal urinary bladder was minimally filled and located slightly to the left and kidney was not visualized .only a single umbilical artery was present and severe oligohydramnios was seen . sirenomelia is strongly associated

with Potter's syndrome and a diabetes mother [7]. There was a patient who has a history of using tobacco before and during pregnancy. The baby died in 30 minutes. Post partum investigation revealed the presence of diabetes mellitus [8]

2.2 Some diagnostic data from case reports

In this type of syndrome mostly diagnosis was performed after birth by using high resolution or colour Doppler sonography in antenatal period. Sirenomelia can be diagnosed as early as 13 weeks [9]. Fused lower extremities that moved at unison showed by ultrasound scan [10]. If neonate present with severe abnormalities leads to intrauterine death or immediately after birth. Therefore it's necessary to early diagnosis and therapeutic plan or maternal is necessary. Diagnosis may often be delayed until the end of the second and third trimester because it is difficult to detect abnormalities by ultrasound [11]. For the diagnosis of sirenomelia ultrasound is an optimal method. Key determinate technology which can be also useful to diagnose sirenomelia are 3D sonography and magnetic resonance (MRI). To confirm the diagnosis after postnatal x-ray and autopsy are also recommended. Diagnosis sirenomelia was between 16 and 32 weeks gestation and delivery was from 27 to 38 gestational week [12, 15]

III CONCLUSION

Sirenomelia or mermaid syndrome is very rare syndrome. By review this article and by read all individual cases we conclude that the maternal present with diabetes mellitus, use tobacco or history of use tobacco, over retinoic acid levels, or other external environmental factors directly or indirectly affects the development of the fetus. Retinoic acid is key determinant or key term in mermaid syndrome, due to its multi-functionality its elevation or lacking of enzyme CYP26A1 can be a potential reason of mermaid syndrome. So pre or early diagnosis or care by mother by nutritional/diet wise or environmental wise this syndrome can either be identified and treated or identified but untreated.

IV ACKNOWLEDGEMENT

The authors would like to thank Dr. Ravi Patel, Principal Shree Swaminarayan College of pharmacy, Kalol for his constant support to our department.

V CONFLICT OF INTEREST

The authors declare no conflict of interest.

VI REFERENCES

- [1] R. Prema¹, Sunil B², Pawan Kumar S³, Sebastian Paul⁴, Sailakshmi M.P.A⁵. 2013. SIRENOMELIA: THE MERMAID BABY - RARE CASE REPORT. *Journal of Evolution of Medical and Dental Sciences*, 2(49): 9611-9613
- [2] R. PADMANABHAN. 1998. RETINOIC ACID-INDUCED CAUDAL REGRESSION SYNDROME IN THE MOUSE FETUS. *Reproductive toxicology*, 12(2): 139-151
- [3] Kei Semba and Ken-ichi Yamamura. 2013. Etiology of Caudal Regression Syndrome. *Human Genet Embryol*, 3(2): 100-107
- [4] Richard Kin Ting Kam¹, Yi Deng², Yonglong Chen^{3*} and Hui Zhao^{1,4*}. 2011. Retinoic acid synthesis and functions in early embryonic development. *Cell & bioscience*, 2(11): 2-14
- [5] Carlos Garrido-Allepuz¹, Endika Haro¹, Domingo González-Lamuño², María Luisa Martínez-Frías³, Federica Bertocchini¹ and Maria A. Ros^{1,4,*}. 2011. A clinical and experimental overview of sirenomelia: insight into the mechanisms of congenital limb malformations. *Disease Models & Mechanisms*, 4: 289-299
- [6] Kumar A.1, Snehlata², Srivastava M.3. 2019. A rare case report of sirenomelia. *Obs Gyne Review: Journal of Obstetrics and Gynecology*, 5(5): 237-240
- [7] Meena Dharmraj, Sumitra Gaur. 2012. Sirenomelia: A Rare Case of Foetal Congenital Anomaly. *Journal of Clinical Neonatology*, 1(4): 221-223
- [8] Sunil Kumar Samal, Setu Rathod. 2015. Sirenomelia: The mermaid syndrome: Report of two cases. *Journal of Natural Science, Biology and Medicine*, 6(1): 264-266
- [9] José Morales-Roselló, Gabriela Loscalzo, Silvia Buongiorno, Vaidilé Jakaitė & Alfredo Perales-Marín. 2020. Sirenomelia, case report and review of the literature. *THE JOURNAL OF MATERNAL-FETAL & NEONATAL MEDICINE*, 1-4

- [10] Mirzapur Pegah¹, Rezakhani Leila² and Khazaei Mozafar^{3*}. 2018. Sirenomelia: Case Report and Review of the Literature. Glob J Reprod Med, 3(5): 0097-00100
- [11] Tingting Xu, MD^{a,b}, Xiaodong Wang, MD, PhD^{a,b}, Hong Luo, MD, PhD^{b,c}, Haiyan Yu, MD, PhD^{a,b,*}. 2018. Sirenomelia in twin pregnancy A case report and literature review. Medicine, 97(51): 1-5
- [12] Lucas L. Boer ^{*1}, Eva Morava², Willemijn M. Klein³, Annelieke N. Schepens-Franke¹, and Roelof Jan Oostra⁴. 2017. Review Article Sirenomelia: A Multi-systemic Polytopic Field Defect with Ongoing Controversies. Birth Defects Research, 1-14
- [13] Jenny Hoque¹, Efterpi Tingi^{2*}, Sanjay Sinha³ and Vincent Bamigboye³. 2017. An unusual case of Sirenomelia Sympus Dipus (Mermaid Syndrome). Obstetrics and Gynecology Reports, 1(1): 1-2
- [14] Charusheela Korday, Baraturam Bhaisara^{*}, Rupali Jadhav, Suraj Rathi, Ubaidulla Shaikh, Avinash Rao. 2019. Sirenomelia, the Mermaid syndrome: a case report. International Journal of Contemporary Pediatrics, 6(6): 2692-2696)
- [15] Asiyeh Shojaee¹, Firooze Ronnasian², Mahdiyeh Behnam² and Mansoor Salehi^{2,3*}. 2021. Sirenomelia: two case reports. J Med Case Reports, 15(217): 1-4

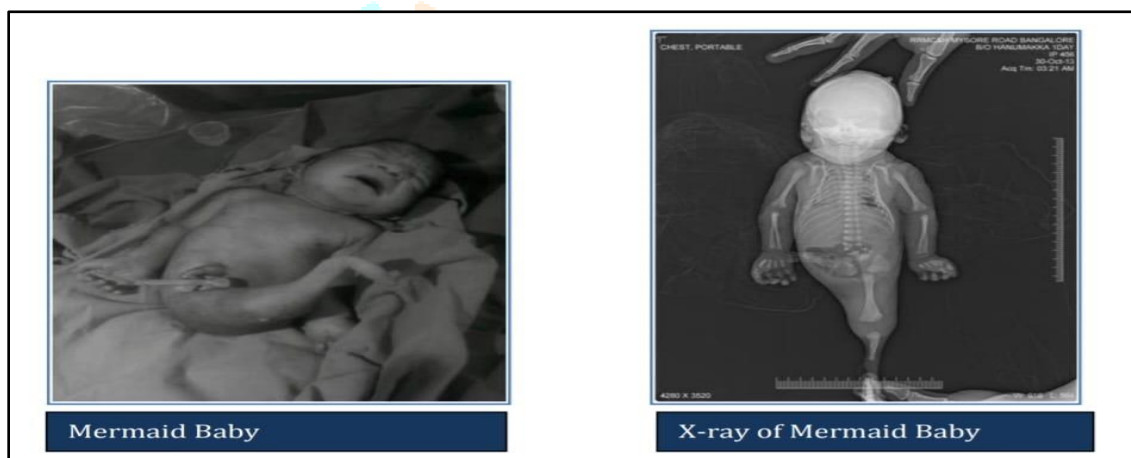

Figure: 1 Neonate present with MERMAID syndrome [1]

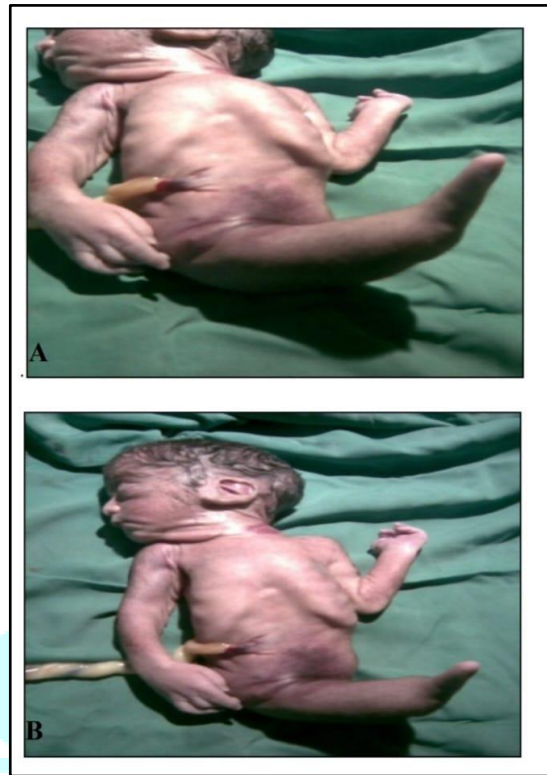


Figure:2 Neonate present with MERMAID syndrome [6]

