



# A Survey on Retinopathy Classification for Diabetic Patient using Image Processing

<sup>1</sup>Ms. Madhuri V. Kakade, <sup>2</sup>Dr. C. N. Deshmukh,

<sup>1</sup>PG Student, <sup>2</sup>Professor,

<sup>1-2</sup>Department of Electronics & Telecommunication,

<sup>1-2</sup>Prof. Ram Meghe Institute of Technology and Research, Badnera, India.

**Abstract:** Diabetic retinopathy is a retinal disease that affects diabetes patients and the major cause of blindness for age population. It is an asymptomatic disease, which involves changes to blood vessels that can cause them to bleed or leak fluid, causing distortion of vision. Therefore, the blood vessels extraction is very important to help ophthalmologists to recognize this disease at the first stage in order to prevent an eventual loss of vision. Diabetic Retinopathy (DR) is a leading disabling chronic disease and one of the main causes of blindness and visual impairment in developed countries for diabetic patients. Studies reported that 90% of the cases can be from through early detection and treatment. Eye screening through retinal images is used by physicians to detect the lesions related with this disease. Due to the increasing number of diabetic people, the amount of images to be manually analyzed is becoming unaffordable. Moreover, training new personnel for this type of image-based diagnosis is long, because it requires to acquire expertise by daily practice. This paper presents the survey of retinopathy classification for diabetic patient using various methods which include image processing and artificial intelligence or machine learning.

**Index Terms - Retinopathy, Image Processing, Diabetic Patient, Machine Learning.**

## I. INTRODUCTION

Diabetic Retinopathy (DR) is human eye disease among people with diabetics which causes damage to retina of eye and may eventually lead to complete blindness. Diabetes mellitus is a metabolic disorder characterized by a hyper-glycaemia due to malfunction in the production of insulin by the pancreas. At long term, it can cause microvascular complications that affect the retina, resulting in Diabetic Retinopathy (DR), which is the leading cause of blindness in active population. Moreover, the World Health Organization (WHO) anticipates that 347 million people were diagnosed with diabetes in the world, and it is predicted that, can be affect more than 640 million people by 2040. According to some estimations, more than 75% of diabetic patients within 15 to 20 years of diabetes diagnosis are endangered by DR. Diabetic retinopathy is an asymptomatic retinal disease and primarily a consequence of diabetes, which involves changes to blood vessels, resulting in micro aneurysms, hemorrhages, exudates, malformation and vascular tortuosity (Non-Proliferative Diabetic Retinopathy) that can subsequently cause an abnormal growth of retinal blood vessels (Proliferative Diabetic Retinopathy) that can lead to blindness in the absence of appropriate treatment. Therefore, the extraction of blood vessels is crucial to help ophthalmologists to identify this disease at the early stage in order to prevent the loss of vision. Anatomy of eye for normal retina and DR-affected retina is shown in Fig-1 and Fig-2 respectively [1] [2].

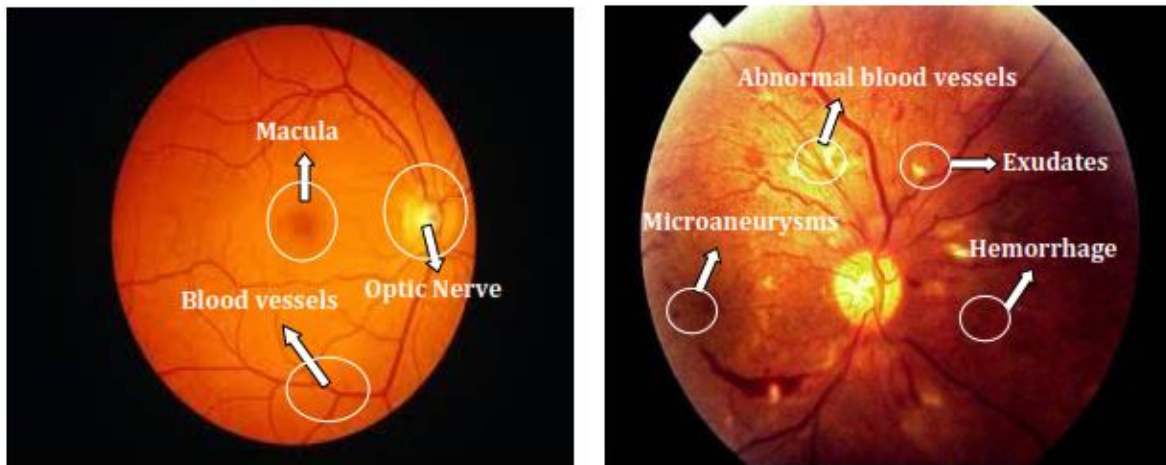


Fig-1: Normal Retina Fig-2: DR-affected Retina

Diabetes is a disease in which glucose metabolism is impaired leading to several complications. Diabetic retinopathy (DR) is one such condition which is characterized by damaged blood vessels at the back of the retina. According to the statistics provided by the International Diabetes Federation (IDF) nearly million patients suffer from diabetes globally and nearly one third have signs of DR. Physicians have categorized DR into five different stages based on the severity viz. No DR, Mild, Moderate, Severe and Proliferative DR, characterized by symptoms shown in the retinal fundus photography images or retinal fundus images in figure 3. In addition to that, the formation of abnormal blood vessels, called neovascularization is the characteristic for later stages of DR. DR can be effectively managed in the early stages, however DR detected at later stages may cause irreversible loss of vision.

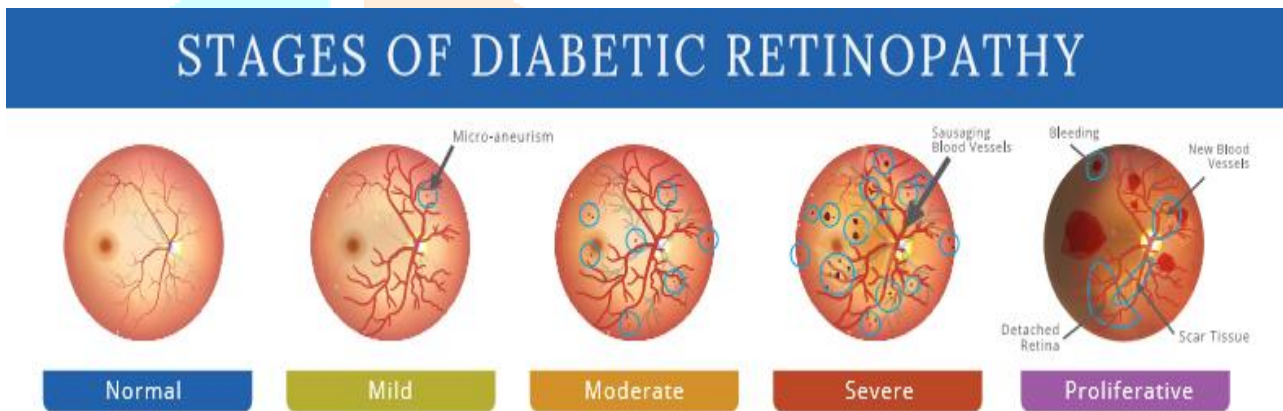


Fig3: Stages of Diabetic Retinopathy

According to the Early Treatment Diabetic Retinopathy Study (ETDRS), the Diabetic Retinopathy (DR) risk levels are listed in Table 1 and their visual representation at different stages as shown in fig3.

Table 1: Diabetic Retinopathy risk levels

DR Risk level	Lesions
No DR	o No lesions
Mild NPDR	o Presence of MA
Moderate NPDR	o Presence of MA and HM o Presence of Cotton wool spots and Exudates
Severe NPDR	Any of the symptoms, o Venous beading in 2 quadrants o Presence of MA and extensive HM in 4quadrants o Intraretinalmicrovascular abnormalities in 1 quadrant
PDR	o Neovascularization o Presence of preretinal& vitreous HM

For an early diagnosis of DRs, ophthalmologists regularly advise diabetic patients to periodically undergo medical screening of their fundus. Nevertheless, retinopathies resulting from diabetes are usually undetected until considerable damage has occurred in a patient’s fundus (usually noticed by deteriorating / loss-of vision). The adequate identification / grading of DR stages can aid physicians in determining suitable intervention procedures. Diabetic patients worldwide need regular screening for the early detection which aids timely treatment to be administered quickly. Through early disease detection and proper screening, nearly 90% of diabetic patients can be diagnosed, and the disease progression can be minimized by extricating the future consequences. The paramount problem lies in the fact that DR does not uncover typical symptoms until an extreme stage is attained [3]. Hence,

periodic eye examinations and regular check-up is entertained to reduce complications. However, a human inspection of retinal features and morphological variations in the fundus images are monotonous and demanding tasks. To overcome this drawback, several automated computer-aided diagnostic systems were evolved in recent times, which act as an assistant for the ophthalmologists to examine the retinal abnormalities.

## II. RELATED WORK

Researchers have developed or implemented efficient techniques for diagnosis of diabetic in two ways, either using binary classification or multi classification, which are explained below.

### *Binary Classification*

MeherMadhuDharmana et.al. [4] proposed method which has an effective feature extraction technique based on blob detection followed by classification of different stages of diabetic retinopathy using machine learning technique. This feature extraction technique could help automatic characterization of retina images for diabetic retinopathy with an accuracy of 83 per cent with the most efficient machine learning classification algorithm, which would help specialists to handily recognize the patient's condition in a progressively precise manner.

Messadi Mohamed et.al. [5] presented approach is based on the segmentation of blood vessels and extracts the geometric features, which are used in the early detection of diabetic retinopathy. The Hessian matrix, ISODATA algorithm and active contour are used for the segmentation of the blood vessels, they have used. Finally, they have applied the decision tree CART algorithm to classify images into normal (NO-DR) or DR. The proposed system was tested on the DRIVE and Messidor databases and achieved an average sensitivity, specificity and accuracy of 89%, 99% and 96%, respectively for the segmentation of retinal vessels and 91%, 100% and 93%, respectively for the classification of diabetic retinopathy. Finally, the obtained results indicate that our approach is effective in diabetic retinopathy detection with better accuracy over existing methods, which can help ophthalmologists in early diagnosis.

J.Anitha et.al. [7] developed CAD techniques are analyzed with respect to performance evaluation and the challenges are discussed, some suitable solutions are suggested for improving the system to be more accurate.

R.Subhashini et.al. [8] aims to construct a graphical user interface that can integrate image processing techniques together in order to predict whether the input fundus/retinal image received from the patient is affected with Diabetic Retinopathy or not; if affected, the graphical user interface will display the severity along with the required action needed to be undertaken by the user / patient. This essentially reduces the processing time involved in the process of detecting the disease and also the ophthalmologists can also have our graphical user interface as a backup that can be used for validating or assist in detecting the disease.

Manoj Kumar Behera et.al. [9] has proposed in their research two well-known predefined feature extraction techniques scale invariant feature transform (SIFT) and speeded up robust features (SURF) have been used simultaneously on each retinal images to capture the Exudates regions. These Exudates of each image stored in a feature matrix and used by the support vector machine (SVM) classifier for prediction of DR. For a 100 set of test images the average sensitivity of the model is 94%.

Karan Bhatia et.al. [10] focuses on decision about the presence of disease by applying ensemble of machine learning classifying algorithms on features extracted from output of different retinal image processing algorithms, like diameter of optic disk, lesion specific (micro aneurysms, exudates), image level (prescreening, AM/FM, quality assessment). Decision making for predicting the presence of diabetic retinopathy was performed using alternating decision tree, Ada-Boost, Naïve Bayes, Random Forest and SVM.

MasoudKhazaeFadafen et.al. [11] proposed method on the DIARETDB1 database, which includes 89 selected images for the diagnosis of diabetic retinopathy, was tested and with four models of methods available for recognizing saliencies, frequency tuned method (FT) model, the spectral residual approach (SR) model, the SDSP model: a novel saliency detection method by combining simple prior has been compared. The proposed method, while retaining the main image information (vessels), highlights the image points in comparison to the other four models with better quality. To evaluate the performance of the proposed method with other methods using Ground truth images, the ROC curve and the AUC calculation were used. The AUC parameter has the highest value in the proposed method. The results of the visual comparison, the ROC curve and the calculated AUC values indicate the desired performance of the proposed method compared to other methods.

Ali Shojaeipour et.al. [13] developed system in which the Gaussian filter is used to enhance images and separate vessels with a high brightness intensity distribution. Next, wavelets transform is used to extract vessels. After that according to some criteria such as vessels density, the location of optic disc was determined. Then after optic disc extraction, exudates regions were determined. Finally they classified the images with a boosting classifier. With utilizing the boosting algorithm, the suggested system can have a power classifier. It is generated by a combination of some weak and simple learners. Hence, this approach can reduce the complication and time consuming operation.

MirthulaBalaji et.al. [14] implemented a semantic analysis that utilizes for portraying the DR. In our proposed methodology, an innovative framework to overcome the issues of traditional methodology. Initially, an input image is acquired from the dataset. Then the preprocessing is performed where the image resizing and the double conversion is carried out and next to this image segmentation is the process where the morphological and thresholding based operations are performed. The GLCM an effective feature is chosen for extracting the features with the co- occurrence matrix. After extracting the features, the classification process is performed using Probabilistic Neural Network (PNN) which provides an effective classifier output. It is concluded that this novel vessel segmentation framework acquired better accuracy, sensitivity, F measures, specificity and precision from this experiment.

YuhaniYusof et.al. [15] focuses on classification of fundus image that contains with or without signs of DR and utilizes artificial neural network (NN) namely Multi-layered Perceptron (MLP) trained by Levenberg-Marquardt (LM) and Bayesian Regularization (BR) to classify the data. Nineteen features have been extracted from fundus image and used as neural network inputs for the classification. For analysis, evaluation were made using different number of hidden nodes. It is learned that MLP trained with BR provides a better classification performance with 72.11% (training) and 67.47% (testing) as compared to the use of LM. Such a finding indicates the possibility of utilizing BR for other artificial neural network model.

BhavaniSambaturu et.al. [17] proposed a novel method to detect hard exudates with high accuracy with respect to lesion level. In the present method they initially detected the possible candidate exudate lesions by using the back ground subtraction



methodology. Following the subsequent steps, in the last stage of algorithm they removed the false exudate lesion detections using the de-correlation stretch based method. They tested our algorithm on publicly available DiaretDB database, which contains the ground truth for all images. They achieved high performance results such as sensitivity of 0.87 and F-Score of 0.78 and Positive Predict Value (PPV) of 0.76 for hard exudate lesion level detection, compared to the existing state of art techniques.

TanapatRatanapakorn et.al. [18] has the automated software for screening and diagnosing DR, by using the combination of digital image processing techniques, has been developed. This software yields the good accuracy for the detection of DR from fundus photographs. It can be used as an alternative or adjunctive tool for DR screening, especially in the remote area where ophthalmologist is not available or in the rural area where ophthalmologist has many task overloads. However, the software yields fair accuracy for classifying the severity of DR. Further software development was required to improve the accuracy of DR classification, which may include additional digital image processing techniques or other methods based on artificial intelligence and deep learning.

AdriánColomer et.al. [19] focused on one of the most common pathologies in the current society: diabetic retinopathy. The proposed method avoids the necessity of lesion segmentation or candidate map generation before the classification stage. Local binary patterns and granulometric profiles are locally computed to extract texture and morphological information from retinal images. Different combinations of this information feed classification algorithms to optimally discriminate bright and dark lesions from healthy tissues. Through several experiments, the ability of the proposed system to identify diabetic retinopathy signs is validated using different public databases with a large degree of variability and without image exclusion.

J.Jayashree et.al. [21] examines the Diabetic retinopathy using PSO Feature Selection algorithm on three different Classifiers SVM Classifier accuracy (98), sensitivity (96.6) and specificity (96.5). SVM Classifier have got the maximum metrics percentage for PSO Feature selection algorithm.

Alexander Rakhlin et.al [22] represents a brief account of ongoing project for Diabetic Retinopathy Detection (DRD) through integration of state-of-the-art Deep Learning methods. We make use of deep Convolutional Neural Networks (CNNs), which have proven revolutionary in multiple fields of computer vision including medical imaging, and we bring their power to the diagnosis of eye fundus images.

Carson Lam et.al. [23] demonstrate the use of convolutional neural networks (CNNs) on color fundus images for the recognition task of diabetic retinopathy staging. Our network models achieved test metric performance comparable to baseline literature results, with validation sensitivity of 95%. We additionally explored multinomial classification models, and demonstrate that errors primarily occur in the misclassification of mild disease as normal due to the CNNs inability to detect subtle disease features. We discovered that preprocessing with contrast limited adaptive histogram equalization and ensuring dataset fidelity by expert verification of class labels improves recognition of subtle features. Transfer learning on pretrainedGoogLeNet and AlexNet models from ImageNet improved peak test set accuracies to 74.5%, 68.8%, and 57.2% on 2-ary, 3-ary, and 4-ary classification models, respectively.

Iyyanar P et.al. [24] develop High End-end Deep learning framework technology to improve and automate Diabetic retinopathy screening. Referral of eyes with Diabetic retinopathy (DR) to an ophthalmologist for further treatment would help in reducing the rate of vision loss, enabling timely and accurate diagnoses to the patients. Specifically in India wherein some cities, there are no doctors, or the equipment needed to diagnose Diabetic retinopathy (DR), our automated machine learning method will come handy. A proposed deep learning approach such as CNN gives high accuracy in the classification of these diseases through spatial analysis. CNN is a complex architecture inferred more from human visual prospects. Among the other algorithms/Framework, involved, the proposed solution is to find a better and optimized way to classifying the image with little pre-processing techniques. Our proposed architecture deployed with dropout layer techniques yields around 90-92 percent accuracy.

### **Multiclass Classification**

DoshnaUmma Reddy et.al. [6] considered a convolutional neural network which uses the VGG- 16 model as a pre-trained neural network for fine-tuning, and, thereby classifying the severity of DR. The model also uses efficient deep learning techniques including data augmentation, batch normalization, dropout layers and learn-rate scheduling on high resolution images to achieve higher levels of accuracy. An average class accuracy (ACA) of 74%, sensitivity of 80% at a specificity of 65% and area under the curve (AUC) of 0.80 have been achieved, which are higher than previously reported results obtained using other pre-trained networks or models.

Sumesh E P et.al. [12] created a DR detection technique, involving digital image processing, has been developed by utilizing retinal image, where fundus image has been obtained from patient's retina. Here, a MATLAB based system has been utilized for analyzing the fundus image that are captured via Peek retina attached on smartphone camera lens. This proposed work aims at segmenting the fundus image into Exudates, Micro aneurysm, Optical Disk and hemorrhage and examine whether the retinal condition is in Proliferative / Non Proliferative DR stage. To achieve this, additionally, morphological methods such as erosion and dilation have been utilized which enables the MATLAB base system to learn the pixel positioning pattern of the fundus images in order to detect the factors associated with DR. Various performance measures has been utilized in validating the proposed technique. From those performance analysis, we could observe 98% accuracy in detecting PDR and NPDR within 39 seconds (half minute). Though the attainment of accuracy is relatively high, there are further possibilities in improving the detection rate of the system.

Shailesh Kumar et.al. [16] presents an improved diabetic retinopathy detection scheme by extracting accurate area and area number of micro aneurysm from color fundus images. Regular screening of eye is crucial for detection and dealing with diabetic retinopathy. Diabetic retinopathy (DR) is an eye disease which occurs due to damage of retina as a result of long illness of diabetic mellitus. Micro aneurysms (MA) are tiny red spots on retina, shaped by inflating out of fragile part of the blood vessels. The recognition of MA at primary stage is very crucial and it is the first step in inhibiting DR. A variety of methods have been proposed for detection and diagnosis of DR. In this paper, there are two features namely; number and area of MA have been determined. Initially, pre-processing techniques like green channel extraction, histogram equalization and morphological process have been

used. For detection of micro aneurysms, principal component analysis (PCA), contrast limited adaptive histogram equalization (CLAHE), morphological process, averaging filtering have been used. Classification of DR has been done by linear Support vector machine (SVM). The sensitivity and specificity of DR detection system are observed as 96% and 92% respectively.

Laxmi Math et.al. [20] proposes the segment based learning approach for detection of diabetic retinopathy, which mutually learns classifiers and features from the data and gets significant development on recognizing the images of diabetic retinopathy and their inside the lesions. Specifically, the pre-trained CNN is adapted to get the segment level DRE (Diabetic retinopathy Estimation) and then Integrating all segment level of (DRM) is utilized to make the classification of diabetic retinopathy images. Lastly, an end-to-end segment based learning approach to deal with the irregular lesions of diabetic retinopathy. For detection of the diabetic retinopathy images obtain area under of ROC curve is 0.963 on the Kaggle dataset and also obtains sensitivity and specificity 96.37% and 96.37% on the higher specificity and sensitivity that outperforms much better than existing model.

Yung-Hui Li et.al. [25] presented a novel algorithm based on deep convolutional neural network (DCNN). Unlike the traditional DCNN approach, we replace the commonly used max-pooling layers with fractional max-pooling. Two of these DCNNs with a different number of layers are trained to derive more discriminative features for classification. After combining features from metadata of the image and DCNNs, we train a support vector machine (SVM) classifier to learn the underlying boundary of distributions of each class. For the experiments, we used the publicly available DR detection database provided by Kaggle. We used 34,124 training images and 1,000 validation images to build our model and tested with 53,572 testing images. The proposed DR classifier classifies the stages of DR into five categories, labeled with an integer ranging between zero and four. The experimental results show that the proposed method can achieve a recognition rate up to 86.17%, which is higher than previously reported in the literature.

### III. CONCLUSION

Diabetic retinopathy cannot be cured, so as to prevent vision loss, laser analysis is usually very effective if it is done before it adversely harms the retina. Provided that the stern destruction of retina has not been done, vision can be improved by the surgical elimination of vitreous gel. This study helps in the detection of retinopathy at an early stage; timely treatment of this disease will prevent permanent vision loss. This paper discussed experiments done by authors for the detection of diabetic retinopathy. This work will be useful for technical persons and researchers who need to use the ongoing research in this area. Various methods are developed to detect and treat patients suffering from diabetic retinopathy classification of different stages of diabetic retinopathy using machine learning technique.

### REFERENCES

- [1] Javeria Amin, Muhammad Sharif, Mussarat Yasmin, "A Review on Recent Developments for Detection of Diabetic Retinopathy", *Scientifica*, vol. 2016, Article ID 6838976, 20 pages, 2016. <https://doi.org/10.1155/2016/6838976>
- [2] SandhyaSoman, Jayashree R, "A Survey of Image Processing Techniques for Diabetic Retinopathy", *International Conference on Advances in computer Science and Technology (IC-ACT'18)* – 2018, ISSN: 2395-1303
- [3] Valarmathi S, Dr. R. Vijayabhanu, "A Review on Diabetic Retinopathy Disease Detection and Classification using Image Processing Techniques", *International Research Journal of Engineering and Technology (IRJET)*, Volume: 07 Issue: 09 | Sep 2020, pp 456-455.
- [4] M. M. Dharmana and A. M.S., "Pre-diagnosis of Diabetic Retinopathy using Blob Detection," 2020 Second International Conference on Inventive Research in Computing Applications (ICIRCA), Coimbatore, India, 2020, pp. 98-101, doi: 10.1109/ICIRCA48905.2020.9183241.
- [5] E. Z. Aziza, L. Mohamed El Amine, M. Mohamed and B. Abdelhafid, "Decision tree CART algorithm for diabetic retinopathy classification," 2019 6th International Conference on Image and Signal Processing and their Applications (ISPA), Mostaganem, Algeria, 2019, pp. 1-5, doi: 10.1109/ISPA48434.2019.8966905.
- [6] N. B. Thota and D. Umma Reddy, "Improving the Accuracy of Diabetic Retinopathy Severity Classification with Transfer Learning," 2020 IEEE 63rd International Midwest Symposium on Circuits and Systems (MWSCAS), Springfield, MA, USA, 2020, pp. 1003-1006, doi: 10.1109/MWSCAS48704.2020.9184473.
- [7] A. G. P. H., J. Anitha and J. N. R. J., "Computer Aided Diagnosis Methods for Classification of Diabetic Retinopathy Using Fundus Images," 2018 International Conference on Circuits and Systems in Digital Enterprise Technology (ICCSDET), Kottayam, India, 2018, pp. 1-4, doi: 10.1109/ICCSDET.2018.8821200.
- [8] R. Subhashini, T. N. R. Nithin, U. M. S. Koushik, "Diabetic Retinopathy Detection using Image Processing (GUI)", *International Journal of Recent Technology and Engineering (IJRTE)*, ISSN: 2277-3878, Volume-8, Issue-2S3, July 2019
- [9] M. K. Behera and S. Chakravarty, "Diabetic Retinopathy Image Classification Using Support Vector Machine," 2020 International Conference on Computer Science, Engineering and Applications (ICCSEA), Gunupur, India, 2020, pp. 1-4, doi: 10.1109/ICCSEA49143.2020.9132875.
- [10] K. Bhatia, S. Arora and R. Tomar, "Diagnosis of diabetic retinopathy using machine learning classification algorithm," 2016 2nd International Conference on Next Generation Computing Technologies (NGCT), Dehradun, 2016, pp. 347-351, doi: 10.1109/NGCT.2016.7877439.
- [11] Fadafen, Masoud&Mehrshad, Nasser &Razavi, Seyyed. (2018). Detection of diabetic retinopathy using computational model of human visual system. *Biomedical Research (India)*. 29. 1956-1960. 10.4066/biomedicalresearch.29-18-551.
- [12] Hamood Ali Hamood Al shamaly, Sumesh E P, Vidhyalavanya R, Jayakumari C, "Diabetic Retinopathy Detection Using Matlab", *International Journal Of Scientific & Technology Research* Volume 8, Issue 11, November 2019
- [13] A. Shojaeipour, M. J. Nordin and N. Hadavi, "Using image processing methods for diagnosis diabetic retinopathy," 2014 IEEE International Symposium on Robotics and Manufacturing Automation (ROMA), Kuala Lumpur, 2014, pp. 154-159, doi: 10.1109/ROMA.2014.7295879.
- [14] V. Govindaraj, M. Balaji, T. a. Mohideen and S. a. F. J. mohideen, "Eminent identification and classification of Diabetic Retinopathy in clinical fundus images using Probabilistic Neural Network," 2019 IEEE International Conference on

- Intelligent Techniques in Control, Optimization and Signal Processing (INCOS), Tamilnadu, India, 2019, pp. 1-6, doi: 10.1109/INCOS45849.2019.8951349.
- [15] N. H. Harun, Y. Yusof, F. Hassan and Z. Embong, "Classification of Fundus Images For Diabetic Retinopathy using Artificial Neural Network," 2019 IEEE Jordan International Joint Conference on Electrical Engineering and Information Technology (JEEIT), Amman, Jordan, 2019, pp. 498-501, doi: 10.1109/JEEIT.2019.8717479.
- [16] S. Kumar and B. Kumar, "Diabetic Retinopathy Detection by Extracting Area and Number of Microaneurysm from Colour Fundus Image," 2018 5th International Conference on Signal Processing and Integrated Networks (SPIN), Noida, 2018, pp. 359-364, doi: 10.1109/SPIN.2018.8474264.
- [17] K. K. Palavalasa and B. Sambaturu, "Automatic Diabetic Retinopathy Detection Using Digital Image Processing," 2018 International Conference on Communication and Signal Processing (ICCSP), Chennai, 2018, pp. 0072-0076, doi: 10.1109/ICCSP.2018.8524234.
- [18] Ratanapakorn, Tanapat&Daengphoonphol, Athiwath&Eua-Anant, Nawapak&Yospaiboon, Yosanan. (2019). Digital image processing software for diagnosing diabetic retinopathy from fundus photograph. *Clinical Ophthalmology*. Volume 13. 641-648. 10.2147/OPHTH.S195617.
- [19] Colomer, Adrián&Iguar, Jorge & Naranjo, Valery. (2020). Detection of Early Signs of Diabetic Retinopathy Based on Textural and Morphological Information in Fundus Images. *Sensors*. 20. 1005. 10.3390/s20041005.
- [20] Laxmi Math & Ruksar Fat, "Adaptive machine learning classification for diabetic retinopathy", *Multimedia Tools and Applications*, <https://doi.org/10.1007/s11042-020-09793-7>
- [21] J. Jayashree, Sruthi R, Ponnamanda Venkata Sairam, J. Vijayashree, "Knowledge based Expert System for Predicting Diabetic Retinopathy using Machine Learning Algorithms", *International Journal of Engineering and Advanced Technology (IJEAT)*, ISSN: 2249 – 8958, Volume-9 Issue-4, April 2020
- [22] Alexander Rakhlin, "Diabetic Retinopathy detection through integration of Deep Learning classification framework", bioRxiv 225508; doi: <https://doi.org/10.1101/225508>
- [23] Lam, Carson & Yi, Darwin&Guo, Margaret & Lindsey, Tony. (2018). Automated Detection of Diabetic Retinopathy using Deep Learning. *AMIA Joint Summits on Translational Science proceedings*. AMIA Joint Summits on Translational Science. 2017. 147-155.
- [24] Iyyanar P, Parthasarathy J, "Diabetic Retinopathy Classification Using Deep Learning Framework", *Journal Of Critical Reviews*, Vol ISSN- 2394-5125 7, Issue 14, 2020
- [25] Li, Yunghui&Yeh, Nai-Ning& Chen, Shih-Jen & Chung, Yu-Chien. (2019). Computer-Assisted Diagnosis for Diabetic Retinopathy Based on Fundus Images Using Deep Convolutional Neural Network. *Mobile Information Systems*. 2019. 1-14. 10.1155/2019/6142839.

