



# PATIENT WITH CHRONIC GRANULOMATOUS DISEASE HAVING A NASAL MASS CAUSED BY *ASPERGILLUS NIDULANS*: A CASE REPORT

<sup>1</sup>Akshay Karyakarte, <sup>2</sup>Jyoti Iravane, <sup>3</sup>Jaishree Petkar

<sup>1</sup>Chief Resident, <sup>2</sup>Professor and Head, Department of Microbiology, Government Medical College, Aurangabad, and <sup>3</sup>Professor and Head, Department of Microbiology PCMC's Post Graduate Institute, Yashwantrao Chavan Memorial Hospital, Pimpri, Maharashtra, India

**Abstract:** A 65-year-old man with Chronic Granulomatous Disease presented with a nasal mass. Nasal scraping sent for mycological examination was inoculated on two slants of Sabouraud's Dextrose Agar and incubated at 25°C and 37°C respectively. Lactophenol Cotton Blue mount from the growth confirmed the isolate as *Aspergillus nidulans*. This report states a case for *A. nidulans* being a distinct pathogen in Chronic Granulomatous Disease patients, thus warranting attention and high index of clinical suspicion. It would also be prudent to stress upon preventing secondary infections in immunocompromised patients.

**Key Words –** *Aspergillus*, Chronic Granulomatous Disease, *Aspergillus nidulans*, opportunistic pathogen

## I. Introduction:

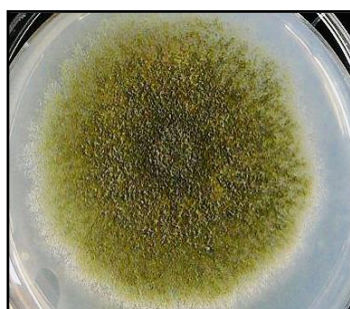
The Case: A 65-year-old man was admitted to Otorhinolaryngology ward for nasal mass. He was a known case of chronic granulomatous disease, on treatment for 15 years. The mass was non-bleeding, non-obstructive, and did not extend into the posterior nares. Mass was non-tender and did not bleed on touch. Nasal scraping was performed, and flakes produced from the mass were sent for mycological examination, before institution of empirical antifungal therapy.

## II. Materials and Methods:

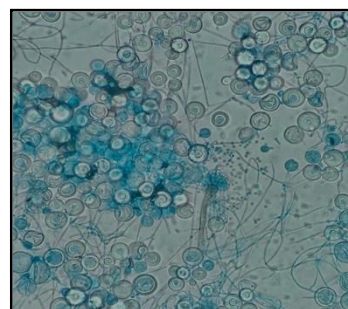
Direct microscopic examination of the sample was performed by preparing a Potassium Hydroxide (KOH) Mount, to observe for fungal elements, if any, and to ascertain their morphology, if present. On discovery of fungal elements, the sample was inoculated on two slants of Sabouraud's Dextrose Agar (SDA), one slant was incubated at 25°C and the other at 37°C, to look for dimorphism. On obtaining growth, a Lactophenol Cotton Blue (LPCB) mount was prepared to compare the morphological features to the initial KOH mount, and to definitively identify the fungal species.

## III. Results and Discussion

Direct microscopic examination of the KOH mount showed presence of fungal elements, which necessitated inoculation of fungal culture medium SDA. Two slants were inoculated and one was incubated at 25°C while the other at 37°C, to evaluate dimorphism; growth was obtained at 25°C in 48 hours. SDA showed yellow-green colonies on obverse and dull-gray inverse as seen in Figure 1<sup>[1]</sup>. LPCB mount was prepared from the growth on SDA for analysis of the fungal morphology. It showed molds with septate hyphae bearing short and smooth conidiophores. They had biserial sterigmata, with short columnar conidia. A few cleistothecia having lens-shaped ascospores were also seen, with abundant Hülle cells as shown in Figure 2<sup>[2]</sup>. Based on these findings, the isolate was identified as *Aspergillus*.



**Figure 1:** Showing growth of *Aspergillus nidulans* on Sabouraud's Dextrose Agar



**Figure 2:** Showing Lactophenol Cotton Blue mount of *Aspergillus*

Chronic Granulomatous Disease (CGD) is a genetic disorder of NADPH oxidase enzyme, which renders phagocytes unable to synthesize reactive oxygen species. This leaves patients with CGD susceptible to bacterial and fungal infections, where fungal infections have a major contribution to mortality. The most common species implicated in such infections is *Aspergillus*; most common agent is *A. fumigatus*. *Aspergillus nidulans* is commonly found in the soil, but is an opportunistic pathogen especially in CGD patients<sup>[3]</sup>. Though *A. fumigatus* is the primary fungal pathogen in CGD, *A. nidulans* is much more virulent and causes severe infection, which is refractory to common antifungals. High-dose amphotericin B is the gold standard for invasive aspergillosis, but targeted therapy for *A. nidulans* is not yet established.

#### IV. Conclusion

To conclude, we report a case of nasal mass caused by *Aspergillus nidulans* in a 65-year-old man with CGD. This report states a case for *A. nidulans* being a distinct pathogen in CGD patients, thus warranting attention and high index of clinical suspicion. Added caution is advisable recommended in CDG patients with fungal infections since *A. nidulans* not only lacks an established line of treatment, but also is refractory to generalized treatment of invasive aspergillosis. It would also be prudent to stress upon preventing secondary infections in immunocompromised patients.

#### V. References

1. Chander J. Textbook of medical mycology. JP Medical Ltd; 2017 Nov 30.
2. Kim M, Shin JH, Suh SP, Ryang DW, Park CS, Kim C, Kook H, Kim J. *Aspergillus nidulans* infection in a patient with chronic granulomatous disease. J Korean Med Sci. 1997 Jun 1;12(3):244-8.
3. Segal BH, DeCarlo ES, Kwon-Chung KJ, Malech HL, Gallin JI, Holland SM. *Aspergillus nidulans* infection in chronic granulomatous disease. Medicine. 1998 Sep 1;77(5):345-54.

