



AXIAL TRI-RADIUS IN MYOCARDIAL INFARCTION PATIENTS

^{1*} Dr. Shashikant Mane , ² Dr. Ashwin Kotwaliwale, ³Dr. Mrs. A. V. Jadhav, ⁴ Dr. S. R. Nikam, ⁵ Dr. D. T. Wagh.

1. Dr. Shashikant Mane, Professor, Department of Anatomy, Krishna Institute of Medical Sciences “Deemed to be University”, Karad.

2. Dr. Ashwin Kotwaliwale, Assistant Professor, Department of Anatomy, Krishna Institute of Medical Sciences “Deemed to be University”, Karad.

3. Dr. Mrs. A. V. Jadhav, Associate Professor, Department of Anatomy, Krishna Institute of Medical Sciences “Deemed to be University”, Karad.

4. Dr. S. R. Nikam, P.G. Student, Department of Anatomy, Krishna Institute of Medical Sciences “Deemed to be University”, Karad.

5. Dr. D. T. Wagh, P.G. Student, Department of Anatomy, Krishna Institute of Medical Sciences “Deemed to be University”, Karad.

Abstract:

Introduction: Palm prints are characteristics of every individual. It has particular pattern in Normal individual and change in pattern suggestive of certain Diseases in Patients. We decided to work on Axial Tri-radius in Myocardial Infarction Patients.

Material & Methods: Study is done on Dermatoglyphic Palm Prints of 200 Myocardial Infarction patients. Out of that 130 were male patients and 70 were female patients. Study is compared with Dermatoglyphic Palm Prints of Normal persons (130 male & 70 female). Axial Tri-radius was noted on prints of Myocardial Infarction patients and of controls.

Observations & Results: Position of Axial Tri-radius was near the proximal margin of Hand. In Male Myocardial Infarction Patients on the Right hand extra Axial Tri-radius was found.

Discussion & Summary: Myocardial infarction patients have presence of Axial Tri-radius more than one in Right hand of Male patients. This indicates one should look for Dermatoglyphic etiology for Myocardial Infarction Patients.

Index Terms : Axial Tri-radius, Palm print, Dermatoglyphics, Myocardial Infarction.

Introduction:

Dermatoglyphics means carving on the skin. Since ancient times Palmar and Plantar ridges forming variety of configurations and patterns have attracted man. Palmistry, an ancient art of fortune telling with the help of Palm has its origin in India, Palmistry continues to be very popular even today.

Ridges develop in relation to volar pads. These pads are evident around 6th week of gestation and reach maximal size by the 12th to 13th week. By the 4th month the epidermal ridges are nicely developed but the process is probably not complete before the 6th month of gestation [1]. Dermatoglyphic analysis as diagnostic tool has many advantages [2]. Finger-print patterns were also known in Assyria in 700 A.D. [3].

Identification of finger prints was employed in Korea, 1200 years ago in documenting deeds for the sale of slaves [4]. In 1684, Dr. Nehemiah Grew, English botanist, was the first person to document the description of

the epidermal ridges which make characteristic patterns when finger tip prints are taken[5]. In 1788, Mayer stated for the first time that the arrangement of skin ridges was never the same in two individuals[6]. In 1879, Dr. Henry Faulds, a medical missionary, in Japan started taking keen interest in fingerprints. He studied finger prints on prehistoric pottery found at Omori and many other places. In the Journal- Nature, He gave an account of his investigations in the year 1880. He suggested the possibility of tracing the criminals by their fingerprints[4].

Wilder (1864 to 1928) studied morphology, comparative aspects, inheritance and racial differences in ridges[7]. In 1943, Cummins and Midlo put forward the anthropological significance of dermatoglyphics. They suggested that there is difference in ridge patterns between Anthropoid Apes and Homosapiens. They were successful in showing differences in ridge pattern among different races of mankind[8]. In opinion of Penrose and Ohara(1973) the process of ridge formation takes place from the second to the 5th month of fetal life [9]. Poll H.(1877 to 1939) studied new methods, racial differences, geographic variations and symmetry in dermatoglyphics[10].

Several hypotheses have been formulated concerning the forces that are responsible of that development of specific ridge patterns. Environmental factors such as external pressure on the fetal pads and perhaps embryonic movements, particularly finger movement, can influence ridge formation, Galton (1892) and Wilder (1902-1904) are the pioneer workers to have studied the hereditary basis of dermal patterns[11]. The formation of pattern is complete by about 18th week according to Miler and Giroux [12]. Hintze Inez Whipple (1871 to 1929) has done important work by carrying out comparative dermatoglyphic surveys[13].

A Tri-radius is formed by the confluence of three ridge systems. The geometric centre of the tri-radius is designated as a tri-radial point. The Axial Tri-radius is the tri-radius close to the palmar axis. It is present normally near the proximal margin of palm and separates the thenar and hypothenar eminences[12]. Axial Tri-radius is denoted as 't' and is usually not more than 10% of the distance between the distal crease of the wrist and proximal crease of the middle finger. This tri-radial point gets displaced in number of Diseases, so We decided to study on this topic.

Materials & Methods:

Design of Study: Observational Study.

Material used:

Wooden table of suitable height, Porcelain tile. "Kores" duplicating ink, Cotton guage ball, White crystal bond paper, Spirit, Soap, water, towel, Magnifying lens.

Method:

The method used to collect the data for the resent study was standard ink method. The person whose finger and palm prints were to be recorded was made to wash Palm & Fingers first with soap and water. So that both hands were made free of oil, sweat and dirt, and wiped with clean towel. The porcelain tile was kept on table. A small amount of Kores duplicating ink was spread over it with help of cotton guage ball to obtain a thin uniform film of ink on the tile.

Palm prints:

Palmprints of both hands obtained after inking with the help of cotton guage ball. A uniform film of ink was obtained on the tile with cotton guage ball. Then with help of same cotton guage ball ink was spread uniformly on right hand. Then first the hand is extended at wrist joint and touched the paper kept on the table and then slowly whole of the hand is kept on the paper. Pressue is applied on the interphalangeal joints, head of metacarpals and dorsum of hand. With the help of fingers or blunt end of pencil little pressure is applied on the webspace between the fingers. Complete palm impression including the hollow of space was obtained over the paper. Same procedure was applied to left hand and palm prints of both hands were obtained and recorded. The prints obtained were immediately examined with hand lens and care was taken to include all essential details.

Tri-radii were noted. Position of Axial Tri-radius was noted.

Results were analyzed Statistically. Statistical Significance was considered when 'p' value was equal to or less than 0.05.

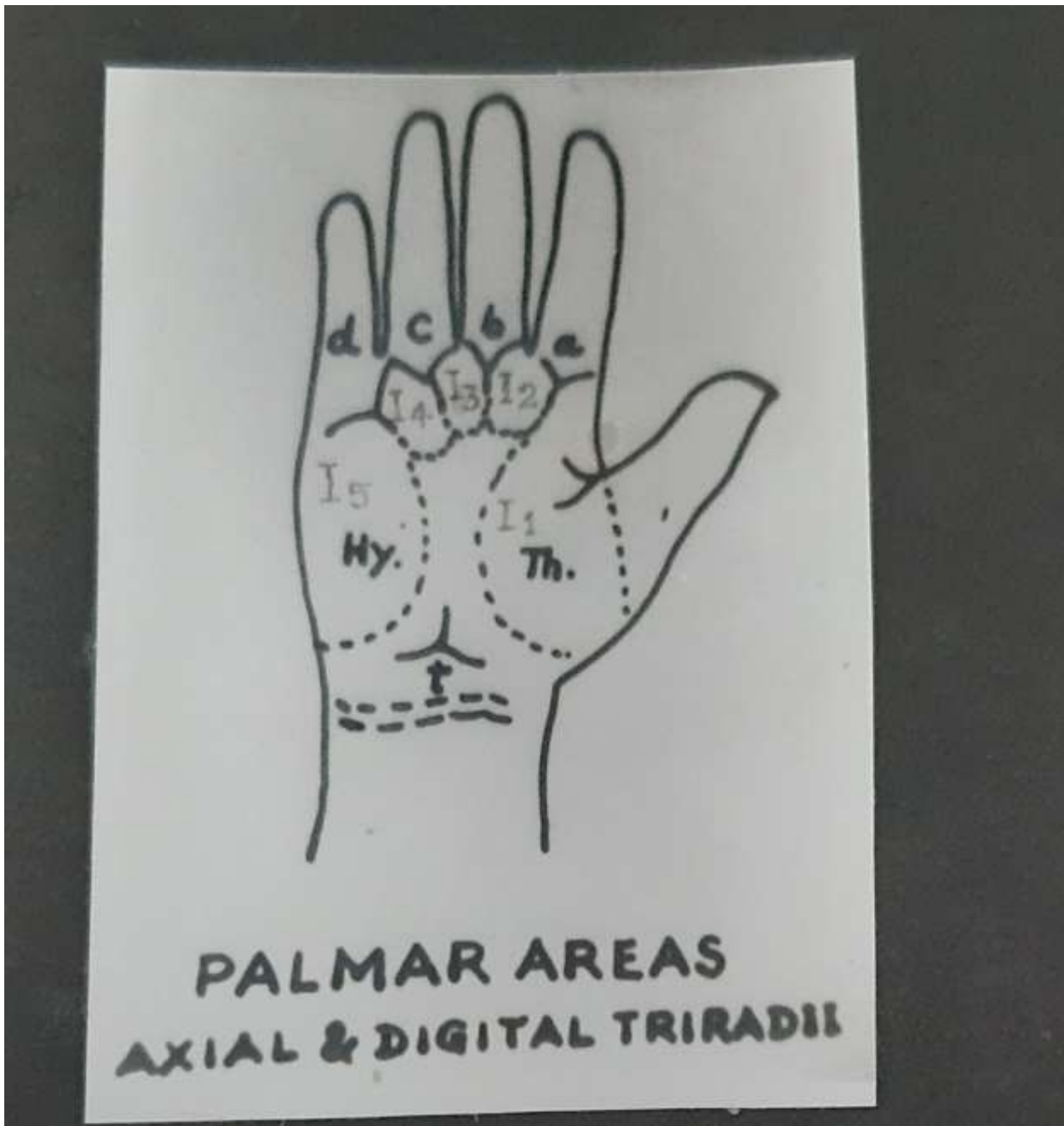


fig 1: photograph showing axial tri-radius (denoted by 't')

Observations & Results:

Axial tri-radius is situated on Palm in between Thenar & Hypothenar eminences(fig 1).

Dermatoglyphic palmprint shows Axial tri-radius (denoted by 't') near the proximal aspect of Hand (fig 2).

Frequency of total number of tri-radial in Male were 5, barring few cases(Table 1).

table 1: frequency of total number of tri-radial in male(n=130)

Hand	Control (%)			Patient (%)		
	4	5	6	4	5	6
Left	0	130	0	1	129	0
	0	(100.00)	(0.00)	(0.76)		(99.23)
Right	0	129	1	1	128	1
	0	(99.23)	(0.76)	(0.76)		(98.46)
				(0.76)		

Inference: $\chi^2 = 1.00$; P is greater than 0.05. So difference is not Statistically Significant.

Frequency of total number of tri-radial in Female were also 5 (Table 2).

table 2: frequency of total number of tri-radii in female(n=70)

Hand	Control (%)			Patient (%)		
	4	5	6	4	5	6
Left	1 (1.42)	69 (98.57)	0 (0.00)	1 (1.42) (0.00)	69	0 (98.57)
Right	0 (0.00) (0.00)	70 (100.00)	0 (0.00)	0 (0.00) (0.00)	70	0 (100.00)

Inference: $\chi^2 = 0.00$; P is greater than 0.05. So difference is not Statistically Significant.

In all categories frequency of 5 'tri-radii' was observed in majority of subjects. Variations from this, that is either 4 or 6 'tri-radii' was observed in extremely few cases.

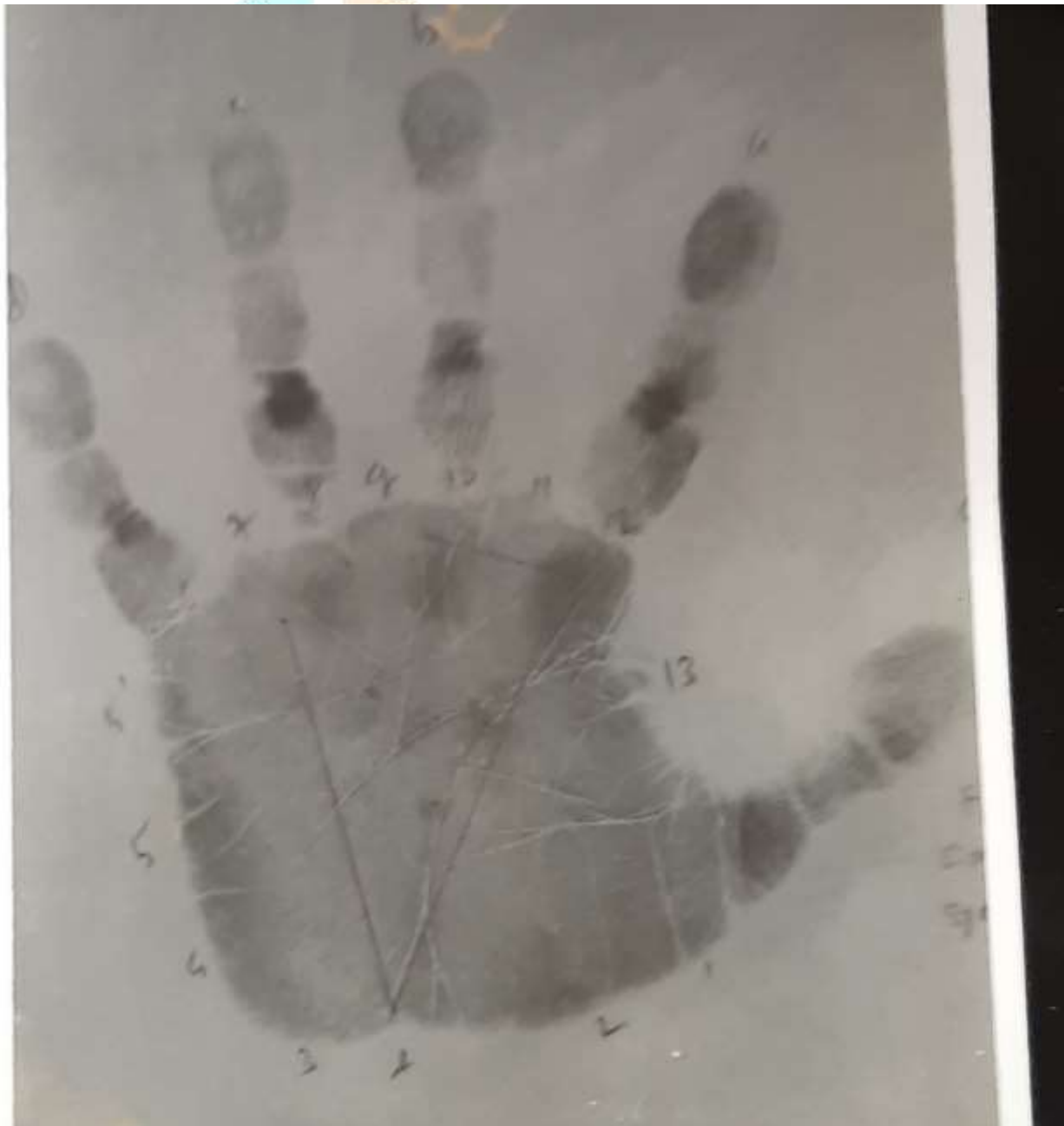

fig 2: dermatoglyphic palmprint showing axial tri-radius (denoted by 't', near the proximal margin of palm between 2 and 3)

Discussion & Summary:

Axial tri-radius in Our Study is present near the proximal margin of palm . Axial tri-radius is denoted as 't' and is usually not more than 10% of the distance between the distal crease of the wrist and proximal crease of the middle finger.

This tri-radial point gets displaced in number of conditions such as Mongolism, the D₁ syndrome, the broad thumb and great toe syndrome, Turner's syndrome and congenital heart defect[12]. According to Miller and Giroux, Axial tri-radius is present normally near the proximal margin of palm and separates the thenar and hypothenar eminences[12].

Sometimes more than one axial tri-radius may be present. The following criteria as detailed by Cummins and Midlo(1943), Hale et al(1961) and Penrose(1961) have been used to indicate the position of axial tri-radius. The axial tri-radius is indicated as 't' when it is near the wrist crease; it is indicated as 't'" when it is near the centre of the palm; and it is indicated as 't"' when it lies intermediate near a lines transecting the base of the thumb [14]. While, Penrose (1954) suggested the position of axial tri-radius depending upon 'atd' angle as follows: The axial tri-radius is indicated as 't' when the 'atd' angle is less than 45⁰ ; it is indicated as 't'" when the 'atd' angle is in between 45⁰ and 56⁰ ; and it is indicated as 't"' when the 'atd' angle is more than 56⁰ [15]. If more than one axial tri-radius is present, the most distal axial tri-radius is used for analysis.

The frequency of double proximal axial tri-radius (DPAT), which results in palmar parathenar pattern has been reported to be increased in these with ventricular septal defect (VSD). Hook EB; Bonenfant R. in 1975 scored presence of this pattern in 313 patients with congenital heart defects[16]. Preliminary studies in dermatoglyphics in congenital heart diseases was done by Sainani GS, Phadke MA, Mutalik[17]. David TJ reported in 1978 absence of 'd' tri-radius in 3 out of 800 patients with congenital heart disease[18].

As per study of Annapurna et al, Multiple axial tri-radii were noted in rheumatic heart diseases[19]. According to Ahuja et al, They found considerable decrease in the 't-d' ridge count in all categories of congenital heart disease studied, showing a distal displacement of the axial tri-radius [20].

So all the above discussion indicates importance of Axial tri-radius . Hence like other parameters, study of Axial tri-radius is must to explore the etiology of Myocardial Infarction Patients.

Conflict of Interest:

There is no conflict of interest amongst authors.

Acknowledgement:

Great help given by Department of Preventive & Social Medicine is been acknowledged.

Bibliography:

- 1.Alter, M. and Schulenberg R. 1966. Dermatoglyphics in Rubella syndrome. JAMA , Vol: 197 : 685-688.
- 2.Vaidya, R. B. 1979. Dermatoglyphics in schizophrenia. Dissertation for M.S. (Anatomy). Submitted to Shivaji University, Kolhapur.
- 3.Waghmore, R.B. 1990. Dermatoglyphics in Vitiligo. Dissertation for M.D.(Skin and V.D.). Submitted to Bombay University, Bombay.
- 4.Kitson, S. 1983. The development of finger print system. Indian Police J. Vol. 30: 26-32.
- 5.Lambourne , G. 1984. The fingerprint story. Publisher Harrap Ltd, London.
- 6.Achs, R. and Harper, R. 1968 Dermatoglyphics. Am. J. Obster. Gynecol.Vol.101: 1006-1023.
- 7.Wilder (1864-1928). Cited by Cummins, H. and Midlo, C.1961. "Finger prints, Palms and Soles". Dover Publications, New York: 20.
- 8.Saha, K. C. 1760. Dermatoglyphics. J. Indian Med. Associ. Vol.54: 428.
- 9.Penrose, L. S. and Ohara, P. T. 1973. The development of the epidermal ridges. J. Med. Genet. Vol. 10: 201-208.
- 10.Poll, H.(1877-1939). Cited by Cummins H. and Midlo C.1961. "Finger prints, Palms and Soles". Dover Publications, New York: 21.
- 11.Schaumann, B., Jonson, S.B. and Jantz, R. L. 1982. Dermatoglyphics in seizure disorders. Prog-Clin-Biol-Res. 326-334.
- 12.Miller, J. R. and Giroux, J. 1966. Dermatoglyphics in pediatric practice. J. Pediatr. Vol.69: 302-312.

13. Hintze (1947). Cited by Cummings, H. and Midlo, C. 1961. Finger prints, Palms and Soles. Dover Publications, New York: 13.
14. Kumar, S. et al. 1974. Dermatoglyphic in healthy Indian Children. Indian J. Pediatric. Vol.41: 249-256.
15. Penrose, L.S. 1954-55. The distal triradius 't' on the hand of parents and sibs of mongol imbeciles. Ann. Hum. Genet. Vol. 19: 10, Cited by Schaumann and Alter. 1976.
16. Hook, E.B. and Bonenfant R. 1975. Parathenar palmar pattern: a dermatoglyphic sign of possible clinical significance. Hum. Hered. 25(6): 509-512.
17. Sainani, G. S., Phadke, M. A., Mutalik, G. S. 1976. Dermal patterns in congenital Heart disease. Indian Heart J. Jan, 28(1): 23-16.
18. David, T. J. 1981. Dermatoglyphics in congenital heart disease. J. Med. Genet. Oct, 18(5): 344-349.
19. Annapurna, V. et al. 1978. Dermatoglyphic studies in rheumatic heart disease. Hum Hered. 28(1): 72-78.
20. Ahuja, Y. R. et al. 1982. Dermatoglyphic studies in congenital heart disease in India. Acta Anthropogenet; 6(3): 141-150.

