



Diabetic Retinopathy Detection: An App

Deep C. Bhatt¹, Maulin A. Darji², Vinay Agrawal³, Parth Singh⁴

^{1,2,3} Department of Computer Engineering, Parul University

Abstract- Diabetic Retinopathy (DR) is an eye disease caused due to constant diabetes and it found to be the main cause of blindness young generation in any nation. Today, around 415 million people are living with diabetes from which 285 million people is currently suffering from DR (Diabetic Retinopathy) a complication of diabetes which affect the eye. Most of the people are not aware that diabetes can also be the reason of their vision-oriented problems. DR have 3 features: Micro aneurysms (MAs), Hemorrhages (HMs) and Exudates (EXs). Which can be detected from a retinal image of patient known as Fundus image. This paper explains the disease, it's features and throw light on the method we have applied for detection of Exudates and Hemorrhages.

Keywords- Microaneurysms, Hemorrhages, Exudates, Image processing, Morphological operation, CNN

I. INTRODUCTION

Diabetic Retinopathy happens when sugar level of blood incline to a certain level that damage blood vessels in the retina. This damage can cause temporary or permanent blindness [4]. In medical field Funds images (Photographs of retina) is used to detect this disease.

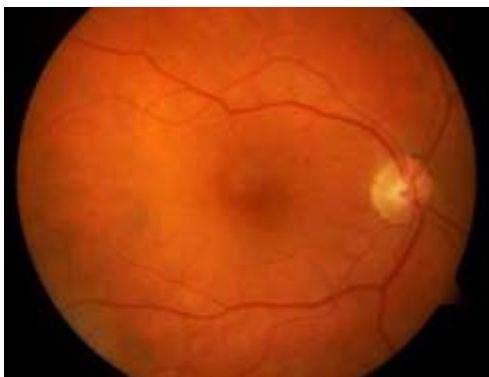


Fig.1 Fundus Image

This disease has 2 types:

- 1) Proliferative (PDR)
- 2) Non-Proliferative (NPDR).

Most common type is NPDR. In early stages of NPDR, exudates begin to emerge as a result of leak of lipid from abnormal blood vessels [9]. Hard exudates and Soft Exudates are the major cause of blurred central vision. In Next Stage it converts into PDR, in which very small vessels get damaged by extreme sugar level in blood in retina and start bleeding. The bleeding causes scar tissues which is responsible to shrink and pull the retina [11]. This will result in bleeding into vitreous cavity (event called as Haemorrhage). In other words,

Haemorrhages occur when MAs burst. A Haemorrhage may be a small micro area of blood which protrudes from artery or vein within the backside of the attention [13]. If left untreated, this may happen repeatedly and can cause immediate and severe visual loss.

In this paper, most of the work is targeted towards detecting Haemorrhages, Hard and soft exudates. Following paper organized accordingly. In the next section, the methodology used for detection of diabetic retinopathy is illustrated.

II. METHODOLOGY

In most of the existing system the whole process is divided into 3 major steps.

- 1) Pre-processing
- 2) Feature Extraction
- 3) Classification.

A. Pre-Processing

Every image is made of 3 basic color channels:

- 1) Red
- 2) Green
- 3) Blue

We have selected Green channel as the contrast of Hard exudates, Soft exudates and Red dots can be is seen quite conspicuously. In addition to that green channel do not under-illuminate or over-saturate the image like their counterparts.

This step's ultimate aim is to crop and resize the image. In other words, all images are not of the same size and every one of them need to be in equal measurements. In order to standardize the images, FOV (Field of View) of the fundus image (which are circular) needs o first cropped to a square of side which is equal to the diameter of the FOV. On the other

hand, some images do not have top and bottom parts. Thus, a black patch is added to such images to make them equal to their counterparts. Finally, this new image is sampled down to size of 512 X 512 pixels as given in Figure.

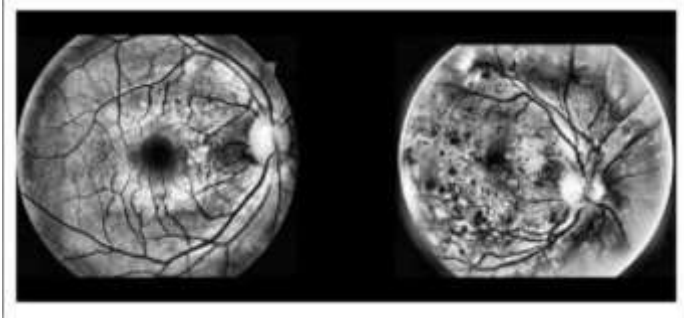


Fig.2 Image before and after preprocessing *B. Feature Extraction*

Diabetic retinopathy mainly involves 3 issues.

1) Exudates (Soft and Hard)

Exudates are small yellow objects in retinal fundus images. It is basically a pus-like or clear fluid which leaks out of the blood vessels into nearby tissues. Soft exudates usually have a fluffy and blocks the optic nerves. They are more whitish. However hard exudates are similar to lipid and of yellow colour and granular in appearance. To detect exudates, we removed all the object that have size of greater than 3000 pixels. Further classification is done on the basis of RGB factor.

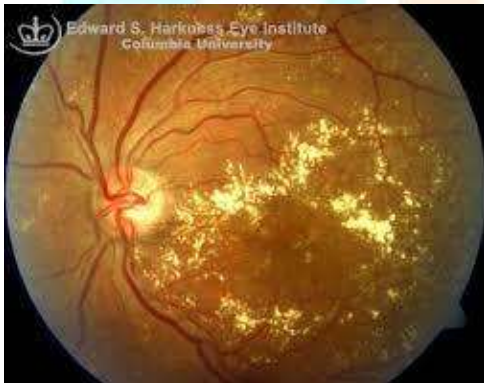

Fig.3 Exudates (Soft and Hard)

2) Red Dots

Red dots are considered as haemorrhage which is nothing but blood from ruptured blood vessels. It affects one's retina and can be the cause of blurred vision. It appears on the fundus image as blood with pale white spots which are made from fibrin (a protein that work to stop bleeding). Detection of such red dots is done by identifying object which are smaller or equal to 10 pixels.

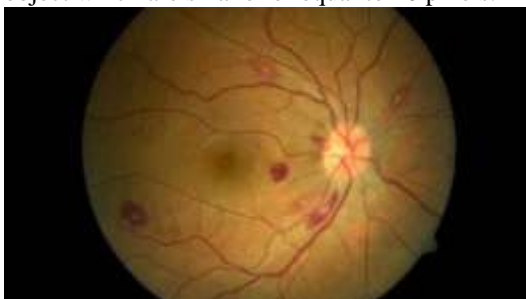

Fig.4 Red blood dots

3) Microaneurysms

When one is suffering from NPDR, the walls of blood vessels in his retina will be weakened. As a result, this tiny aneurism cause swelling

in the side of blood vessel. If left untreated, these miniature aneurysms can explode and leak blood. Matched filter and thresholding technique are used to detect MAs.

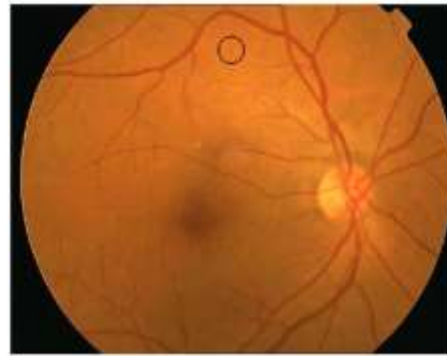


Fig.5 Microaneurysms

C. Convolution Neural Network (CNN)

CNN is also known as CovoNet. It is a class of deep learning and networks which is mostly used analyse visual imagery [17]. We have implemented convolution neural network for our software as it is quite effective for output.

CNN is basically multiplication of matrix. Any image is nothing but a matrix representation and we multiply such matrix with other image's matrix to compare and train machine.

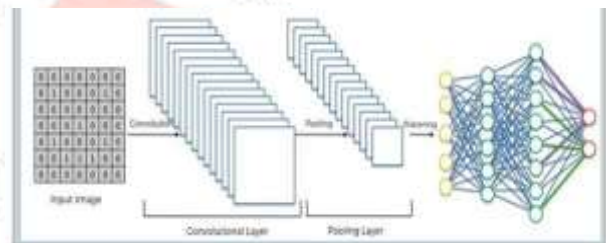


Fig.6 Concept of CNN

As per the figure the input image and output image have 2 layers convolution layer and pooling layer. Convolution layer extract features from the image which is provided by the user [19]. Its main function is to preserve the spatial bond between pixels by learning itself. Pooling is a part of Deep Learning Visual Reorganisation (local neural network feature detector). We have used max pooling that calculates maximum (largest value) in each patch of each feature map for better results. The results are down sampled that highlight the most present feature in patch which give us better efficiency.

D. Flutter

Flutter is Google's platform for creating applications. We have used this platform to make our application [18]. We have used basic application structure and created the app which need a dataset, perform the detection of retinopathy and gives the output.

III. DATA SET

Various datasets are studied by us and we have worked on two different dataset which are as follow:

1) DIARETDB0 - Standard Diabetic Retinopathy Database Calibration level 0.

The current database consists of 130 color fundus images of which 20 are normal and 110 contain signs of the diabetic retinopathy. Images were captured with a 50-degree field-of-view digital fundus camera with unknown camera settings [23]. The data correspond to practical situations, and can be used to evaluate the general performance of diagnosis methods. From this dataset we use some images for testing and some for training the machine.

We took around 90 images from the dataset to train our model and rest 40 images were kept for testing.

Here are the result and the efficiency that we got from training these 90 images and testing of remaining images.

2) DIARETDB1 - Standard Diabetic Retinopathy Database Calibration level 1.

This dataset consists of 89 color fundus images of which 84 contain at least mild non-proliferative signs of the diabetic retinopathy, and 5 are considered as normal which do not contain any signs of the diabetic retinopathy according to all experts who participated in the evaluation [22]. Images were captured using the same 50-degree field-of-view digital fundus camera with varying imaging settings. From this dataset we use some images for testing and some for training the machine [14].

We took around 60 images from the dataset to train our model and rest 29 images were kept for testing.

Here are the result and the efficiency that we got from testing of remaining images.

III. FUTURE WORK

The observations presented in these papers are currently being extended to these broader set of methods. Feasible scope of future modifications includes:

To start analyzing of different dataset which are useful for the project. The results show that the method proves the accuracy of the system achieved up to 78% when analyzed with the given database of the diabetic patients. So, we will try to achieve more efficiency than the existing one. We will try to overcome and reduce the drawbacks which are faced by the existing method. We will also try to utilize multiple images per patient. This existing software do not detect microaneurysms yet but in future we will work on it.

IV. CONCLUSION

After design and implementation of diagnostic tool for Diabetic Retinopathy was successfully completed. This tool has three major steps; Pre-processing, feature extraction and classification. The proposed method is in a position to detect all the abnormal features within the fundus images. The system proposed a completely unique combination of image preprocessing technique for retinal anatomical structures and

classification with neural network. The machine may be based on a device that extracts irregular features such as microaneurysms, exudates, hemorrhages and new vessels etc. for grading the severity of Diabetic Retinopathy. Early detection, diagnosis and examination of DR are gaining importance as it allows timely treatment and loss of vision. The proposed method gives 70% accuracy. Also, this method is found to scale back the manual effort required for the detection and also the accuracy gets increased. The algorithms proposed are computationally efficient for detecting and diagnosing the diseases from the fundus images.

REFERENCES

- [1] Romany F. Mansour, "Evolutionary Computing Enriched Computer Aided Diagnosis System For Diabetic Retinopathy: A Survey," IEEE Reviews in Biomedical Engineering (Volume: 10), 2017, pp. 334–349.
- [2] Amol Prataprao Bhatkar, Dr. G.U.Kharat. Detection of Diabetic Retinopathy in Retinal Images using MLP classifier 2015 IEEE International Symposium on Nano electronic and Information Systems, India,2015.
- [3] Ramon Pires, Sandra Avila, Herbert F. Jelinek, Jacques Wainer, Eduardo Valle, and Anderson Rocha, Beyond Lesion-based Diabetic Retinopathy: a Direct Approach for Referral, IEEE Journal of Biomedical and Health Informatics (Volume: 21 , Issue: 1 , Jan. 2017), pp. 193–200.
- [4] Raju Maher, Sangramsing Kayte, Dr. Mukta Dhopeswarkar, "Review of Automated Detection for Diabetes Retinopathy Using Fundus Images," IJARCSSE.
- [5] S.D. Shirbahadurkar, V. M. Mane, D. V. Jadhav, "A Modern Screening Approach for Detection of Diabetic Retinopathy," IEEE, 2018.
- [6] R.S. Mangrulkar, "Retinal Image Classification Technique For Diabetes Identification," International Conference on Intelligent Computing and Control (I2C2),2017.
- [7] Yashal Shakti Kanungo,Bhargav Srinivasan, Dr. Savita Choudhary, Detecting Diabetic Retinopathy using Deep Learning, IEEE International Conference on Recent Trends in Electronics, Information & Communication Technology, 2018.
- [8] Manjiri B. Patwari, Ramesh R. Manza, Yogesh M. Rajput,Manoj Saswade, Neha Deshpande, "Review on Detection and Classification of Diabetic Retinopathy Lesions Using Image Processing Techniques", International Journal of Engineering Research & Technology, Vol. 2 Issue 10, October – 2013.
- [9] Darshit Doshi, Aniket Shenoy, Deep Sidhpura, Prachi Gharpure, Diabetic Retinopathy Detection using Deep Convolutional Neural Networks, IEEE, International Conference on Computing, Analytics and Security Trends, 2016.
- [10] Ankita Gupta, Rita Chhikara, Diabetic Retinopathy: Present and Past, Procedia Computer Science, Volume 132, 2018, pp. 1432-1440.
- [11] Santhakumar R, Megha Tandur, E R Rajkumar, Geetha K S, Girish Haritz Kumar, Machine Learning Algorithm for Retinal Image Analysis, 2016.
- [12] B. Sumathy, S. Poornachandra, Automated DR and prediction of various related diseases of retinal fundus images, Biomedical Research 2018.
- [13] Sohini Roychowdhury, Dara D. Koozekanani, Keshab K. Parhi, DREAM: Diabetic Retinopathy Analysis Using Machine Learning, IEEE Journal of Biomedical and Health Informatics (Volume: 18 , Issue: 5 , Sept. 2014),pp. 1717 – 1728.
- [14] Nisha A. Panchal, Dr. Darshak G. Thakore, Dr. Tanmay D. Pawar, Detection of Diabetic Retinopathy: A Survey, IJRASET, 2018.
- [15] Mr. M.C. Shanker, Adlin Belma, Aafreen Fathima, Nishandhini, Nithya, Early Detection of Diabetic Retinopathy using Fundus Images, IJRASET,2018.
- [16] <https://towardsdatascience.com/a-comprehensive-guide-to-convolutional-neural-networks-the-eli5-way-3bd2b1164a53>
- [17] <https://adeshpande3.github.io/A-Beginner%27s-Guide-To-Understanding-Convolutional-Neural-Networks/>
- [18] <https://flutter.dev>
- [19] <https://medium.com/technologymadeeasy/the-best-explanation-of->

convolutional-neural-networks-on-the-internet-fbb8b1ad5df8
[20] <https://www.alliedacademies.org/abstract/automated-dr-and-prediction-of-various-related-diseases-of-retinal-fundus-images-8739.html>
[21] <https://www.mayoclinic.org/diseases-conditions/diabetic-retinopathy/symptoms-causes/syc-20371611>
[22] <https://www.it.lut.fi/project/imageret/diaretdb1/>
[23] <https://www.it.lut.fi/project/imageret/diaretdb0/index.html>

AUTHORS

First Author – Deep Bhatt, B.Tech Computer Science and Engineering, Parul University, bhattdeep9816@gmail.com.

Second Author – Darji Maulin, B.Tech Computer and Science and Engineering, Parul University, darjimaulin@gmail.com.

Third Author – Vinay Agrawal, B.Tech Computer and Science and Engineering, Parul University, vinayagrwal555@gmail.com.

Fourth Author – Parth Singh, parth.singh2990@paruluniversity.ac.in.

