



Surgical management of a radicular cyst using Symphysis onlay bone grafting.

Dr.Venkatesh balaji Hange¹,Dr. Shrey Srivastava², Dr.Shishir Mohan Devki³,Dr. Hasti Kankariya⁴,

Junior resident ¹,senior lecturer ²,Head of the department³,professor ⁴,Department of Oral & Maxillofacial Surgery^{1,2,3,4}, K.D. Dental college & Hospital, Mathura, U.P., India.

INTRODUCTION :- Radicular Cysts are believed to be formed from epithelial cell rests of Malassez (ERM), which are remnants of Hertwig's epithelial root sheath, present within the periodontal ligament.(1) Radicular cyst is one of the most frequently occurring cysts in the oral cavity usually accompanied by infection or an infectious disease that is followed by enlargement. They are the most common odontogenic cyst affecting Maxilla more than three times the mandible.(2) Around 60% of all jaw cysts are radicular or residual cysts. The cyst reflects a chronic inflammatory cycle and only grows over an extended time period. Some studies in the UK and South Africa have shown that radicular cysts occur more frequently in males between the third and fifth decades of life and more frequently found in the anterior maxilla than other parts of the mouth.(3)

Cyst treatment may be done by surgical or non-surgical methods; either by marsupilization or enucleation, depending on the size and location of the lesion, the bone integrity of the cystic wall and its proximity to vital structures. (4) After the marsupilization or enucleation of the cyst ,moderate to large cystic cavity remains which can be either left to heal by itself or filled with various types of bone grafts are used such as autogenous graft, allogeneic graft, alloplastic graft and Xenogeneic graft to promote sufficient periapical wound healing.

This case report presents radicular cyst of anterior maxilla treated by cyst enucleation followed by apicectomy of involved teeth ,reconstructed using autogenous bone graft harvested from mandibular symphysis.

CASE REPORT :- A 60 year old reported to the department of oral and maxillofacial surgery, K.D. Dental College & Hospital with a chief complaint of painless slow growing swelling on anterior palate.patient gave history foreign body impingement of sugar cane husk 35 years back.since the there are repeated episode of swelling & pus discharge but patient apparently did not take any dental treatment. Patient gave history of self-medication of antibiotic & painkiller upon onset of swelling.

3 months back patient visited for private dental clinic regarding tenderness with 11# & 21# , for which root canal treatment initiated by the private dentist. During root canal treatment ,they

discovered well defined solitary radiolucency in the maxillary anterior region .for which patient referred to our department.

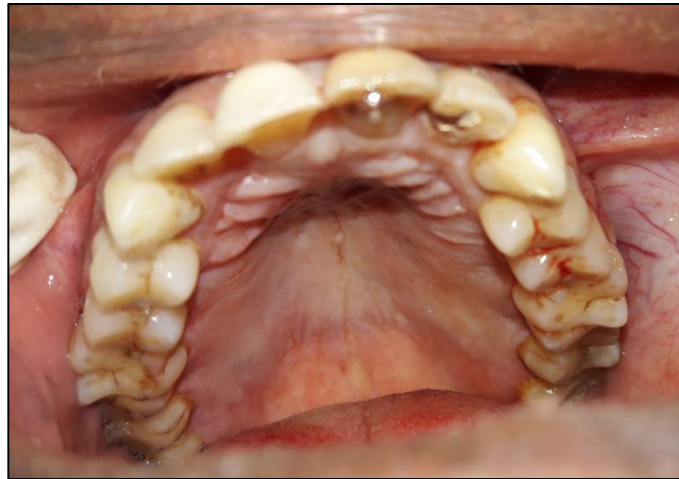


Fig. 1 Pre-operative palatal view after discharge of pus.

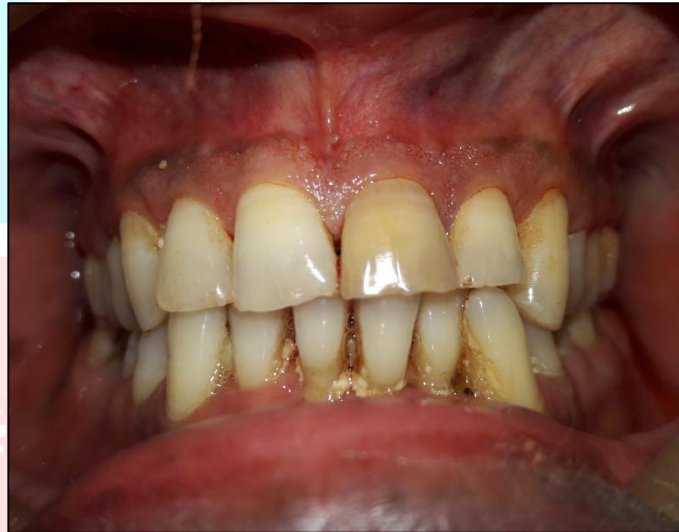

Fig. 2 Pre-operative occlusion with discolouration with 21#.

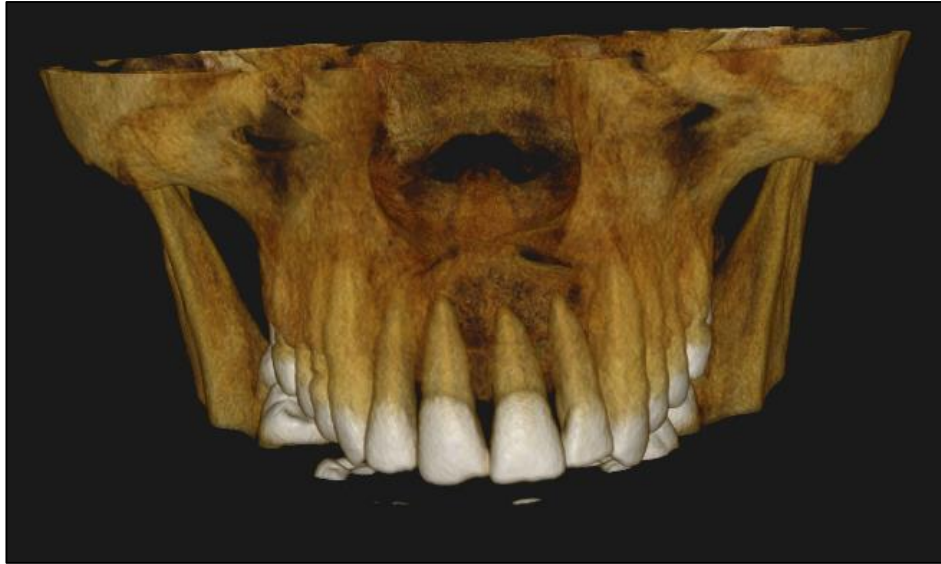

Fig.3 3D reconstruction CBCT showing well defined radiolucency with apices of 11,21 ,22.

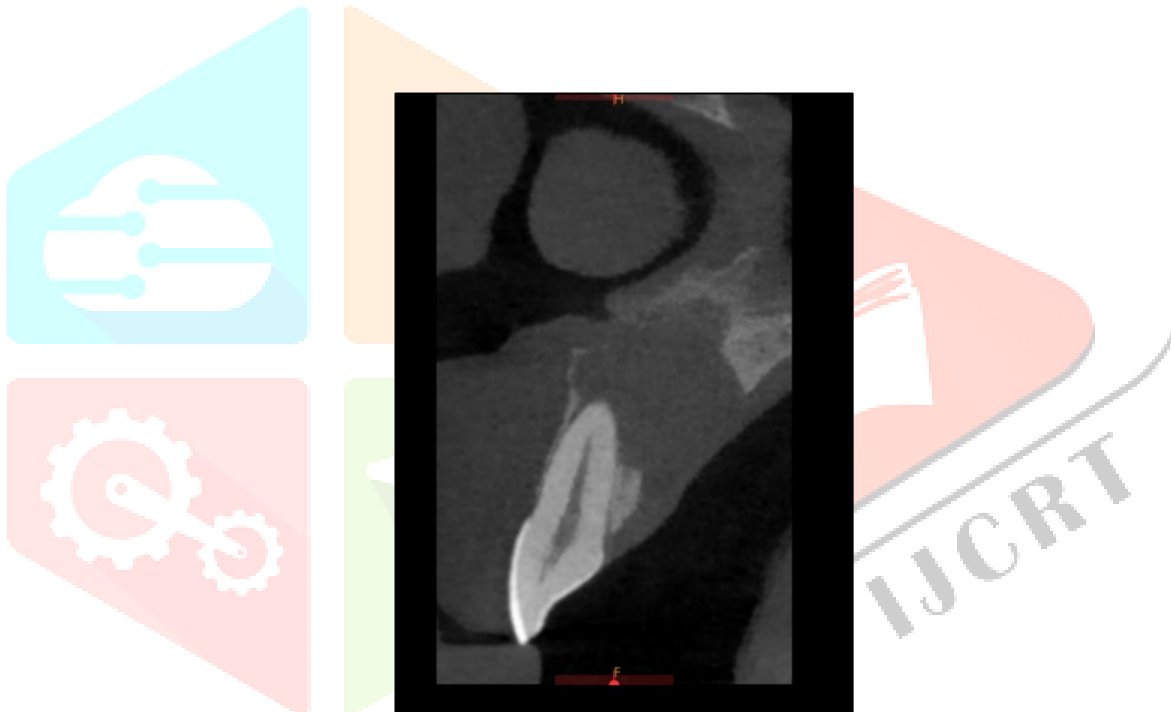


Fig.4 Sagittal plane of CBCT scan showing perforation comparatively more on palatal cortex as well as perforation of floor of nasal cavity.

On examination the lesion was round to oval, sessile, well circumscribed swelling on anterior hard palate, measuring about 2 x 1.5 cm (approx), extending from 21 to 23 which was fluctuant in nature with no erythematous changes, there were no signs of paraesthesia or discharge associated with it. Clinically the lesion appeared to be a benign odontogenic pathology, with the provisional diagnosis of radicular cyst.

All the necessary pre surgical blood investigations which were carried out were found to be within normal limits. The cone beam computed tomography shows, Well-defined solitary hypodense Osteolytic lesion is seen in maxillary anterior region extending:

1. Mesio distally: from distal of 11 to distal surface of 23.
2. Superio inferiorly: from the alveolar crest of bone to the involvement of nasal cavity. There is perforation of floor of nasal cavity.
3. Labio palatally: minimally expansile lesion with the perforation of labial and palatal cortical plate seen.
4. Blunting of apex is seen s/o Root Resorption I.r.t 21. based upon above mentioned findings radiographic diagnosis of Benign Odontogenic Cyst i.r.t 11, 21, 22 were made. differential diagnosis includes radicular Cyst i.r.t 11, 21, 22.

Based upon the clinical findings & radiographic diagnosis, cyst Root canal therapy followed by enucleation & apicectomy i.r.t 11,21,22 reconstruction of bony defect with autogenous bone graft harvested from symphysis were planned.

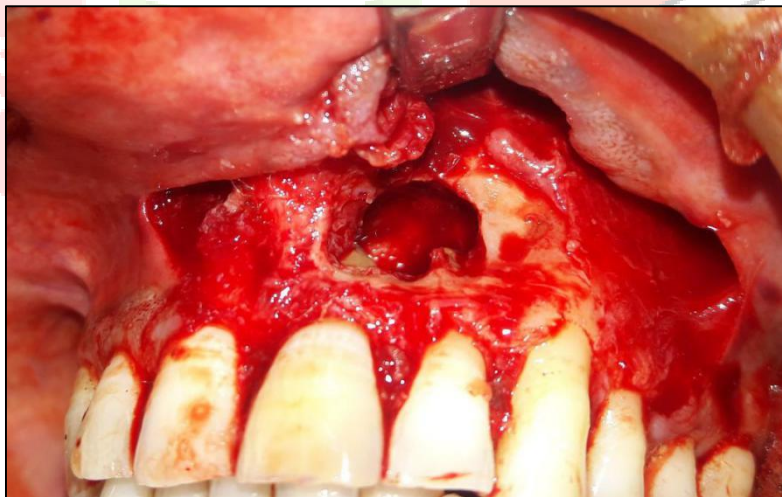


Fig.5 Exposure of cyst via buccal approach using crevicular incision i.r.t 11, 12,21,22,23,24 & bilateral releasing incisions.

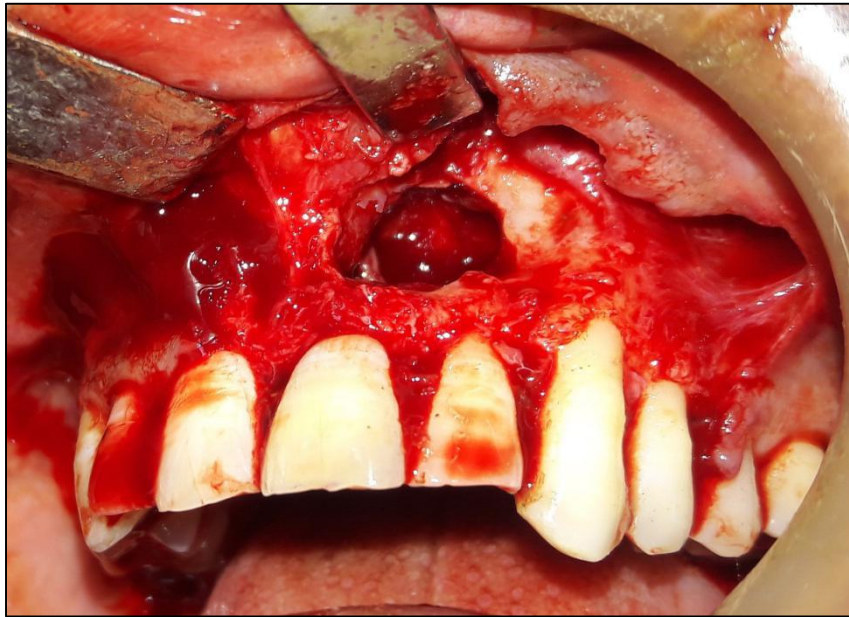


Fig.6 showing bony window created for complete enucleation of cyst ,apicectomy with 21,22

The excised specimen of cyst were collected & sent to oral pathology department , K.D. Dental College & Hospital for histopathological examination. The histopathological examination revealed non-keratinised stratified squamous epithelium with long irregular rete ridges showing a characteristic arcading pattern supported by the underlying connective tissue. which gave final diagnosis of radicular cyst.

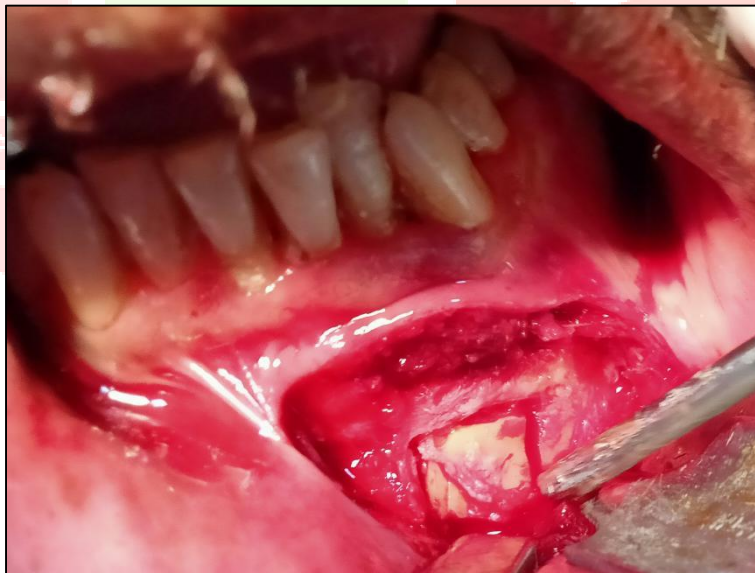


Fig. 7 Showing bone graft prepared for harvesting from mandibular symphysis 15 x 10 x 5mm graft were taken

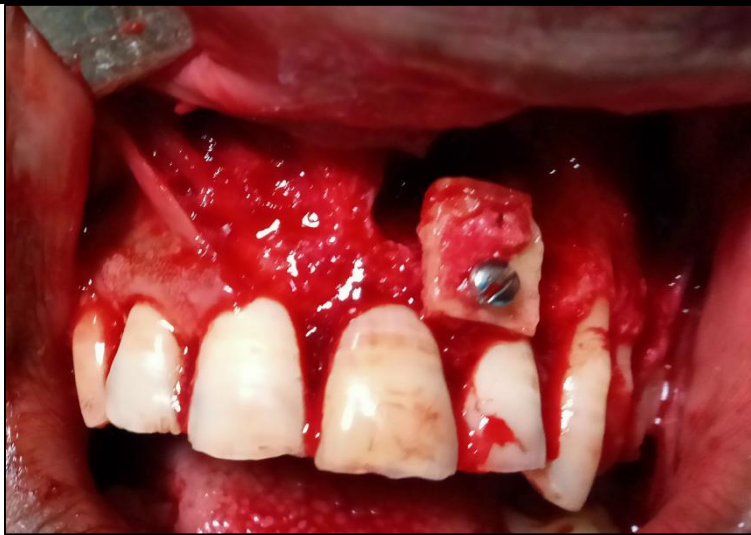


Fig. 8 Showing bone graft placed using 2x6mm stainless steel screw to cover bony window ,collagen membrane also placed over graft .

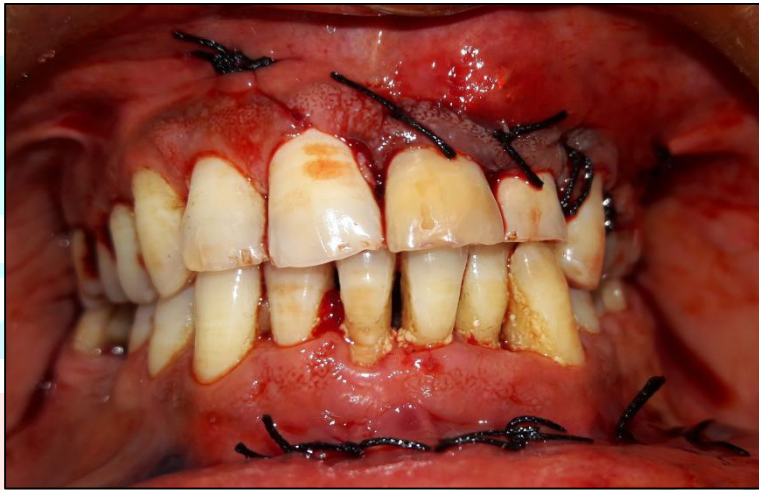

Fig.9 Immediate post operative showing closure of both recipient & host graft sites

HARVESTING FOR SYMPHYSIS GRAFTING: It is suggested that at least 5 mm bone is maintain below the teeth apices, inferior border and bilaterally anterior to mental foramina. After the symphysis has been exposed and the mental foramina are located, the clinician measures the defect to determine the size of bone block(s) required. This measurement can be performed with a simple caliper or templates, or by molding bone wax into the recipient site.

For particulate type of bone harvest a trephine is used to drill so that graft material obtained in an cylindrical segment. For particulate grafting either trephine drill or alternatively osteotome using chiesel and mallet method can be used. A 4.0 mm trephine drill bur at a 50,000 RPM is used 4-5 mm below bone apices for penetration through buccal cortical bone without damaging soft tissue and mental nerve. in this way a cylindrical segment of graft is obtained closure is done after control of bleeding.

Block type bone harvest, overall dimension of graft should be 2 to 3 mm larger than the actual dimension of graft needed at recipient site. This is done to allow space for contouring the graft after harvested so it should allow snug fit after contoured into recipient site. A surgical bur with straight handpiece at 50,000 RPM is used along with copious irrigation it can be either harvested using only bur or a trephine is made or drill are placed which later joined using osteotome to harvest symphysis bone graft, after bone graft obtained. Appropriate allogeneic or alloplastic graft material can be packed into the donor site to restore the defect, and a resorbable collagen membrane can then be placed over the graft material, if desired.

DISCUSSION :- Radicular cyst, also known as periapical cyst, periodontal cyst, root end cyst, or dental cyst, originates from malassez epithelial cell rests in the periodontal ligament due to inflammation ,due to pulp necrosis or trauma. Radicular cysts, with an incidence of 0.5-3.3% of the total number in both primary and permanent dentition.(5)

Prevalence of the radicular cysts in the maxilla is 60% as compared with mandible, and is associated with buccal or palatal enlargement.(6)

In our case location was anterior maxilla , and was associated with palatal enlargement which was similar with review literature.

Radicular cyst pathogenesis was described as comprising three distinct phases: the initiation phase, the formation phase and the enlargement phase. Radicular cysts are usually asymptomatic ,unless episode of acute ex-cerebration occur. Associated teeth are always non-vital and may show discoloration(5) .In our case both 21,22 involved were non vital whereas tooth discolouration was seen with 21.

The radicular cyst has been identified as inflammatory because it is a result of pulpal necrosis following caries in most cases, with an associated inflammatory periapical reaction.The pathogenesis of radicular cysts has been described as comprising of three distinct phases: the phase of initiation, the phase of cyst formation and the phase of enlargement.Although the associated teeth usually show no root resorption, there may be smooth resorption of root apices(3). The given case report shows blunting of apex is seen i.e. Root Resorption I.r.t. 21.

The recommended treatment option available for radicular cyst is the conventional endodontic approach combined with decompression or surgical enucleation of a cyst with extraction of the

offending tooth. Some authors are of the view that suspected radicular cysts must be totally enucleated surgically to remove all epithelial remnants.(6)

Cystic cavity remained after removal of cyst can be augmented using various grafts & guided tissue regeneration with autogenous bone graft remains the gold standard to improve bone augmentation. Autogenous bone is typically harvested from the chin, mandibular ramus, tibia, iliac, or calvaria. The advantages of using this graft is that it contains living cellular elements that enhance bone growth and is completely biocompatible.(7)

Hammack et al. concluded that the cortico-cancellous nature of the symphysis site harvested bone promotes faster vascular growth once the block is mounted, resulting in faster assimilation and less possibility of resorption during healing. Neiva et al. in his study showed that block size available from intraoral location has been found to be an average of 10 mm (height) × 15 mm (width) × 6 mm (thickness), with an average bone volume of approximately 860 mm.(8)

Bone harvested from the mandibular symphysis is mainly cortical in nature, allowing application of rigid fixation in situ and thus providing good primary stability. These grafts can be easily carved to intimately fill in defects and provide good alveolar contour. Fixed onlay grafts also avoid the potential migration that can be encountered with particulate bone grafts.(9) Bernhard Pommer et al. Concluded that the chin bone should be harvested at least 8mm below the tooth apices with a maximum harvest depth of 4mm so as to avoid injury to mandibular incisive canal.(10)

CONCLUSION :- The treatment protocol of radicular cyst ranges from non-surgical, endodontic treatment to a surgical treatment via cyst decompression or enucleation followed by apicectomy or simply extraction of offending tooth followed by curettage. We recommend non-surgical treatment for small lesions where as moderate to large lesion enucleation & apicectomy followed by augmentation of cystic cavity with autogenous bone graft should be done for rapid integration and less potential resorption during healing. This case report shows successful presentation of surgical management of radicular cyst by enucleation & apicectomy followed by augmentation using autogenous bone graft harvested from symphysis.

REFERENCES :-

- 1) Dr. Kumar Nilesh, Dr. Anuj S Dadhich, & Dr. Pramod R Chandrappa ,unusually large radicular cysts of maxilla : Steps in diagnosis & review of management ,J.Bio.Innov4(1),pp:01-11,2015.
- 2) Gaurav Vidhale et al., Management of Radicular Cyst Using Platelet-Rich Fibrin & Iliac Bone Graft - A Case Report ,Journal of Clinical and Diagnostic Research. 2015 Jun, Vol-9(6): ZD34-ZD36.
- 3) Dexter Brave, Madhusudan A.S, Gayathri Ramesh, V.R Brave ,Radicular cyst of anterior Maxilla ,international journal of dental clinics 2011:3(2):16-17 .
- 4) Dr. Chanchal Singh, Dr. Tina Agarwal and Dr. Sonal Gupta ,Surgical and supportive management of radicular cyst with palatal perforation: A case report ,International Journal of Applied Dental Sciences 2017; 3(2): 224-227.
- 5) Harshitha KR, Varsha VK, Deepa. C ,Radicular cyst: A case report ,International Journal of Applied Dental Sciences 2015; 1(4): 20-22.
- 6) Deshmukh J,Shrivastava R, Bharath KP,et al ,Giant radicular cyst of the maxilla ,BMJ Case Rep 2014. doi:10.1136/bcr-2014-203678.
- 7) J.M.P. Camargo, T. Braga, R. Camargo et.al,Surgical management of a large radicular cyst using modified guided tissue regeneration techniques: a case report with 4 years follow-up ,Oral Surgery 12 (2019) 323-331.
- 8) Nermine Ramadan ,Symphysis onlay bone grafting for horizontal maxillary alveolar ridge augmentation: a systematic review ,Dent Oral Craniofac Res, 2015 ,Volume 1(6): 172-177 ,doi: 10.15761/DOCR.1000139.
- 9) Andre Montazem, David V. Valauri et.al. ,The Mandibular Symphysis as a Donor Site in Maxillofacial Bone Grafting: A Quantitative Anatomic Study ,J Oral Maxillofac Surg ,58:1368-1371, 2000.
- 10)Pommer B,Tepper G, Gahleitner A, Zechner W,Watzek ,G. Newsafety margins for chin bone harvesting based on the course of the mandibular incisive canal in CT. Clin. Oral Impl.