

# Comparison of Genetic tool of Dermatoglyphic Patterns in Diabetic and Non- Diabetic Individuals.

Sharmila. D<sup>\*1</sup>, Dharmarajan. P<sup>2</sup>, Umesh .G<sup>3</sup> and N. Jothi Narendiran<sup>1</sup>

<sup>1</sup>PG & Research Department of Advanced Zoology and Biotechnology,  
Government Arts College (Autonomous), Nandanam, Chennai – 600 035.

<sup>2</sup>Institute of Diabetology, Madras Medical College(MMC), Chennai-600003.

<sup>3</sup>Department of Psychiatry, Ponnaiyah Ramajayam Institute of Medical Sciences.  
Chennai-603102.

## Abstract

Dermatoglyphics has proved to be very useful tool used for identification of many gene-linked abnormalities and diseases. The aim of this study was to compare the differences in the finger print patterns in type II diabetic mellitus with non-diabetic control group. This study included totally 400 patients of both sex normal and type II diabetic mellitus patients. All the patients were asked and got their palmer dermatoglyphic impression on plain white A4 paper used the ink method .The result obtained from the diabetic and non diabetic patients was more commonly founded in the loop pattern. For that Loop pattern correlated with radial and ulnar loop of non -diabetic males subjects were 45 % found to have radial loop, 21.5% were found to have ulnar loop, and the females non diabetic subjects were 28.6% found to have radial loop, 21.3% were found in ulnar loop. Radial loops were found the predominant digital pattern in non- diabetic males as well as females. Diabetic patients loop pattern correlated with radial and ulnar loop of males subjects were 19.41% found to have radial loop ,42.4% were found to have ulnar loop, and the female diabetic subjects were 24.05% found to have radial loop ,32.6% were found to have ulnar loop. In both sex diabetic subjects ulnar loop were found to the predominant. Dermatoglyphics provide a simple, inexpensive, anatomical, and non-invasive means of determining the diseases which have a strong hereditary basis and can be employed as a method of screening for diabetes mellitus of high-risk population on early detection, thus reducing the morbidity and mortality.

**Keywords:** Dermatoglyphics, Diabetes mellitus type II, Radial loop, Ulnar loop.

## INTRODUCTION

The term "Dermatoglyphics" was introduced by Cummins.<sup>(1)</sup>The analysis of dermal ridges and their configurations by studying prints of them is called Dermatoglyphics.<sup>(2)</sup>Dermatoglyphics is the study of epidermal ridges and their configurations. The term dermatoglyphics arrived from ancient Greek word; derma = "skin," glyph = "carving" is the scientific study of fingerprints.<sup>(3)</sup>Dermatoglyphics is one of the upcoming branches of medical science where the dermal ridge patterns are studied and used in prediction of genetic disorders for diagnosis of twins, questioned paternity and other hereditary disorders .The formation of ridges takes place at an early stage in fetal life, beginning at the 3rd month of intrauterine life and continuing till the 4th month. Growth disturbances in the fetus at this crucial time distort the alignment at ridges when hands and/or feet are involved.<sup>(4)</sup>

Diabetes mellitus, or simply diabetes, is a metabolic disorder in which a person has high blood glucose level, either because the pancreas does not produce enough insulin, or because cells do not respond to the insulin that is produced.<sup>(5)</sup>There are two major forms of diabetes mellitus. Type I (or insulin-dependent) diabetes, the beta cells are progressively destroyed and secrete little or no insulin; injections of exogenous insulin are thus required to sustain the person's life. This form of the disease accounts for only about 10% of

the known cases of diabetes. About 90% of the people who have diabetes have type II (non-insulin-dependent) diabetes, is also called maturity-onset diabetes, it is usually diagnosed in people over the age of 40, and type II diabetes in children is rising (due to an increase in the frequency of obesity), however, these terms are no longer preferred. Type II diabetes develops slowly is hereditary and occurs most often in people who are overweight<sup>(6)</sup> Globally diabetes prevalence is similar in men and women but it is slightly higher in men above 60 years of age and in women at older ages. Early diagnosis and treatment are essential in preventing long-term complications such as retinopathy, neuropathy and nephropathy. Most sufferers are asymptomatic and hence early diagnosis is a problem.<sup>(7)</sup>

Diabetes also gives rise to dire complications if not under control. Since it is a condition with a partial genetic background, one can assume that there might be certain dermatoglyphic findings specific to diabetic patients. Digital finger patterns include various types like loops (ulnar or radial), whorl and arch. Loops have an open end, depending on which they are classified into radial or ulnar. Loops and whorls have a core (centre) whereas arches have no core. Arches have ridges which rise at the centre. The present study is designed to compare the males and females dermatoglyphic patterns of non- diabetic and type 2 diabetic patients belonging to Tindivanam origin.

## **MATERIALS AND METHODS**

Ethical clearance was obtained from the institutional ethical committee at Madras Medical College - Rajiv Gandhi Government General Hospital, Chennai. The fingerprints were obtained by the method as suggested in Home office 1960.<sup>(8)</sup> This particular study is an observational of cross sectional study included totally 400 patients for each 100 patients of males and females non diabetic patients compared with each 100 patients of males and females diabetic patients. The finger prints were collected from the subjects, after clearly explained the nature and purpose of the study. All the patients were asked and got their palmer dermatoglyphic impression on plain white A4 paper used the ink method. In this method ink was applied on the patient's fingers. The prints pattern of the fingers were taken by roll on technique, where the coated fingers were rolled from the one edge of the finger to the other end on a A4 paper.<sup>(9)</sup> The person fingers patterns can be documented on the sheet for further analysis. Each finger print was examined with a hand lens to identify the finger print pattern.<sup>(10)</sup> This ink on the palm can easily be washed off with water. Data collection was done within the period of February 2017 to June 2017 in various places of the rural areas around Tindivanam.

### **The Parameters Studied Were:**

- The digital pattern-loop- ulnar loop/ radial loop/ whorl/ arch

### **Inclusion Criteria**

- Individuals with type 2 diabetes mellitus (30 to 70 yrs) diagnosed as per ADA criteria

### **Exclusion Criteria**

- Type1 diabetes mellitus patients
- Gestational diabetes mellitus patients

### **Other Investigations**

- Family History of diabetes mellitus.
- Blood sugar Fasting & PP.
- Other complications of diabetes mellitus.

## RESULTS

The result obtained from the present study included totally 400 patients(4000 samples)for each 100patients males and females non diabetic patients compared with each 100 patients of males and females diabetic patients were analyzed for the general prevalence of different finger print patterns ,of these non- diabetic males 66.5% were found to have loops patterns, 25.6% were found to have whorls, and 7.9% were found to have arches, and diabetic males 61.81% were found to have loops patterns, 25.45%were found to have whorls, and 12.74% were found to have arches (figure- 1)(Table-1).The result obtained from the non –diabetic females patients of these 49.9% were found to have loops patterns, 32.6% were found to have whorls ,and17.5% were found to have arches ,and diabetic females 56.65% were found to have loops patterns,33.63% found to have whorls, and 9.72 % were found to have arches. (Figure- 2) (Table-1)

Diabetic (males and females) and non diabetic (males and females) loop pattern was more commonly found loops pattern, correlated with radial and ulnar loops of non diabetic (males and females) males subjects were 45 %found to have radial loops, 21.5% found to have ulnar loops, and females non diabetic subjects were 28.6% found to have radial loops, 21.3% were found in ulnar loops. Radial loops were found the predominant digital pattern in non- diabetic males as well as females. (Figure- 3) (Table-2) Diabetic loop pattern correlated with radial and ulnar loops of (males and females) male subjects were 19.41% found to have radial loops 42.4% were found to have ulnar loops and the female diabetic subjects were 24.05% found to have radial loops 32.6% were found to have ulnar loops .In both sex diabetic subjects ulnar loop were found to the predominant. (Figure- 4) (Table-2).

**TABLE – 1**

### PERSENTAGE OF FINGER PRINTS PATTERNS IN NORMAL & DIABETICS SUBJECTS

<b>GROUPS/PATTERNS</b>	<b>LOOPS</b>	<b>WHORLS</b>	<b>ARCHES</b>
<b>NON-DIABETIC MALE</b>	<b>66.5%</b>	<b>25.6%</b>	<b>7.9%</b>
<b>DIABETIC MALE</b>	<b>61.81%</b>	<b>25.45%</b>	<b>12.74%</b>
<b>NON-DIABETIC FEMALE</b>	<b>49.9%</b>	<b>32.6%</b>	<b>17.5%</b>
<b>DIABETIC FEMALE</b>	<b>56.65%</b>	<b>33.63%</b>	<b>9.72%</b>

TABLE – 2

COMPARISON OF LOOP GROUP FINGER PRINTS PATTERNS IN NORMAL & DIABETICS SUBJECTS

LOOP → RADIAL LOOP + ULNAR LOOP

GROUPS	LOOPS	RADIAL LOOPS	ULNAR LOOPS
NON-DIABETIC MALE	66.5%	45%	21.5%
DIABETIC MALE	61.81%	19.41%	42.4%
NON-DIABETIC FEMALE	49.9%	28.6%	21.3%
DIABETIC FEMALE	56.65%	24.05%	32.6%

FIGURE - 1

CHART SHOWING COMPARISON OF NON-DIABETIC MALE & DIABETIC MALE SUBJECTS

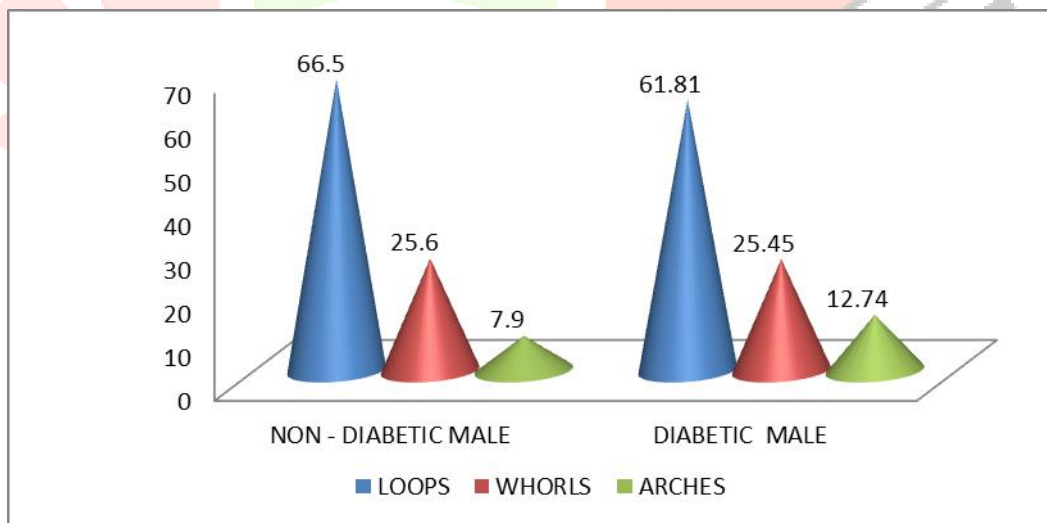


FIGURE - 2

CHART SHOWING COMPARISON OF NON-DIABETIC FEMALE & DIABETIC FEMALE SUBJECTS

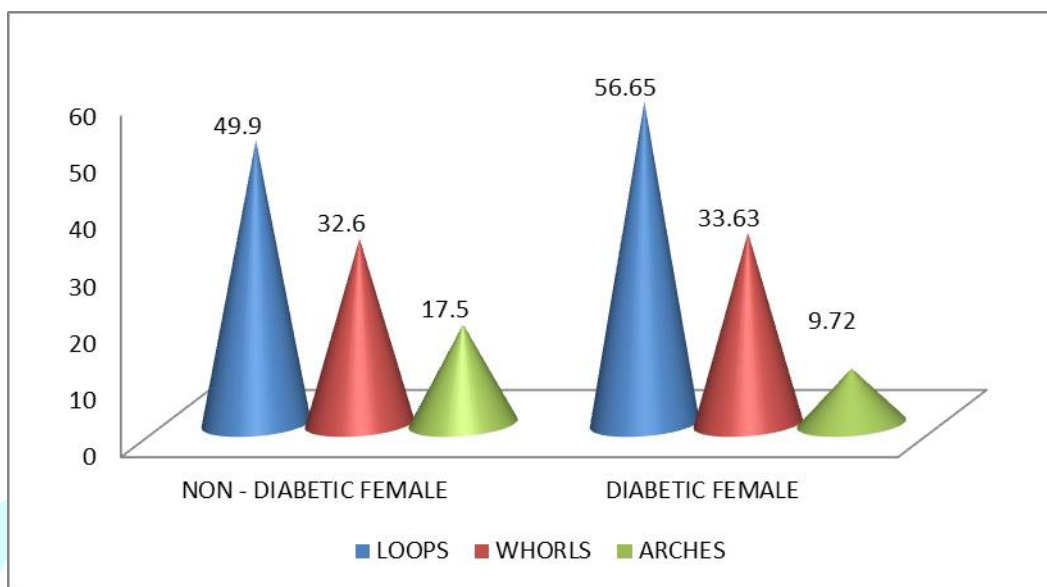


FIGURE 3

LOOP PATTERNS CORRELATED WITH RADIAL & ULNAR OF DIABETIC & NON-DIABETIC MALE SUBJECTS

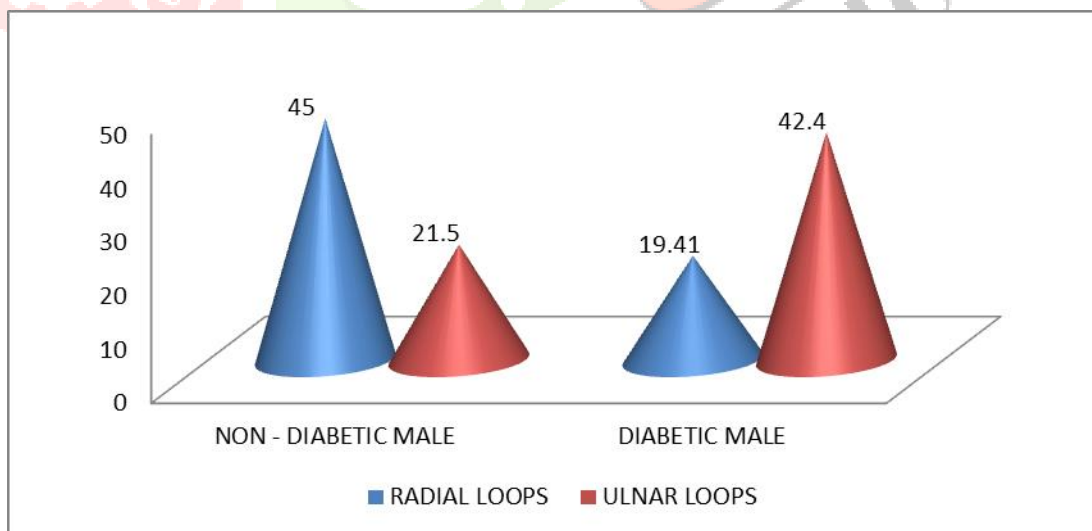


FIGURE 4

LOOP PATTERNS CORRELATED WITH RADIAL & ULNAR OF DIABETIC AND NON-DIABETIC FEMALE SUBJECTS

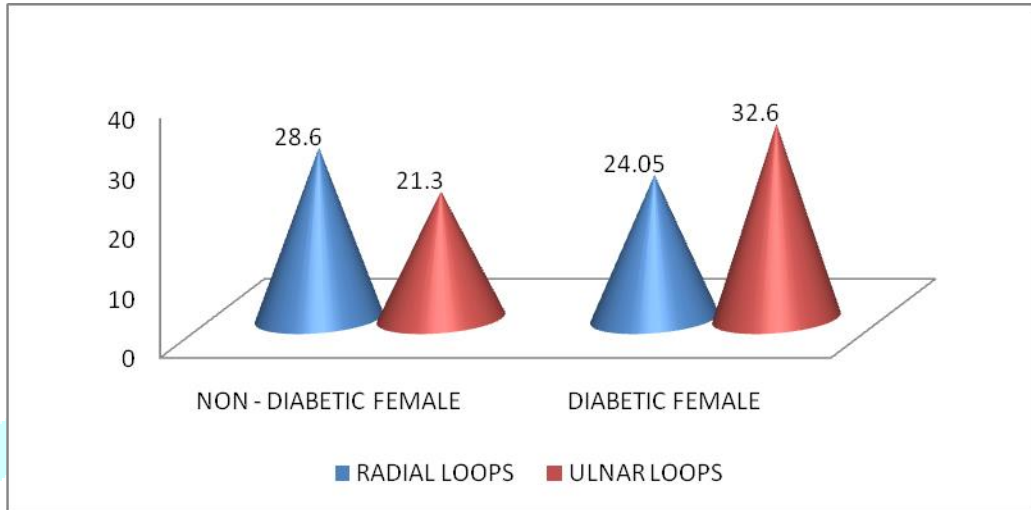
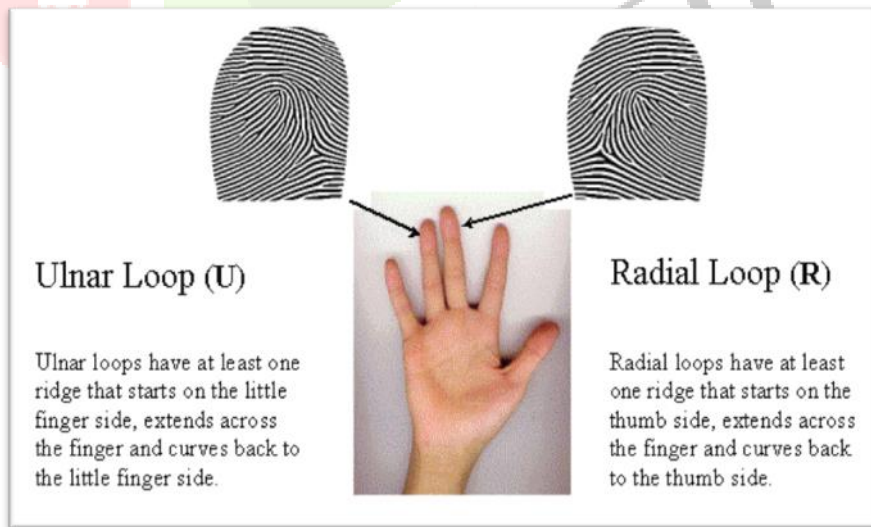


FIGURE -5

ULNAR LOOP Vs RADIAL LOOP





## DISCUSSION

Dermatoglyphics is the study of the epidermal ridge configuration on fingers and toes of palms and soles. As mentioned earlier, it represents the genetic makeup of an individual and is easily recordable. The procedure of recording epidermal ridge configurations is simple, non-invasive and inexpensive. Diabetes Mellitus Type II is a disease with an established genetic background and hence it is safe to assume that there might be significant dermatoglyphic findings in such cases. Several studies done in different regions have significantly identified correlation between different fingerprint patterns and diabetes; however the type of pattern identified varies from one region to another. Therefore, a more population and disease specific study may be required to confirm the value of dermatoglyphics in early diagnosis of diabetes mellitus. Study of finger print pattern is part of Dermatoglyphics and its association with Type 2 diabetes is one of the current research areas. Hence, this parameter is useful for pre-detection of diabetes by dermatoglyphic studies

In a study by Burute P et al. conducted in Maharashtra, India, it was noted that there was a significantly higher frequency of arches and lower frequency of whorls in female diabetics than controls. It was also noted that there was an increase in the frequency of ulnar loops in both males and females of the diabetic group however; the difference was not statistically significant.<sup>(11)</sup>

In a study by Sant et al. it was noted that the frequency of whorls was increased and frequency of ulnar loop was decreased in both hands of male and female diabetic patients and both findings were significant.<sup>(12)</sup> In another study by Eberechi et al. conducted in Nigeria, Africa, it was observed that the diabetic subjects had significantly higher frequency of ulnar loops.<sup>(13)</sup>

Ravindranath et al. recorded that there was a statistically significant increase in the frequency of ulnar loops in both males and females especially on the left hand of female diabetic patients.<sup>(14)</sup>

In the present study there was increases frequency of loop pattern in both sex of diabetics and non-diabetics patients. A especially frequency of ulnar loops found in both males and females diabetic patients and radial loop were found in both sex of non –diabetic patients. The findings of the present study are comparable to those of Ravindranath et al. and Eberechi et al.

## CONCLUSION

The study was conducted in a small population comprised of patients hailing from the rural areas in and around Tindivanam. Dermatoglyphics provide a simple, inexpensive, anatomical, and non-invasive means of determining the diseases which have a strong hereditary basis and can be employed as a method of screening for diabetes mellitus of high-risk population on early detection, thus reducing the morbidity and mortality.

This study would be helpful to formulate counseling messages based on dermatoglyphic pattern prevalent among young generation and their possible stimulation to determine the young people's likelihood to develop diabetes in their later age. It can be used for mass screening program for prevention of DM.

## REFERENCE

1. Pathan F K J, Hashmi R N( 2013). Variations of Dermatoglyphic Features in Non Insulin Dependent Diabetes Mellitus. International Journal of Recent Trends in Science And Technology.; 8(1):16-19.
2. Cummins H. (1929). Revised methods of interpretation and formulation of palmar dermatoglyphics. American Journal of Physical Anthropology.; 12: 415-502.
3. Schaumann B, Alter M. (1976). Dermatoglyphics in Medical Disorders. New York: Springer Verlag; Berlin; 27: 871.

4. Panda M, Chinara PK, Nayak AK. (2004). Dermatoglyphics in diabetes mellitus. *J Anat Soc India*;53:3366.
5. Gardner, D.G. (2011). *Greenspan's basic & clinical endocrinology*. New York. McGraw- Hill Medical. PP:9-17.
6. Fox, S.I. (2003). *Human Physiology*. 8th edition. McGraw-Hill Companies. pp: 615-617.
7. Ana Tarca. (2006). Dermatoglyphics in Diabetes Mellitus Of Type 2 (T2DM) or Non-Insulin dependent. *J Preventive Med.*; 14:60-70.
8. Home Office (1960). *Instructions in the Method of Taking Finger and Palm Prints*. London, H.M.S.O.
9. Cummins H., & C. Midlo. (1961). *Fingerprints, Palms and Soles, an Introduction to Dermatoglyphics* 2nd edition (New York: Doves Publications Incorporated) pp: 121-124.
10. Babler W.J (1991). Embryonic development of epidermal ridges and their configurations. *Birth Defects Original Article Series*. 27:95-112.
11. Burute P, Kazi SN, Vatsalaswamy and Arole V (2013). Role of Dermatoglyphic Fingertip Patterns in the prediction of Maturity Onset Diabetes Mellitus (Type II). *Journal of Dental and Medical Sciences*, 8(1), 1-5.
12. Sant SM, Vare AM, Fakhruddin S. (1983). Dermatoglyphics in diabetes mellitus. *Journal of Anatomical Society of India*, 35(1), 129-132.
13. Eberechi UD, Gabriel S O and Peter DO (2012). A comparative study of the digital pattern, position of triradii, b-c and a-d palmar distances of diabetic subjects and essential hypertensive individuals in River state. *International Journal of Advanced Biotechnology and Research*, 3(2):615-620.
14. Ravindranath, R. and Thomas, I.M. (1995). Finger ridge count and finger print pattern in maturity onset diabetes mellitus. *Ind J Med Sci*; 49(7): 153-156.