



INTERNATIONAL JOURNAL OF CREATIVE RESEARCH THOUGHTS (IJCRT)

An International Open Access, Peer-reviewed, Refereed Journal

Rhinosporidiosis Presenting As An Oropharyngeal Mass: A Clinical Plight ?

Dr. Bhavin Shah

Consultant ENT and Head & Neck Surgeon

Department of ENT

Matoshree Gangubai Shambhaji Shinde Hospital Thane.

(Platinum Group of Hospital Pvt.Ltd)

present case.

Abstract

Rhinosporidiosis, is a chronic granulomatous disease presenting as a polypoidal mass in the nasal cavity and nasopharynx caused by *Rhinosporidium seeberi* and is endemic in India and Sri Lanka. Diagnosis is mainly by clinical observations and is confirmed by histopathology. We report a case of atypical rhinosporidiosis that presented as an oropharyngeal mass and mimicked chronic tonsillitis. Hence possibility of this atypical rhinosporidiosis should be included in the clinical differential diagnosis of any posterior oral or oropharyngeal mass, particularly when managing patients from rural endemic areas.

Key words: Naso-oropharyngeal rhinosporidiosis, oropharyngeal mass, rhinosporidium seeberi

INTRODUCTION

Rhinosporidiosis (RS) is a chronic, noncontagious sporadic disease caused by *Rhinosporidium seeberi*.^[1,2] It is a cosmopolitan disease of human and domestic animals, prevalent in hot tropical climate of endemic zones like India, Sri Lanka, East Africa, parts of America and also encountered among expatriate population in the West.^[3,4] Water and soil are the main reservoirs of infection and the endospores are transmitted through water and dust into the nasal mucosa by traumatic inoculation where they mature subepithelially and after maturation burst with release of sporangia into the tissues.^[5] RS is characterized by a reddish, friable, polypoidal, hyperplastic mass mostly occurring in the nasal cavity and nasopharynx, however, sporadic occurrence in extra nasal sites is also observed.^[6] The latter appearance may pose a diagnostic challenge to the clinician, as documented in the

CASE REPORT

A 28-year-old male patient hailing from rural background presented to the dental out-patient department with a chief complaint of difficulty in swallowing and a foreign body sensation in posterior part of tongue and throat with occasional cough since 6 months [Figure 1]. Intraoral examination revealed a pinkish red lobulated mass in the lateral wall of oropharynx, behind the faucial pillar on the right side. It had yellowish white dotted spots on the surface, which was nonpulsatile and did not bleed on physical examination [Figure 2]. Medical history was normal without any systemic symptoms, nasal obstruction, discharge, or epistaxis. Local examination revealed no abnormality in the nasal cavity. The lesion was provisionally diagnosed as chronic follicular tonsillitis and antibiotic regimen of amoxicillin and clavulanic acid (625 mg, TID) was started. The patient reported back after 1 week with no regression of symptoms despite therapy. The following differential diagnosis were considered: nasopharyngeal angiofibroma, vascular polyp, nasopharyngeal carcinoma and mycotic granuloma, and incision biopsy of the oropharyngeal mass was performed, which revealed numerous stromal double-walled sporangial cysts containing endospores in different developmental stages, present below a stratified squamous epithelium and surrounded by polymorphonuclear leukocytes and eosinophils [Figure 3]. Hence a final diagnosis of RS was made. On contrast magnetic resonance imaging (MRI) of the face and neck, a large lobulated soft tissue mass showing intense enhancement in right nasal cavity, nasopharynx and oropharynx, extending to the anterior surface of epiglottis, with fluid accumulation in right maxillary sinus was observed [Figures 4 and 5]. Endoscopic sinus surgery was performed and the mass was excised. The gross

specimen was in the form of elongated, polypoidal soft friable mass measuring 7.5×4.5 cm, with one surface appearing whitish, smooth and mucoid and other surface in the form of fungating exophytic verrucous growth

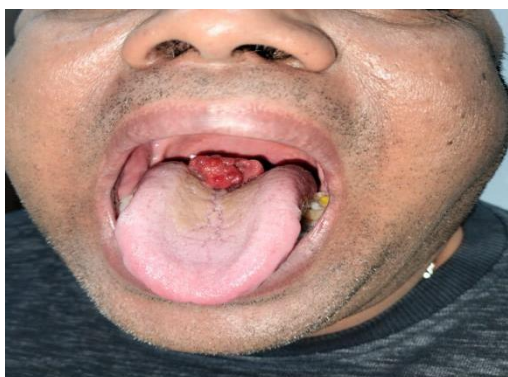

Figure 1: Extraoral patient photograph.

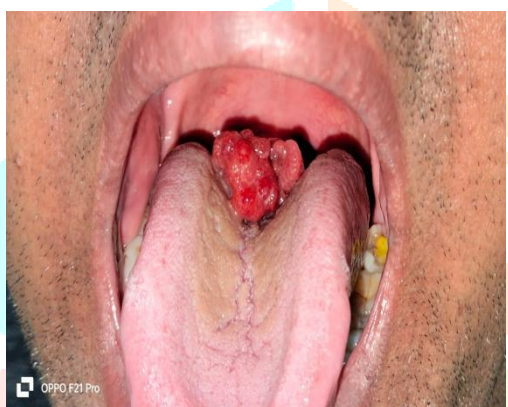

Figure 2: Intraoral mass in right tonsillar and lateral pharyngeal wall with yellow flecks on surface.

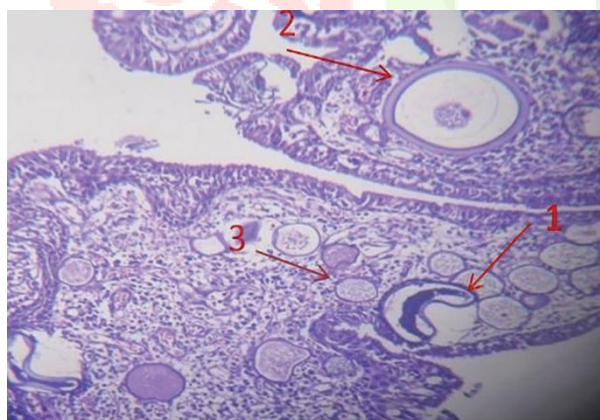


Figure 3: Globular cysts showing developmental stages of *R. seeberi* in rhinosporidial tissue. 1 - mature sporangium with surrounding cell infiltrate. 2 - Intermediate sporangium, 3 - juvenile sporangium (H and E stain, $\times 4$).

Small yellowish nodules measuring 2-5 mm were seen scattered on the surface. The microscopic features were in accordance with earlier diagnosis. Periodic acid schiff (PAS) stained sections revealed conspicuous sporangia in a fibromyxoid stroma [Figure 7]. Additionally, transepithelial elimination of sporangia and giant cells were observed [Figure 8]. Postoperatively, the patient was started on dapsone (diaminodiphenylsulphone, 100 mg, OD) and is

now on a 2-month follow up without recurrence.

DISCUSSION

RS, although infective but not infectious, is hyperendemic in the following states in India: Tamil Nadu, Kerala, Odisha, West Bengal, and Chattisgarh.^[4,7] The exact nature of the *Rhinosporidium* is not known and is controversial.^[7] Presently, *Rhinosporidium seeberi* is classified in a new DRIP clade (*Dermatocystidium*, *rosette agent*, *ichthyophonus*, and *psorospermium*), which includes fish and amphibian pathogen.^[8] RS is common among sand workers, paddy cultivators, and people bathing in stagnant muddy water.^[1] In fact our patient did give a history of bathing in pond water. Previously, 4 out of 16 cases have indicated pond bathing history.^[4] Trauma or abrasion in skin or mucous membrane aids the organism to gain access into the tissues. RS commonly involves the nasal cavity, anterior part of nasal septum, nasal vestibule, and nasopharynx with an age predilection of 15-40 years. The male to female ratio of RS is 4:1.^[6] The chief clinical manifestations are bleeding polyp, nasal stuffiness, discharge, and difficulty in breathing. Other sites of involvement may include lip, palate, uvula, conjunctiva, larynx, trachea, penis, vagina, bone, ear, scalp, skin, etc. The diagnosis of RS is delayed when extranasal sites are involved.^[9,10] Hence taking a proper occupational and personal history is imperative. RS occurring as an oropharyngeal mass has to be differentiated from other entities. Previously, six cases that presented as a visible oropharyngeal mass were confused with juvenile angiofibroma and antrochoanal polyp.^[3] Chronic follicular tonsillitis may mimic oropharyngeal RS due to site of occurrence, symptoms of dysphagia, chronic irritation in throat and yellow beads of pus on surface. However, the tonsils and lymph nodes are enlarged in the former and lacks nasopharyngeal connection.^[11] Nasopharyngeal angiofibroma, which is also a vascular tumor-like lesion occurring in the nasopharynx may extend into the oral cavity and also simulate RS both clinically and radiologically.^[3] However, nasal obstruction and epistaxis are commonly present in the former, it is very destructive and extends into the paranasal sinuses with anterior bowing of posterior wall of the maxillary sinus. Lack of maxillary sinus extension also helps to distinguish RS from polyps and papillomas.^[4] Nasopharyngeal carcinoma due to its location has to be differentiated from RS by its destructive nature, rapid course, occurrence of pain, nerve symptoms, presence of firm or hard cervical nodes, and/or presence of metastasis at the time of diagnosis. Other mycotic granulomas may resemble RS if they occur in a similar location but they usually occur in the immunocompromised individuals and histopathological examination is discriminatory.^[12] Contrast computed tomography (CT) scan is done to delineate extent of the lesion, in which it appears as a lobulated, moderately to minimally enhancing soft tissue mass.^[4]

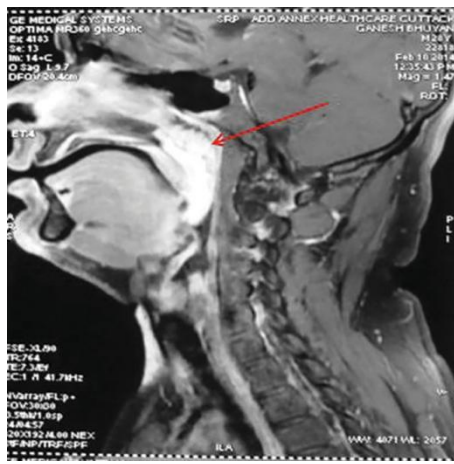

Figure 4: Sagittal section of MRI showing hyperintense mass (arrow) in nasal cavity, nasopharynx and oropharynx. (column width)

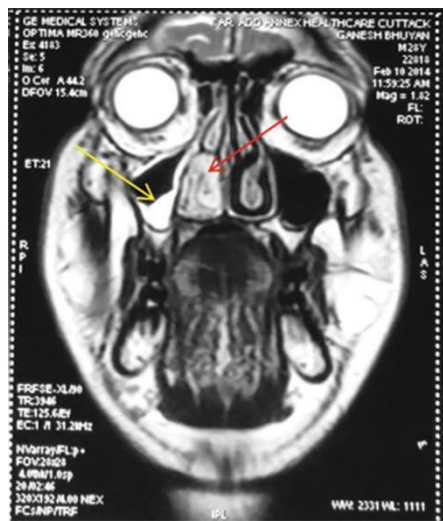


Figure 5 : Coronal MRI section depicting hyperintense mass in right nasal cavity (red arrow) and fluid accumulation in right maxillary sinus (yellow arrow). (column width)

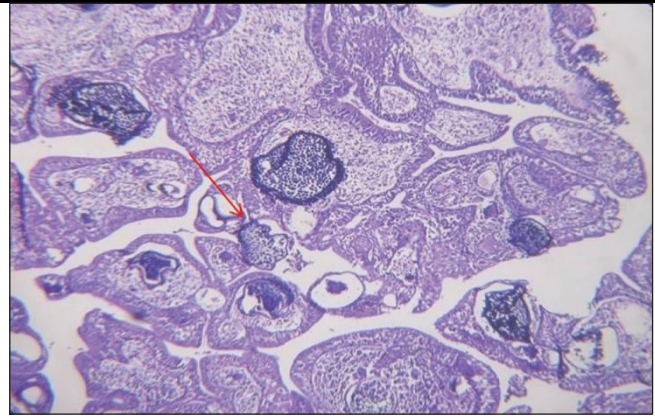


Figure 7 : Late stage of transepidermal elimination of mature sporangia into the tissues (arrow) (H and E stain, $\times 4$). (column width)

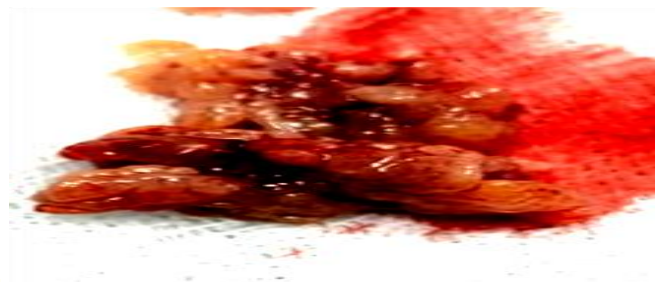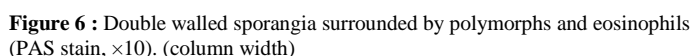


Figure 8 : Excised polypoidal gross specimen

We used contrast MRI to demarcate the extent and it appeared as an intensely enhancing lesion in the respective area, which may be due to the rich vascularity of RS. MRI study of sinonasal malignancy gives a heterogenous appearance with necrosis while inverted papillomas give a cerebriform appearance.^[4]

RS microscopically manifests as subepithelial thick walled, globular cysts, or sporangia with numerous daughter spores in different developmental stages. In 10 days, the endospores form sporangium after passing through trophozoite stage.^[5] They can be visualized by routine hematoxylin and eosin staining and also by methenemine silver and PAS stains. There is granulation tissue in surrounding connective tissue containing lymphocytes, plasma cells, focal collection of histiocytes, and also neutrophils. Pseudocystic abscess formation, granulomatous reaction and fibrosis have also been described.^[7] Transepidermal elimination of RS sporangia is a part of nonspecific defense reaction of the body to expel them and was observed in our case.

The mainstay of treatment is surgical excision. Limited excision with cauterization at base of the lesion is preferred as radical surgery may lead to perforation, hemorrhage, increased recurrence, and dissemination.^[1] However, those with oropharyngeal extension may require more extensive approach. Dapsone is a promising drug that is used as an adjunct to surgery as it arrests the maturation of sporangia and promotes fibrosis.^[13]



CONCLUSION

RS remains an enigmatic disease with some queries pertaining to the mode of infection, mechanism of spread, immune reaction, histopathological aspects, and significance of transepithelial elimination of the sporangia. In this age of travel, it is an emerging infective disease notorious for its high rate of recurrence. Dental surgeons may encounter atypical cases of RS, which need to be diagnosed, managed, and their clinical course followed with care.

REFERENCES

1. Nair A, Manjula B, Balasubramanya A, Nayar R. Endoscopic removal of Naso-Oropharyngeal Rhinosporidiosis: A Report. *Indian J Otolaryngol Head Neck Surg* 2005;57:354-6.
2. Babu S, Anuradha A, Chandra S, Kashyap B. Nasal Rhinosporidiosis with Oropharyngeal extension. *Ann Nigerian Med* 2011;5:24-7.
10. Shailendra S, Prepageran N. Oropharyngeal Rhinosporidiosis in a Migrant Worker — A Delayed Presentation. *Med J Malaysia* 2008;63:65-6.
11. Prasad K, Veena S, Permi HS, Teerthanath S, Padma Shetty K, Shetty JP. Disseminated Cutaneous Rhinosporidiosis. *J Lab Physicians* 2010;2:44-6.
12. Dhingra PL, Dhingra S. Diseases of ear, nose and throat. 5th ed. Amsterdam, Netherlands: Elsevier; 2013.
3. Saha J, Basu AJ, Sen I, Sinha R, Bhandari AK, Mondal S. Atypical Presentations of Rhinosporidiosis: A Clinical Dilemma? *Indian J Otolaryngol Head Neck Surg* 2011;63:243-6.
4. Prabhu SM, Irodi A, Khiangte HL, Rupa V, Naina P. Imaging features of Rhinosporidiosis on contrast CT. *Indian J Radiol Imaging* 2013;23:212-8.
5. Arseculeratne SN. Microcystisaeruginosa as the causative organism of rhinosporidiosis. *Mycopathologia* 2000;151:3-4.
6. Von Haacke NP, Mugliston TA. Rhinosporidiosis. *J Laryngol Otol* 1982;96:743-50.
7. Arseculeratne SN. Recent advances in rhinosporidiosis and
8. rhinosporidiumseeberi. *Indian J Med Microbiol* 2002;20:119-31.
9. Herr RA, Ajello L, Taylor JW, Arseculeratne SN, Mendoza L. Phylogenetic analysis of *Rhinosporidiumseeberi*'s 18Ssmall subunit ribosomal DNA groups this pathogen among members of the protactistan Mesomycetozoa clade. *J Clin Microbiol* 1999;37:2750-4.
13. Neville BW, Damm DD, Allen CM, Bouquot JE. Oral and Maxillofacial Pathology. 2nd ed. Philadelphia: Elsevier; 2007.
14. Nair KK. Clinical trial of diaminodiphenylsulfone (DDS) in nasal and nasopharyngeal rhinosporidiosis. *Laryngoscope* 1979;89:291-5.

