



CONOMETRICS – A NO SCREW, NO GLUE TECHNIQUE REDEFINING RETENTION IN IMPLANT PROSTHODONTICS – A REVIEW

Authors:

**Dr Pooja Katwate, Dr Ruchi Kasat, Dr Babita yeshwante, Dr Akash Todsam,
Dr Meghana Nelanuthala**

- 1) MDS, student, Department of Prosthodontics, Chhatrapati Shahu Maharaj Shikshan Sanstha's Dental College and Hospital, Kanchanwadi, Chhatrapati Sambhajinagar, Maharashtra.
- 2) MDS Professor and PG Guide, Department of Prosthodontics, Chhatrapati Shahu Maharaj Shikshan Sanstha's Dental College and Hospital, Kanchanwadi, Chhatrapati Sambhajinagar, Maharashtra.
- 3) MDS, student, Department of Prosthodontics, Chhatrapati Shahu Maharaj Shikshan Sanstha's Dental College and Hospital, Kanchanwadi, Chhatrapati Sambhajinagar, Maharashtra.
- 4) MDS student, Department of Prosthodontics, Chhatrapati Shahu Maharaj Shikshan Sanstha's Dental College and Hospital, Kanchanwadi, Chhatrapati Sambhajinagar, Maharashtra.
- 5) MDS student, Department of Prosthodontics, Chhatrapati Shahu Maharaj Shikshan Sanstha's Dental College and Hospital, Kanchanwadi, Chhatrapati Sambhajinagar, Maharashtra

ABSTRACT:

A Cone-in-cone Morse taper connection between abutments and crowns has been proposed to retain implant supported definitive fixed dental prostheses (FDPs). The "Conometric Concept," a prosthetic technique, was applied to preserve zirconia and lithium disilicate (LS2) restorations. In order to keep an implant-supported restoration without the use of screws or cement, the conometric idea involves creating a cone-in-cone relationship between an abutment and the corresponding coping. Prefabricated parts are used to fit the restoration into the abutment. Conical coupling abutments function without cement by utilizing friction between the abutment and the titanium coping to hold a prosthesis in place. A spring-fixed partial denture remover can be used to remove the restoration with ease, as it lacks any access holes. The emergence profile of the restoration can be placed sub-gingivally without the risk of cement remaining at the abutment coping interface. The main objective of this study is to critically review articles that have used conometric concept and to evaluate its clinical effectiveness.

KEYWORDS: IMPLANT-SUPPORTED DENTAL PROSTHESIS; FIXED PARTIAL DENTURE; CONOMETRIC CONNECTION; DENTAL IMPLANT ABUTMENT DESIGN, CLINICAL OUTCOME.

1. INTRODUCTION:

Since the 1960s, when Brånemark is credited with establishing contemporary implantology, the discovery of connections that alleviate marginal bone resorption has spurred research into new developments. Numerous connection kinds, such as conometric, flat-to-flat, platform-matched, anti-rotational, internal or external hexagon, and platform-switching connections, have been proposed. Implants without connections or with connections far from the edge of the bone are also recommended (one-piece implants). Ever since dental implants were first introduced, scientists have worked to maximize their mechanical and biological responses. With relation to the biological effects of dental rehabilitations, the stability of soft and hard tissues becomes important. At the same time, taking care of any mechanical problems is necessary to ensure full success in rehabilitation.

Dental implants and prosthetic superstructures can be connected using one of two methods: cemented or screw-retained. However, from a mechanical and biological point of view, both approaches have inherent drawbacks.

Despite the advantages of cemented restorations, challenges arise due to the need for complete removal of excess cement in the soft tissues surrounding the implant. Studies have demonstrated a strong correlation between residual cement and the onset of chronic peri-implant pathologies, emphasizing the complications linked to excess residual cement. In vitro testing revealed the presence of cement residues in all tested samples, positioned more apically than the margin of the prosthetic crown. From a clinical standpoint, it has been verified that an excess of cement can lead to peri-implantitis. However, the precise role of cement in the aetiology of peri-implant pathologies remains unclear. The literature suggests that cement remnants may act as an irritant for soft tissues, drawing an analogy with tartar in teeth implicated in periodontal disease.

Bacterial plaque has been found to be the etiological agent for peri-implant disorders in human peri-implant mucositis research, emphasizing the restoration of peri-implant tissue health following plaque clearance.

Excess cement in the peri-implant sulcus or an improper prosthetic margin can lead to biological problems. The existence of an access hole for the screw or the difficulty to access the screw itself are examples of mechanical problems related to screw retention. The superstructure may be removed with ease thanks to the screw-type connection, which makes maintenance and repairs while dealing with mechanical issues feasible. However, in order to obtain a passive fit, welding the superstructure addresses displacement of the model and distortion of the impression material, necessitating precision in the production process. The possibility of peri-implantitis or peri-implant mucositis as a result of leftover cement is removed with screw-retained superstructures. On the other hand, in screw-retained prostheses, a poor bond between the abutment and superstructure may directly increase mandibular stress.

Natural teeth can move several dozen micrometres because of the periodontal ligament's pressure variation. On the other hand, the range of motion for prosthetic dentures that are fixed to an implant is reported to be 10 μm or less. It is thought that when there is a little misfit in the implant superstructure, the surrounding tissue is under more stress than it would be in the absence of the tooth, which can result in issues down the road. Research has indicated that an implant-abutment interface mismatch that creates a micro gap may cause micromotion and consequent bone resorption in the surrounding region. Additionally, when there is a misfit between the abutments and superstructures, it can lead to fractures of the superstructures and components. Complications have been documented, including abutment screw loosening and decreased preload. Minimal biological and mechanical complications have been reported when there is no misfit between the implant and the abutment, and a good passive fit is achieved.

It is commonly known that marginal bone level and the health of hard tissues are correlated with, and that the former is a prerequisite for, the latter. If left untreated, mucositis conditions may progress to peri-implantitis, which can cause irreversible damage and even lead to implant loss.

Therefore, the conometric connection was developed in an effort to enhance conventional retention techniques. The frictional force between the coping and abutment is what makes the conometric connection work. An ideal fit between the coping and abutment results in a biological closure of the inner mechanical compartment and good marginal adaptation. By using materials that are produced industrially, the two components are perfectly adapted to one another. Therefore, two of the peri-implantitis etiological factors are eliminated by the presence of a perfect fit between the components and the lack of cementation. As was previously noted, a perfect fit ensures prosthetic retention, but the primary cause is the physical phenomena

of friction between bodies, which describes two bodies that are in close contact and is opposed to reciprocal motion.

The retentive force decreases as the angle between the cone and the perpendicular to the base increases. In other words, a larger angle results in a smaller retentive force. Conversely, if the walls tend towards parallelism, the retention force will be at its maximum. Because this connection is industrial premade, it is ideal for a digital approach. After the exact structure of the abutment is established, a digital procedure may include scanning the spatial position of the abutment. The advancement of technology in computer-guided implant planning, which makes use of 3D radiography and digital scanning, improves the predictability of digitally calculating the angle of implant abutments and makes it easier to apply this knowledge in surgical procedures. The planning of abutment angles and implant locations in guided surgery is made possible by the design software, which results in the achievement of ideal parallelism.

The intersection of conometry and comprehensive digital CAD/CAM is intriguing. Indeed, potential occlusal or marginal discrepancies arising from scanner or software approximation errors might be circumvented during the secondary cementation process. The subgingival placement of the prosthetic margin does not involve an inflammatory risk due to an excess of cement or a gap. SEM analysis of the interface zones between coping and abutment, after the system has been subjected to a load, did not show an appreciable gap; therefore, this entails a lower risk of bacterial colonization. Also, in vitro studies showed that biological sealing avoids bacterial contamination.

The aim of this study is to present a review on the entire concept and importance as well as benefits of conometric connection.

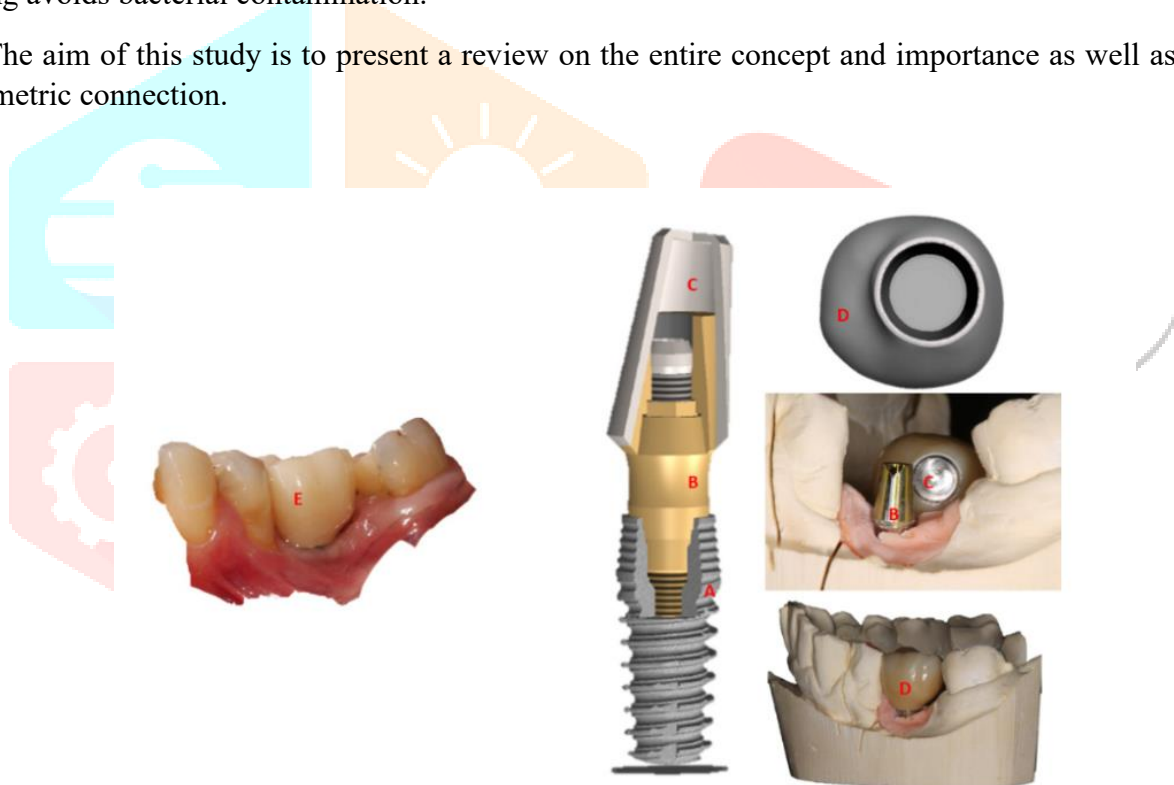


Figure 1. Example of conometric connection diagram. (A) Fixture; (B) Conometric Abutment; (C) Conometric Hood or Coping; (D) Prosthetic Manufact CAD-CAM Project; (E) clinical view

2. MATERIALS AND METHODS:

A manual and electronic search was carried out. The following categories of research were included because there hasn't been much research done on the subject to date: expert opinions, case reports, consensus reports, case series, meta-analyses, systematic reviews, randomized controlled clinical studies, observational studies, and experimental studies on humans, animals, and in vitro. Papers that didn't address the conometric link between the prosthesis and the abutment were not included. A narrative summary of the general findings was produced by extracting and comparing data from publications that were identified as relevant. Among these six common sectors of interest, of which the following were identified as advantages: lack of cement or

screw; marginal adaptation and bacterial sealing; retention force; digital approach; follow-up; and varieties of prostheses.

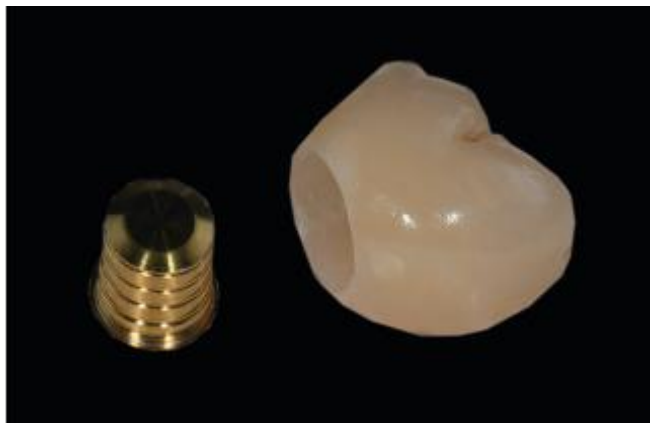

Figure 2: Crown and definitive abutment before cementation.

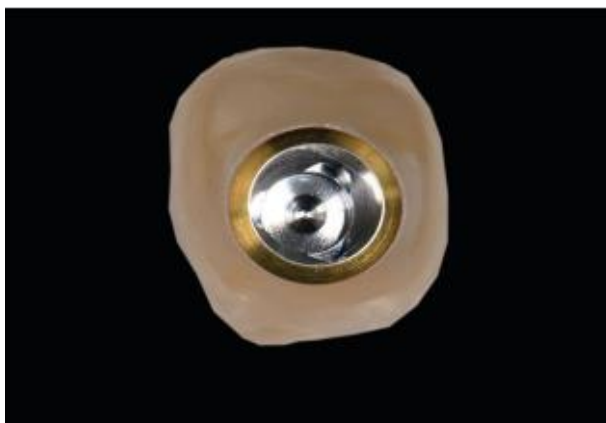


Figure 3: Polished interface between crown and Abutment after cementation.

3.DISCUSSION:

There are certain drawbacks to both screwed and cemented prosthesis. Cemented ones are now commonly used in implant prosthesis restorations. The drawback of cemented restorations, despite its many benefits, is that any excess cement in the soft tissues surrounding the implant structure must be entirely removed. A study showed a direct correlation between the emergence of chronic peri-implant diseases and leftover cement. There have been problems linked to excess leftover cement. One of the possible causes of cement residues in the peri-implant region is the clinical practice of positioning the prosthetic margins subgingivally for aesthetic reasons. This, however, carries with it the risk of an incomplete removal of the cement and, therefore, an iatrogenic damage. An in vitro study showed that it is impossible to clean all the cement surpluses when the margin is placed from 1.5 to 3 mm apically at the margin of the soft tissues. The results of a prospective clinical study showed that more than 80% of prosthetic rehabilitations present an excess of cement, although the operators believed they had performed a meticulous cleaning. In addition to the presence, the characteristics of the cement can also influence the results: resinous-based cements were more difficult to remove from the smooth surface of the implants. Therefore, selective clinical use, in the implant field, of cement with lower adhesive properties was also proposed. In summary, it can be concluded that it is difficult to remove all excess cement after cementation if the margins are located subgingivally. The deeper the position of the margin, the greater the difficulty in detecting excess cement. Only when the margin is visible can all cement residues be removed. Therefore, it was recommended to use individual abutments with clinically visible margins and easily removable cement for the cementation of prostheses or to give preference to screwed prostheses.

Therefore, following these evaluations, the use of a fixed prosthesis with a conometric connection, which does not require cement, could have advantages for clinical management, for the post-operative course, and for the long-term stability of soft and hard tissues.

The only retentive force in a conometric connection is friction, which requires close connections and extreme accuracy to produce. The failure of bacterial infiltration of the artifact is attributed to this excellent adaptation between the coping and abutment. The creation of bacterial plaque may be facilitated by an inadequate adaptation that results in a gap at the level of the conometric connection; this reconfiguration of the microflora may be the primary cause of bacterial inflammation and bone crest resorption.

The biointegrity, the bacteriological seal, and the preservation of the health of the peri-implant tissues are all determined by the internal and marginal modifications of the abutment coping system. Bacteria follow a natural course that starts at the interface level and extends into the deepest parts of the space between the hood and the abutment. Through the use of in vitro microbiological testing, it was shown that the areas inside the prosthetic conometric connection are free of any living or dead bacteria. From this perspective, this can thus

be regarded as a suitable prosthetic element. Despite flat surfaces being in close touch, the marginal area's scanning electron microscopy (SEM) study revealed tiny, punctual micro-gaps (1.67–2.04 μm).

The average gaps between the conometric connections of the systems under analysis range from 2 to 3 μm ; the gap between the prosthetic crown and the hood, on the other hand, is much larger, measuring up to 145 μm . This gap is virtually non-existent, as the prosthetic crown is filled during the cementation procedures.

The literature makes it abundantly evident that when the conometric connection is triggered with a force of 50 N, a perfect seal can be produced. Zirconia has demonstrated its ability to withstand stresses exceeding 1500 N in in vitro experiments.

A sufficient marginal seal is determined by the close contact that occurs when the cap deforms in its most apical portion when subjected to an adequate insertion force. According to research published in the literature, this area does not appear to be large enough for the growth of germs, as long as the hood is fitted correctly to reduce the possibility of an inadequate seal and prosthetic detachment. Extraoral cementation and polishing provide for advantageous control over the prosthesis–soft tissue contact, perhaps mitigating inflammatory aspects. Considering these variables, it can be concluded that marginal adaption and, consequently, a sufficient bacteriological seal are beneficial elements for the health of the implant.

Because this connection type is industrially built, it lends itself well to a digital approach. Using a digital process could enable scanning of the pillar's spatial position once the precise conformation of the abutment is determined. When using guided surgery, the restorer can help plan the implant position by merging the information from the radiograph with the design that was obtained through the scan.

Conometry and full digital CAD/CAM have an intriguing interaction; in reality, during the secondary cementation process, any potential occlusal or marginal inconsistencies caused by approximation errors in the scanner or software are avoided. In contrast to the analogic procedure, the authors of the study by Degidi et al. performed all steps digitally for all patients, resulting in a fixed partial rehabilitation supported by two implants finished with monolithic lithium disilicate. In fact, if there is not enough parallelism between the two implants by more than 25 degrees, which is the compensation limit of angled abutments, cone-in-cone engagement cannot be achieved. Control in all three dimensions of the implant position is essential to achieving a favourable prosthetic outcome.

Digital technology appears to be advantageous in this situation, both for the implant's proper spatial placement and for the eventual completion of the prosthetic. The first factor is essential to achieving a proper engagement and, consequently, a positive therapeutic outcome. It also offers the possibility of designing and implementing specialized abutments that meet the parallelism requirements specified by the clinical scenario. The second entails completing the rehabilitation; this later really accepts potential errors resulting from the CAD/CAM process because of a subsequent cementation; additionally, digital techniques enable the creation of an instant prosthesis.²

4. CONCLUSION:

The type of conometric connection performs well in terms of retentive force, marginal seal, biological inertia, and respect for the peri-implant tissues, according to a thorough study of studies published in the literature. Consequently, inserting the prosthetic edges deeply into the gingival sulcus can improve the rehabilitation's looks. Furthermore, it works well with a digital approach—either totally digital or more conventional. Additional benefits include finishing the prosthesis during the implant placement session and accurately analysing the similarities between the implant abutments and prosthetic structure design in order to create a structure that can be integrated with an intra-oral welded substructure.

Single-element rehabilitation, multiple-element bridges, fixed partial prostheses, and fixed total prostheses were all completed using this kind of connection.

Regarding follow-up, just one study provided medium-term data, while the majority of studies assessed this kind of rehabilitation for brief to medium periods of time. It is crucial to emphasize that long-term follow-up studies are challenging to conduct, but they are essential to better understand the clinical behaviour of this kind of relationship. Furthermore, investigations using dynamic loads in vitro could be carried out to simulate the masticatory stress more accurately.

A limit of this study is the absence of articles in the literature, concerning this topic, with a high level of significance, so only case reports, observational studies, dental techniques, and in vitro experiences have been considered.

REFERENCES

1. Nithyanandham S, Sivaswamy V, Thangavelu L. Evaluation Of The Clinical Effectiveness Of The Conometric Concept-A Systematic Review. *Int J Dentistry Oral Sci.* 2021 Jun 30;8(5):2918-23.
2. Lupi SM, Todaro C, De Martis D, Blasi P, Rodriguez y Baena R, Storelli S. The Conometric Connection for the Implant-Supported Fixed Prosthesis: A Narrative Review. *Prosthesis.* 2022 Aug 16;4(3):458-67.
3. Lupi SM, De Martis D, Todaro C, Isola G, Beretta M, Rodriguez y Baena R. Conometric Connection for Implant-Supported Crowns: A Prospective Clinical Cohort Study. *Journal of Clinical Medicine.* 2023 Dec 13;12(24):7647.
4. Degidi, M.; Nardi, D.; Sighinolfi, G.; Degidi, D. The Conometric Concept for the Definitive Rehabilitation of a Single Posterior Implant by Using a Conical Indexed Abutment: A Technique. *J. Prosthet. Dent.* 2020, *123*, 576–579.
5. Gehrke, P.; Hartjen, P.; Smeets, R.; Gosau, M.; Peters, U.; Beikler, T.; Fischer, C.; Stolzer, C.; Geis-Gerstorfer, J.; Weigl, P.; et al. Marginal Adaptation and Microbial Leakage at Conometric Prosthetic Connections for Implant-Supported Single Crowns: An In Vitro Investigation. *Int. J. Mol. Sci.* 2021, *22*, 881.
6. Degidi, M.; Nardi, D.; Sighinolfi, G.; Piattelli, A. The Conometric Concept: A 5-Year Follow-up of Fixed Partial Monolithic Zirconia Restorations Supported by Cone-in-Cone Abutments. *Int. J. Periodontics Restor. Dent.* 2018, *38*, 363–371.
7. Degidi, M.; Nardi, D.; Sighinolfi, G.; Piattelli, A. The Conometric Concept: Definitive Fixed Lithium Disilicate Restorations Supported by Conical Abutments. *J. Prosthodont.* 2018, *27*, 605–610.
8. Bressan, E.; Stocchero, M.; Jimbo, R.; Rosati, C.; Fanti, E.; Tomasi, C.; Lops, D. Microbial Leakage at Morse Taper Conometric Prosthetic Connection: An in Vitro Investigation. *Implant Dent.* 2017, *26*, 756–761.
9. Albiero, A.; Benato, R.; Momic, S.; Degidi, M. Computer-Aided Crown Design Using Digital Scanning Technology for Immediate Postextraction Single-Implant Restorations Supported by Conical Indexed Abutments. *Int. J. Periodontics Restor. Dent.* 2021, *41*, 135–140.
10. Nardi, D.; Degidi, M.; Sighinolfi, G.; Tebbel, F.; Marchetti, C. Retention Strength of Conical Welding Caps for Fixed Implant-Supported Protheses. *Int. J. Prosthodont.* 2017, *30*, 553–555.
11. Bressan, E.; Lops, D.; Tomasi, C.; Ricci, S.; Stocchero, M.; Carniel, E.L. Experimental and Computational Investigation of Morse Taper Conometric System Reliability for the Definition of Fixed Connections between Dental Implants and Protheses. *Proc. Inst. Mech. Eng. Part H J. Eng. Med.* 2014, *228*, 674–681.
12. Antonaya-Martin, J.; Del Rio-Highsmith, J.; Moreno-Hay, I.; Lillo-Rodríguez, J.; Gomez-Polo, M.; Celemin-Viñuela, A. CAD/CAM Conic Crowns for Predictable Retention in Implant-Supported Protheses. *Int. J. Prosthodont.* 2016, *29*, 230–232.
13. Linkevicius, T.; Vindasiute, E.; Puisys, A.; Peciuliene, V. The Influence of Margin Location on the Amount of Undetected Cement Excess after Delivery of Cement-Retained Implant Restorations. *Clin. Oral Implants Res.* 2011, *22*, 1379–1384.
14. Caricasulo, R.; Malchiodi, L.; Ghensi, P.; Fantozzi, G.; Cucchi, A. The Influence of Implant-Abutment Connection to Peri-Implant Bone Loss: A Systematic Review and Meta-Analysis. *Clin. Implant Dent. Relat. Res.* 2018, *20*, 653–664.
15. Gehrke, P.; Burg, S.; Peters, U.; Beikler, T.; Fischer, C.; Rupp, F.; Schweizer, E.; Weigl, P.; Sader, R.; Smeets, R.; et al. Bacterial Translocation and Microgap Formation at a Novel Conical Indexed Implant Abutment System for Single Crowns. *Clin. Oral Investig.* 2021, *26*, 1375–1389.