



Silent Left Atrial Mass With Lung Cancer: A Suspicious Association And A Challenging Case

Soukaina Kadiri, Mounir Nesnassi, Najat. Mouine, Ilyasse Asfalou, Aatif. Benyass
Cardiology Center, Mohammed V Military Instruction Hospital of Rabat, Mohammed V University, Rabat,
Morocco

Abstract: Diagnosing a mass in the left atrium can be difficult. The most frequent differential diagnoses are primary or metastatic tumors, vegetation, and thrombi. We report a case of a left atrium mass found in a 57-year-old man, with a history of a non-operable squamous cell lung cancer. The control chest scanner showed a defective opacification of the left atrium. The TTE revealed a dilated left atrium with the presence of a large atrial mass. Despite a considerable portion of the left atrium being occupied by the tumor, the patient maintained sinus rhythm and showed no symptoms. The cardiac MRI concluded to a large left atrial myxoma. The patient was subsequently transferred to the cardiovascular surgery department where he underwent resection of this mass and the anatomic pathology confirmed the diagnosis of myxoma. The relevance and value of TTE for a precise diagnosis of cardiac myxoma, while cancer lung metastasis is highly suspected, is shown by our case.

I. INTRODUCTION

Primary cardiac tumors are extremely rare, with reports of 200 cases per million cases. Benign cardiac tumors make up about 75% of first cases [1]. About 50% of benign tumors are cardiac myxomas, which are primarily derived from or near the interatrial septum and grow into the left atrium. Heart myxomas can occur at any age and are more common in women, having a mean presentation age of 62 +/-13 years [1]. The clinical presentation may differ significantly. Obstructive heart failure is the most common presenting symptom in patients; however, other symptoms may be vague or nonspecific, such as arrhythmia, systemic embolization, or constitutional symptoms (fever, sweats at night, and weight loss). In one in five cases, a myxoma may be asymptomatic and discovered by accident, that is our case.

II. CASE REPORT

Patient information: 57-year-old male patient, a previous smoker, with a history of non-operable squamous cell lung cancer, was admitted to hospital for a CT chest control, after eight months of radio-chemotherapy. The patient doesn't report any complaints.

Clinical findings: on physical examination, he was afebrile and had normal vitals but a diastolic murmur, rumble and early diastolic plop were heard on cardiac auscultation.

Diagnostic assessment: The electrocardiogram shows a sinus rhythm. Transthoracic echocardiography (TTE) revealed a large mobile round mass (3.6x 4 cm) in the left atrium (Fig. 1). The mean pressure gradient across the mitral valve on Doppler was 7 mmHg. To confirm the diagnosis, a transesophageal echocardiography (TEE) was performed. A large (4 cm x 3.6 cm), ovoid and heterogeneous mass was observed in the left atrium attached to the left atrial septum. The finding was confirmed by cardiac MRI (Figure 2) that showed a presence at the level of the left atrium of a rounded tissue mass measuring 48 mm x 37 mm, based on a wide implantation fitting into the lower part of the inter atrial septum, the mass is mobile, prolapsing into the mitral orifice associated to a turbulent anterograde mitral flow in favor of mitral obstruction. The MRI aspect is in favor of a large myxoma of the left atrium with probable thrombi on the fringes.

Therapeutic interventions and follow-up: Cardiovascular surgery was consulted for the resection of the left atrial myxoma. The patient underwent an uncomplicated resection of the left atrial mass. Pathology findings were consistent with a myxoma.

III. DISCUSSION

Primary cardiac tumors are incredibly uncommon [2]. Less than 0.1% of incidence was found in one research [3]. Nonetheless, in an autopsy series, it was found that up to one in five cancer patients had heart metastases, which is more than 20 times more common [4]. The majority of cardiac tumors are benign. Atrial myxomas account for almost 50% of benign cardiac tumors [4].

Clinical manifestations of atrial myxomas range from non-specific symptoms to potentially fatal consequences like acute cardiac failure, stroke, or even unexpected death [5–6]. These symptoms included the following: 64% of patients had auscultatory findings, 15% had the classic tumor plop, and mitral valve obstruction and electrocardiographic evidence of left atrial hypertrophy. 20% had neurologic deficits, and 29% had systemic embolization. Softer and smaller tumors (less than 4.5 cm) were linked to a higher incidence of embolization [7]. Of the patients, 34% experienced constitutional symptoms (such as fever and weight loss). However asymptomatic large cardiac myxoma of the left atrium, as described in our case, is very rare. The diameter and weight of tumors vary greatly, from 1 to 15 cm and 15 to 180 grams, respectively [8]. Myxomas that are friable or villous account for about 35% of cases, and these typically show up as emboli. Depending on the tumor's anatomical location, the cardiovascular symptoms can vary. Most of the remaining myxomas are located in the right atrium, with the left atrium accounting for about 80% of their origins [9-10]. Most cardiac myxomas occur in the left atrium and are attached by a stalk to the atrial septum in the region of the fossa ovalis. About 90% of these myxomas are solitary.

The preferred imaging modality for diagnosing cardiac myxomas is two-dimensional echocardiography, which typically shows the mobile myxoma attached to the interatrial septum by a thin stalk [11]. Myxomas exhibit variable echogenicity and sporadic calcifications on echocardiography. The attachment to the interatrial septum is the primary indicator for the identification of a myxoma [12]. Therefore, during the echocardiographic examination, it is crucial to determine the site of tumor attachment. A myxoma can be distinguished from other masses by the presence of an attachment stalk. Typically, TTE is enough to diagnose a patient; nevertheless, transesophageal echocardiography can be utilized in this situation if the results are not ideal.

Also ultrafast transthoracic scan and cardiac magnetic resonance imaging (MRI) offer more detailed information. In our case, the diagnosis has been revealed by TTE due to the characteristic appearance. Though there were several differential diagnoses, including thrombi, vegetation, metastases, the precise differentiation is eventually determined by histological analysis.

In addition, lung carcinoma is a common tumor with highly heterogeneous malignancies. Nonetheless, the concomitant occurrence of a left atrial myxoma and an adenocarcinoma lung carcinoma is extremely rare. Herein, we described a case of synchronous silent left atrial myxoma and primary lung carcinoma which makes the diagnosis of myxoma more difficult.

Thrombi are much less prevalent when there is no underlying heart disease, although they can happen in situations where there is a hypercoagulable state, including autoimmune disease, pregnancy, or some types of cancer. It could be challenging to differentiate thrombi from myxomas during a transthoracic scan. A few distinguishing characteristics could help to distinguish between myxomas and thrombi. For instance, myxomas often appear as a single mass and are rarely calcified. The most frequent location is the left atrium, and the fossa ovalis is frequently where an attachment stalk is found. However, the appearance of thrombi and myxomas varies greatly, and pathologic investigation may be necessary for a conclusive diagnosis.

The majority of the time, atrial myxoma can be surgically removed. Wide removal of the implantation base is necessary as part of radical tumor excision to lower the recurrence rate. One the atrial septal defect is sealed with a pericardial or Dacron patch after the entire bulk and the entire thickness of the surrounding inter-atrial septum are removed [13].

IV. CONCLUSION

Among primary cardiac tumors, atrial myxoma accounts for 50%. The amount of symptoms and the size of the tumor may differ in a small number of cases, like ours. Although there was a large myxoma, the patient was asymptomatic, which made the diagnosis difficult. Echocardiography provides an excellent diagnostic technique for detection of intracardiac masses. Standard TTE is especially useful for the diagnosis of ventricular thrombi, atrial myxomas, and thrombi that protrude into the atrial cavity. For definitive treatment to be provided and to lower the chance of further problems including embolic and systemic symptoms, prompt surgical resection is necessary.

COMPETING INTERESTS

The authors declare that they have no competing interest

Figures

Figure 1: four chamber view and parasternal view on transthoracic echocardiography revealing the presence of a large mobile round mass (3.6x 4 cm) in the left atrium

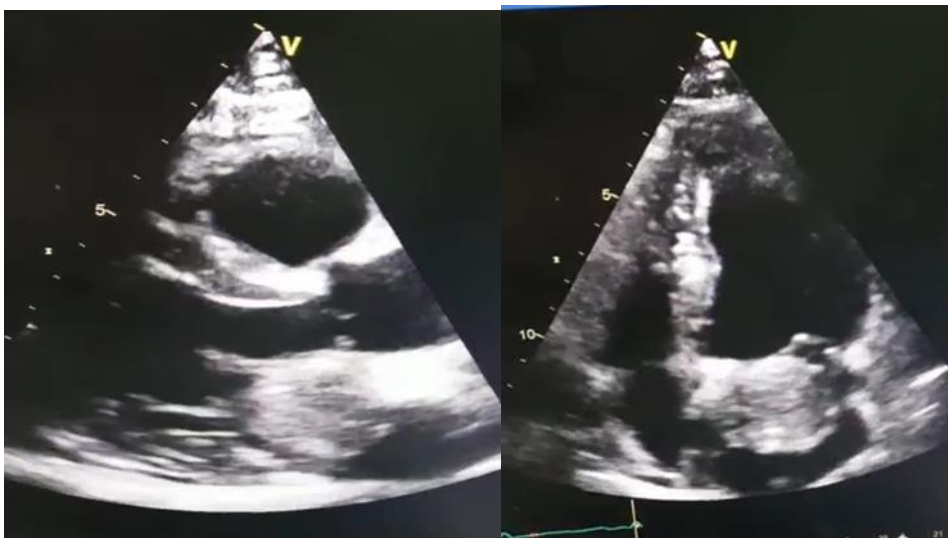
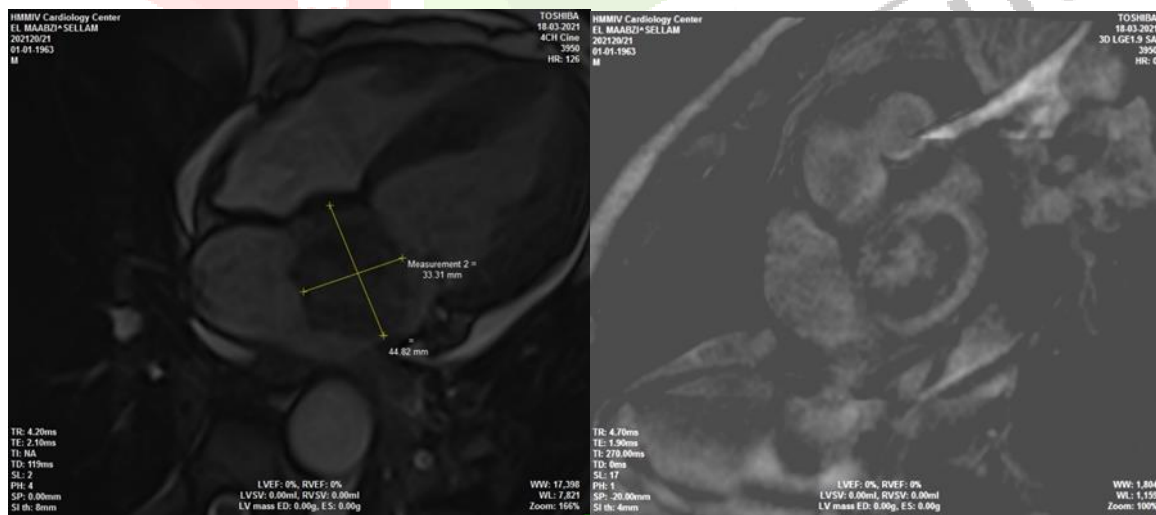


Figure 2: cardiac MRI showing a large myxoma of the left atrium with probable thrombi on the fringes



REFERENCES

1. Reynen K. Frequency of Primary Tumors of the Heart. *The American Journal of Cardiology*. 1996 ;77 :107.
2. Frequency of primary tumors of the heart. Reynen K. *Am J Cardiol*. 1996 ;77:107.
3. Tumors of the heart: A 20-year experience with a review of 12,485 consecutive autopsies. Lam KY, Dickens P, Chan AC. <http://europepmc.org/abstract/med/8215825>. *Arch Pathol Lab Med*. 1993; 117:1027–1031.
4. McAllister HA Jr, Fenoglio JJ Jr. Tumors of the Cardiovascular System. *Atlas of Tumor Pathology*. Second Series, Fa. Washington DC: Armed Forces Institute of Pathology; 1978. Benign Tumors and Cysts of the Heart and Pericardium; pp. 1–20.
5. Heart failure and syncope due to a giant atrial myxoma (Article in English, Portuguese) Cabrera H, Trindade e Silva LP, Gamboa C. *Rev Port Cardiol*. 2010; 29:315–319.
6. Giant left atrial myxoma with dual coronary supply presenting with recurrent stroke. Akhundova A, Samedov F, Cincin A, et al. <http://link.springer.com/article/10.1007%2Fs00059-013-3999-4>. *Herz*. 2015; 40:318–320.
7. Risk prediction for emboli and recurrence of primary cardiac myxomas after resection. Wang Z, Chen S, Zhu M, et al. *J Cardiothorac Surg*. 2016;11:22.
8. Clinical presentation of left atrial cardiac myxoma. A series of 112 consecutive cases. Pinede L, Duhaut P, Loire R. *Medicine (Baltimore)* 2001 ;80:159–172.
9. Analysis of benign ventricular tumors: long-term outcome after resection. ElBardissi AW, Dearani JA, Daly RC, et al. *J Thorac Cardiovasc Surg*. 2008 ;135 :1061–1068.
10. Clinical presentation of left atrial cardiac myxoma. A series of 112 consecutive cases. Pinede L, Duhaut P, Loire P. *Medicine (Baltimore)* 2001 ;80 :159–172.
11. Braunwald E. *Heart Disease. A Textbook of Cardiovascular Medicine*, 6th ed. Philadelphia: WB Saunders Co; 2005.
12. Feigenbaum H, Armstrong W, Ryan T. *Feigenbaum's Echocardiography*. Philadelphia: Lippincott Williams & Wilkins; 2005:701–733.
13. Ren DY, Fuller ND, Gilbert SA, Zhang Y. Cardiac Tumors: Clinical Perspective and Therapeutic Considerations. *Current Drug Targets*. 2016 Jul 3