



A CASE STUDY OF CHRONIC OTITIS MEDIA TREATED WITH HOMOEOPATHIC SIMILLIMUM

Dr.Kiran Tidke (Assistant professor)

Dhanvantari Homoeopathic Medical College And Hospital & Research Centre, Nashik, India.

Abstract:

Introduction - Otitis media is the inflammation of middle ear cleft. Otitis media is not only the most common bacterial infection in children, but also a leading cause of hearing loss in children. **Main Complaint of Patient** - A case of yellowish, offensive, bloody discharge from right ear on and off with itching. **Diagnosis** – Chronic Otitis Media. **Intervention** - After analyzing the symptoms presented by the patient, pulsatilla 200 was prescribed. **Outcome** – After prescribing Homoeopathic simillimum the condition of the patient improved and does not show any side effects. **Conclusion** - The author has tried to find out the scope of homoeopathic medicines in chronic Otitis media.

Keywords:

Otitis media, Homoeopathic medicines.

Introduction:

Otitis media represents an inflammatory condition of the middle ear. Factors believed to affect the occurrence of Otitis media include age, gender, race, genetic background, socioeconomic status, type of milk or formula used in infant feeding, presence or absence of respiratory allergy, season of the year, pneumococcal vaccination status. Children with certain types of congenital craniofacial anomalies are particularly prone to Otitis media.

The peak incidence and prevalence is from 6-20 months of age. The incidence of Otitis media is greater in boys than in girls. Otitis media is second in prevalence only to the common cold. The prevalence rate of acute Otitis media in India is around 17-20% & chronic Otitis media is 7.8%.^[1]

Classification of otitis media:-

- 1.Acute suppurative otitis media – It clinically presents as tense and hyperaemic tympanic membrane along with pain and tenderness and sometimes mastoiditis.
- 2.Chronic suppurative otitis media – It manifests clinically as draining ear with perforated tympanic membrane and partially impaired hearing.

The most common organisms are streptococcus pyogenes, haemophilus influenzae, pneumococcus and staphylococcus aureus. Chronic otitis media is the chronic inflammation of the middle ear and mastoid cavity, which presents with recurrent or persistent ear discharges (otorrhoea) for 2 to 6 weeks. The common causes of chronic otitis media are multiple episodes of acute otitis media, unhygienic conditions, low socioeconomic status. The common clinical features are ear discharge, hearing loss, earache, tinnitus, vertigo. Treatment includes use of antibiotics, nasal decongestant drops to improve drainage of middle ear through the eustachian tube and analgesics to relieve pain and ear drops are also used.^[2] Modern medicine provides a temporary relief and suppresses the problem.

Remedies for treatment of chronic otitis media includes Calcarea carb, lycopodium, pulsatilla, silicea, calcarea ostrearum, kali-bich, tellurium, mercurius solubilis, hepar sulph, sulphur.^[3]

Case presentation:

A 23years male patient came on 15/09/2017 with complaints of:-

Presenting complaints:

| Presenting complaints | Location | Sensation | Modalities | Concomitants |
|--|-----------|----------------------------|--|-----------------------------|
| Pain and yellowish, offensive and occasional bloody discharge from right ear on and off. Since 4 years. [But increased since 3 months] | Right ear | Itching over the right ear | Aggravation by-cold food and drinks, ice cream. Amelioration by-cotton plug in ear. | Mild difficulty in hearing. |

No otalgia, no tinnitus, no hearing problem.

Past history:

Other mode of treatment taken for same ailments and then discharges stop but since last 2 years, same episode has occurred two times in a month.

Family history:

Mother – Hypertension. Father – Apparently healthy.

Personal history:

Desires: sweets.

Aversion: ghee.

Appetite: adequate.

Thirst: 4 to 5 glass/ day.

Urine: 4 to 5 times/ day.

Stool: once/ day.

Sleep: sound.

Constitution: well built. Wheatish Complexion.

Thermal state: Hot

Physical

| | Summer | Winter | Rainy |
|-----------|-----------|-----------|-----------|
| Covering | ✗ | ✓ | ✗ |
| Fan | ✓ | ✗ | ✗ |
| Bathing | Luke warm | Luke warm | Luke warm |
| Tolerance | Cold | Cold | Cold |

examination:

Pulse: 76/min.

B.P.: 120/70mm of Hg

No pallor.

Systemic examination:

Respiratory system: Air entry bilaterally equal.

Central nervous system: conscious and well oriented.

Cardio vascular system: S1 S2 normal.

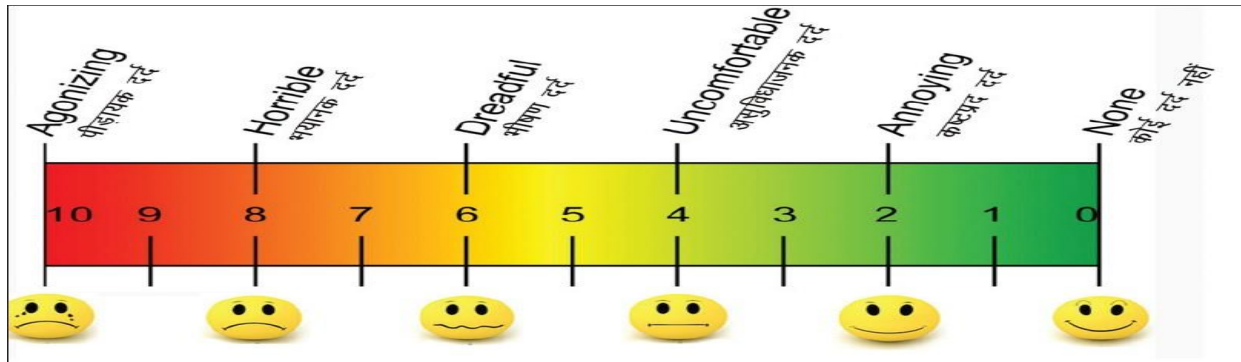
P/A: soft and non- tender.

Local examination:

Right ear – yellowish, watery, offensive discharge.

Left ear – wax.

Hearing test: 1.Rinne test – positive (air conduction is greater than bone conduction). 2.Weber test – sound is heard when tuning fork is placed in midline.

Visual Analogue Scale: 8**Mental state:**

-The patient was having financial tension. He want to do education in technical line but due to money problem he did graduation.

-Anxiety about what will happen in future.

-Still he is unable to decide whether to stay in same job or should change.

-Care, feeling and love for others.

Diagnosis: Chronic Otitis media.

THERAPEUTIC INTERVENTION –**Rubrics and Remedial analysis:-**

MIND – ANXIETY – future, about

MIND – IRRESOLUTION

MIND – AFFECTIONATE

GENERALS – FOOD and DRINKS – sweets – desire

GENERALS – FOOD and DRINKS – fats – aversion

EAR – PAIN - right

EAR – PAIN – cold, taking from

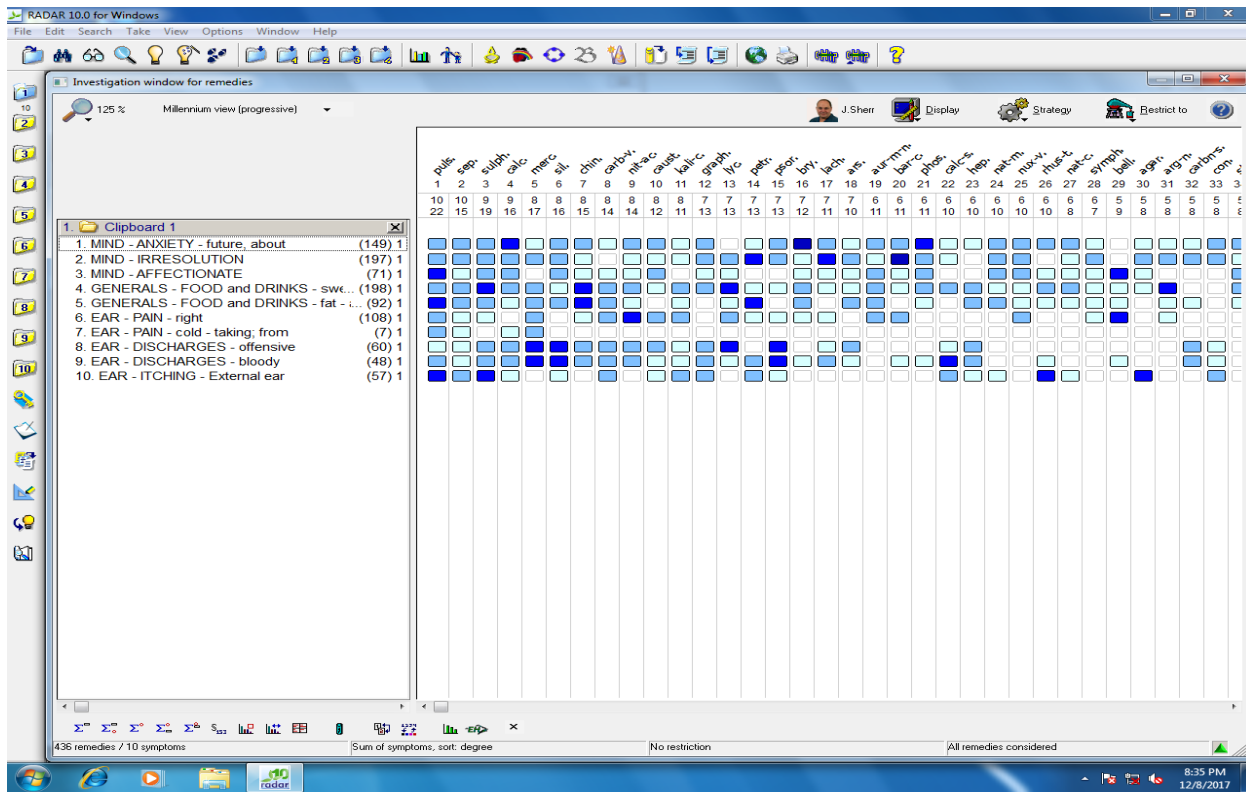
EAR – DISCHARGES offensive

EAR – DISCHARGES – bloody

EAR – ITCHING – External ear

Case was repertorised on the following symptoms by using RADAR 10.5 (Schroyens F. synthesis 9.0).

Repertorization Sheet:

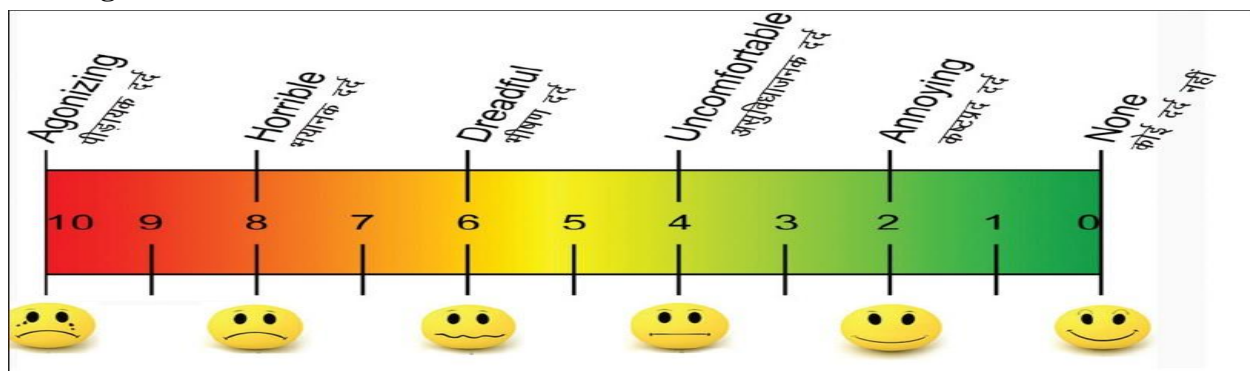


Prescription: Pulsatilla 200 x 3 doses x 8 hourly
Sac Lac 30 x TDS x 15 days.

Follow up: 1/10/2017

- Pain and discharges from right ear decreased than before.
- Bloody discharge from right ear decreased in last 15 days.
- But complaints aggravates after taking cold.
- Now no itching over the right ear.
- Difficulty in hearing decreased.

Visual Analogue Scale: 4



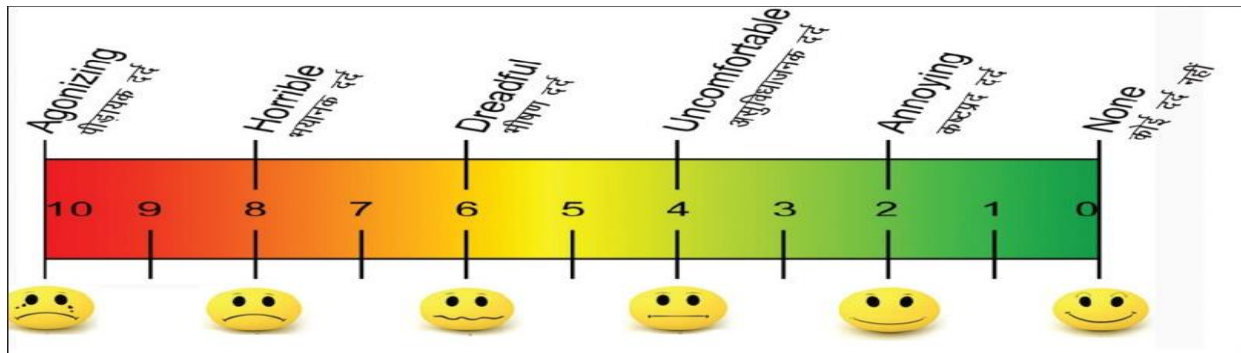
Prescription: Sac Lac single dose
Sac Lac 30 x TDS x 15 days

Follow up: 16/10/2017

- Pain and discharge from right ear decreased.
- No bloody discharge from right ear.

- No itching over the right ear.
- No difficulty in hearing.
- Complaints are better now.
- No new complaints.

Visual Analogue Scale: 2



Prescription: SL 30 x TDS x 15 days

Conclusion:

1. As per the visual analogue scale study, the intensity of pain has reduced.
2. The frequency of disease before treatment 2 times in a month has reduced to 0 per month for two consecutive months.
3. Thus, from above study researcher has concluded that after administration of homoeopathic simillimum the condition under study, that is chronic Otitis media improved substantially.
4. The author is still observing the case for any recurrence.

Discussion:

1. Homoeopathic medicines like pulsatilla, merc sol, calcarea carb, silicea, sulphur, graphites, hepar sulph are usually found on Repertorization.
2. After reportorial study the knowledge of materia medica, the therapeutics guide us to reach upto Homoeopathic simillimum medicines.
3. In the otitis media like conditions conventional conservative medicines has limited role and surgical treatment doesn't assure the permanent cure.

Declaration of patient consent – The authors certify that they have obtained appropriate case of the patient in the written format.

Conflicts of Interest – Authors declare no conflicts of interest.

References:

- 1) Mohan Bansal. Essentials of Ear, Nose and Throat. 1st edition. New Delhi: The Health sciences publisher; 2016. p. 101.
- 2) Harsh Mohan. Textbook of Pathology. 6th edition. New Delhi: Jaypee Brothers Medical publishers (P) ltd; 2010. p. 514.
- 3) Boericke. W. pocket manual of homoeopathic materia medica and repertory. Rep.ed. New Delhi: B Jain Publishers: 1998.
- 4) Radar 10.5 (Schroyens F. synthesis 9.0).