



# AN AI-BASED DIABETIC RETINOPATHY DETECTION USING RETINAL IMAGES

S Priya<sup>1</sup>, S Mahalakshmi<sup>2</sup>,

G Gokul Surendra kumar<sup>3</sup>, B Balaji<sup>4</sup>, S Shobana<sup>5</sup>

Assistant Professor<sup>1,2,3,4,5</sup>, Department of Electronics and Communication Engineering,

PERI Institute of Technology, Chennai, India-600048.

**Abstract:** Diabetic Retinopathy (DR) has been considered to be the most menacing eye-related disease which causes blindness or vision loss in the long run if not identified early. Because DR is not an irreversible procedure and only vision is preserved via care. Consequently, Early diagnosis and care with DR will significantly minimize the chance of vision loss. Thus an efficient computing method has to be employed to facilitate the detection of DR from retinal images. Digital image processing is one such method where it influences the medical field. In this paper, a DR detection technique, involving an artificial intelligence approach by utilizing a retinal image, where a fundus image has been obtained from a patient's retina.

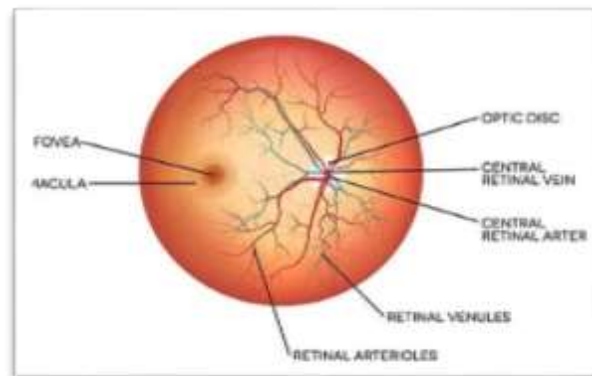
**Index Terms:** Vision loss, Artificial intelligence, Diagnosis

## 1. INTRODUCTION

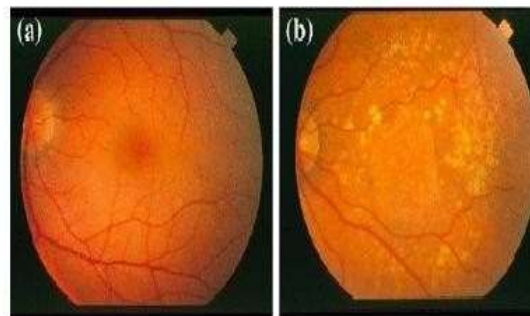
To recover from any disease, early detection makes the treatment to be more effective. Diabetes mellitus is a major clinical and public health problem, especially among the working-age population which results from the presence of high sugar levels in blood. It can also develop diseases related to the eyes, heart, kidneys, and so on. As far as the eye is a matter of concern, diabetes increases the formation and maturation of cataracts. In the retina, diabetes leads to retinopathy which is one of the leading causes of irreversible blindness in around 40-50% of diabetics. Thus, there arises a need for awareness among people to know its importance and intense care has to be given to eyes. Predicting its presence in the fundus images and the identification of diabetic retinopathy in early-stage has always been a major challenge for decades. Hence, early detection and treatment of DR are very important. Physicians rely heavily on imaging to make accurate diagnoses of eye diseases. It seems to be very interesting to know about the complex functioning of the eyes which helps us to see visual images around the world. The eye is a fascinating part of your body, and the second most complex organ, after

the brain. The light is passed through the cornea (the front layer of the eye) which helps the eye focus. Some of the light enters through an opening called the pupil. The iris controls the light intensity. When the light is focused throughout the retina, a light-sensitive tissue located at the back of the eye that serves as the primary organ of the visual system., most of the light entering the eye is focused onto the focal point on the retina, known as the macula. The retina translates the optical images into neural impulses which are excited by the photoreceptors namely rods and cones which provide conscious light perception, color differentiation, and depth perception.

The main parts of a healthy retina and blood vessels, optic discs, and macula, and any variations in these components are symptoms of eye disease. Figure 1 shows the normal retina and its parts while Figure 2 shows the healthy and unhealthy retina.



**Figure 1:** Normal retina and its parts



**Figure 2:** a)Healthy retina b) Unhealthy retina

### 1.1 Unhealthy Retina

During the earlier stage of diabetic retinopathy, revascularization occurs which includes bleeding within the eye and may explode sometimes. Severe conditions can lead to blurred vision in diabetic patients. Clinically significant macular Odem, macular ischemia, vitreous and pre-retinal hemorrhages along with components of advanced diabetic eye disease viz. fractional retinal detachment, combined mechanism retinal detachment, recurrent or protracted vitreous or pre-retinal hemorrhages are the main causes of visual disability in diabetic retinopathy Automated DR prognosis is just possible by recognizing funds images with DR-related features. This may be difficult due to these DR-related lesions varying in contrast, appearance, and structure.

Recent advancements such as anti-VEGF agents, focal lasers, vitreoretinal surgery, funds angiography, OCT(optical coherence tomography), etc., have truly and well revolutionized the treatment of diabetic retinopathy. However, one of the fast-growing and refreshing developments in the application of diabetic care is Artificial intelligence Hence this paper illustrates an artificial intelligence-based approach to detecting the diabetic retinopathy stages.

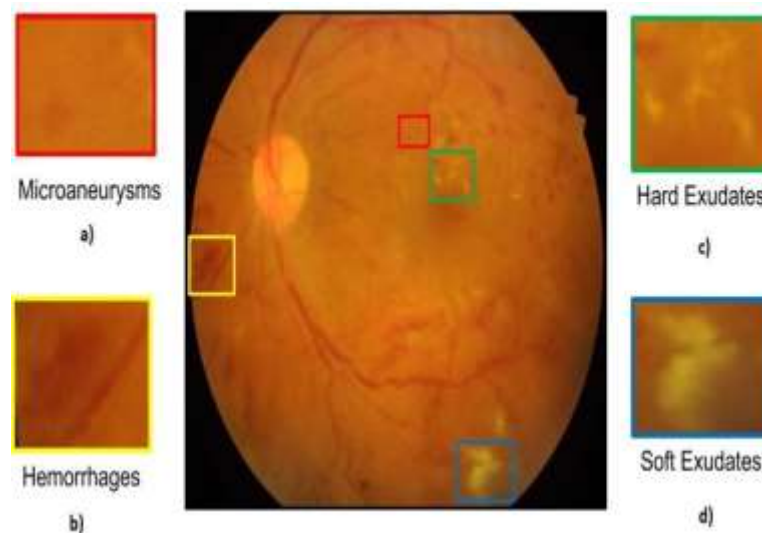
Abbood et al [1] present an algorithm for improving the quality of images to strengthen the standard of color fundus images by reducing the noise and improving the contrast and its experimental results are evaluated using two standard datasets- Eye PACS and MESSIDOR. Hazaimah et al [2] provide a MATLAB-based analysis and classification of the funds into Exudates, Micro aneurysms, Optical Disks, and hemorrhage. It also examines the proliferative and non-proliferative stages of DR. For this purpose, morphological operations such as erosion and dilation were also done. This proposed mechanism observed 98% accuracy in the detection DR within 39 seconds.

Arias-Serrano et al [3] projected an effective image processing approach for diabetic retinopathy detection from fundus images, the enhancement of the images included converting the images to (Hue, Saturation, and Intensity) and then de-noise the images. Zhou et al., [4] described a method for assessing retinal pictures called multi-instance learning (MIL). Through pre-trained CNNs, the learned characteristics are employed to obtain the DR image lesion. They are employed in the DR classification's global aggregation.

Bellemo et al [5] proposes a system where with the use of extracted retinal blood vessels, eye disease can be detected. At first retinal blood vessels from images are extracted. Then noise and environmental interference from the image are removed and for segmentation, local entropy thresholding is used. Using a training dataset of over 70,000 fundus images, Pratt et al.[6] trained a CNN using a stochastic gradient descent algorithm to classify DR into 5 classes, and it achieved 95% specificity, 75% accuracy, and 30% sensitivity. A DL model was trained from scratch on the MESSIDOR-2 dataset for the automatic detection of DR, and 96.8% sensitivity and 87% specificity were scored. Apart from the above journals we are referred some journals [7-10].

## 2. STAGES OF DIABETIC RETINOPATHY

DR is divided widely into two levels: DR (PDR) proliferative and DR (NPDR) non-proliferative. NPDR, referred to as the Diabetic Retinopathy background occurs when the blood vessels inside of the retina are weakened by diabetes, causing blood leakage and fluid on the retinal surface. DR is detected by the appearance of different types of lesions on retinal images. These lesions are micro aneurysms (MA), hemorrhages (HM), and soft and hard exudates. Micro aneurysms (MA) are the earliest signs of DR that appear as small red round dots on the retina due to the weakness of the vessel's walls. The size is less than  $125\ \mu\text{m}$  and there are sharp margins. Hemorrhages (HM) appear as larger spots on the retina, where its size is greater than  $125\ \mu\text{m}$  with an irregular margin. Hard exudates appear as bright-yellow spots on the retina caused by leakage of plasma. They



have sharp margins and can be found in the retina's outer layers. Soft exudates (also called cotton wool) appear as white spots on the retina caused by the swelling of the nerve fiber. The shape is oval or round. Figure 3 illustrates the fundus image.

**Figure 3:** Fundus image illustration a) Micro aneurysms b) Hemorrhages c) Hard exudates d) soft exudates

## 3. SYSTEM ARCHITECTURE

In general, diabetic retinopathy and classified into five stages or classes namely: normal, mild, moderate, severe, and Proliferative Diabetic Retinopathy. Hence it has to be classified Figure 4 shows the general block diagram of the classification of diabetic retinopathy.

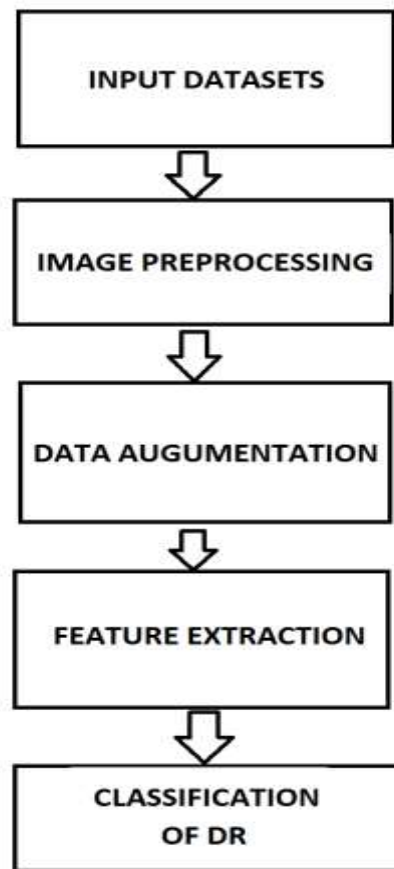


Figure 4: Block Diagram- DR

#### 4. DATA SETS USED

We used the datasets from the Indian Diabetic retinopathy image dataset and the Kaggle database. It contains images of both eyes for each subject. The photographs were captured using several cameras, in different conditions, lighting, and resolutions. The dataset is divided into two sets for the training and testing, each including eye photos taken from a different patient.

### 5. RESULTS AND DISCUSSION

The dataset from the Indian Diabetic retinopathy image dataset consists of 413 original images under the training set 103 images under the testing set for disease grading 54 images under the training set and 81 images under the testing set for segmentation. Micro aneurysms are the most crucial and distinguishing feature in detecting DR. We obtained an accuracy of 94% while evaluating the model which uses the KNN algorithm and CNN for image classification. The given below figures show the feature detection.




Figure 5: Process of execution

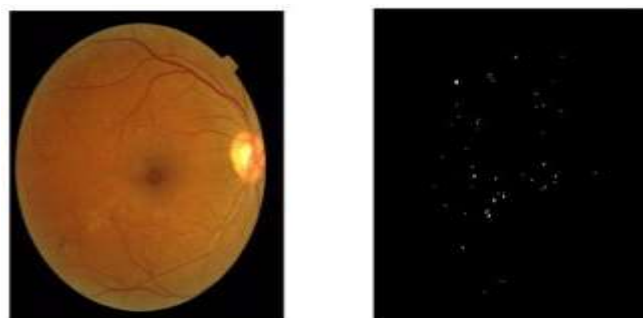
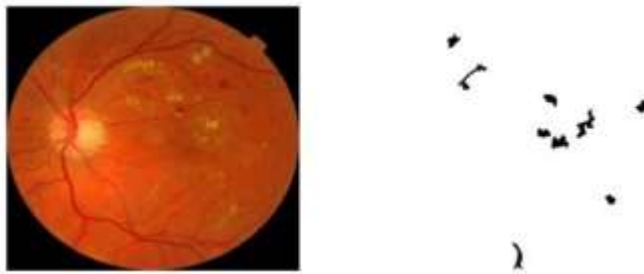
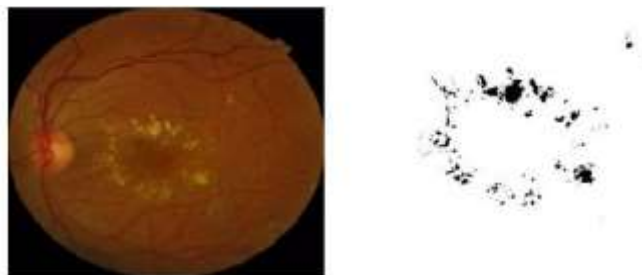


Figure 6: Micro aneurysm detection



**Figure 7:** Haemorrhage detection



**Figure 8:** Exudates detection

## CONCLUSION

Here we have discussed the diagnosis of DR and its phases. This war waged against this epidemic of Diabetes has a long way to go. It needs awareness among persons with diabetes to avoid the consequences which would be achieved by taking necessary action. Thus, its detection has to be enhanced. This project can help with the early diagnosis of DR stages to prevent loss of vision. Using CNN for image processing has increased the efficiency of the model.

## REFERENCES

- [1] Abbood, Saif Hameed, Haza Nuzly Abdull Hamed, Mohd Shafry Mohd Rahim, Amjad Rehman, Tanzila Saba, and Saeed Ali Bahaj. 2022. "Hybrid Retinal Image Enhancement Algorithm for Diabetic Retinopathy Diagnostic Using Deep Learning Model." *IEEE Access: Practical Innovations, Open Solutions* 10: 73079–86. <https://doi.org/10.1109/access.2022.3189374>.
- [2] Al Hazaimeh, Obaida M., Khalid M. O. Nahar, Bassam Al Naami, and Nasr Gharaibeh. 2018. "An Effective Image Processing Method for Detection of Diabetic Retinopathy Diseases from Retinal Fundus Images." *International Journal of Signal and Imaging Systems Engineering* 11 (4): 206. <https://doi.org/10.1504/ijsise.2018.10015063>.
- [3] Arias-Serrano, Isaac, Paolo A. Velásquez-López, Laura N. Avila-Briones, Fanny C. Laurido-Mora, Fernando Villalba-Meneses, Andrés Tirado-Espin, Jonathan Cruz-Varela, and Diego Almeida-Galárraga. 2023. "Artificial Intelligence Based Glaucoma and Diabetic Retinopathy Detection Using MATLAB — Retrained



<https://doi.org/10.12688/f1000research.122288.1>.

[4] Zhou, Lei, Yu Zhao, Jie Yang, Qi Yu, and Xun Xu. 2018. “Deep Multiple Instance Learning for Automatic Detection of Diabetic Retinopathy in Retinal Images.” *IET Image Processing* 12 (4): 563–71. <https://doi.org/10.1049/iet-ipr.2017.0636>.

[5] Bellemo, Valentina, Zhan W. Lim, Gilbert Lim, Quang D. Nguyen, Yuchen Xie, Michelle Y. T. Yip, Haslina Hamzah, et al. 2019. “Artificial Intelligence Using Deep Learning to Screen for Referable and Vision-Threatening Diabetic Retinopathy in Africa: A Clinical Validation Study.” *The Lancet. Digital Health* 1 (1): e35–44. [https://doi.org/10.1016/s2589-7500\(19\)30004-4](https://doi.org/10.1016/s2589-7500(19)30004-4).

[6] Pratt, Harry, Frans Coenen, Deborah M. Broadbent, Simon P. Harding, and Yalin Zheng. 2016. “Convolutional Neural Networks for Diabetic Retinopathy.” *Procedia Computer Science* 90: 200–205. <https://doi.org/10.1016/j.procs.2016.07.014>.

[7] Arrigo, Alessandro, Emanuela Aragona, Francesco Bandello, IRCCS San Raffaele Scientific Institute, Vita-Salute San Raffaele University, Milan, Italy, IRCCS San Raffaele Scientific Institute, Vita-Salute San Raffaele University, Milan, Italy, and IRCCS San Raffaele Scientific Institute, Vita-Salute San Raffaele University, Milan, Italy. 2023. “Artificial Intelligence for the Diagnosis and Screening of Retinal Diseases.” *USO ophthalmic Review* 17 (2): 1. <https://doi.org/10.17925/usor.2023.17.2.1>.

[8] Bidwai, Pooja, Shilpa Gite, Kishore Pahuja, and Ketan Kotecha. 2022. “A Systematic Literature Review on Diabetic Retinopathy Using an Artificial Intelligence Approach.” *Big Data and Cognitive Computing* 6 (4): 152. <https://doi.org/10.3390/bdcc6040152>.

[9] Deshmukh, S.V., and A. Roy. 2021. “An Empirical Exploration of Artificial Intelligence in Medical Domain for Prediction and Analysis of Diabetic Retinopathy: Review.” *Journal of Physics. Conference Series* 1831 (1): 012012. <https://doi.org/10.1088/1742-6596/1831/1/012012>.

[10] Rajamani, Shalini, and S. Sasikala. 2023. “Artificial Intelligence Approach for Diabetic Retinopathy Severity Detection.” *Informatica. An International Journal of Computing and Informatics* 46 (8). <https://doi.org/10.31449/inf.v46i8.4425>.