



AN OVERVIEW OF TREATMENT & MANAGEMENT CATARACT

Pratik Anil Bhand*, Hemant J. Pagar

“Department of Pharmacology”

Dr. Vithalrao Vikhe Patil Foundation's College of Pharmacy,

Ahmednagar, Maharashtra, India. 414111.

Abstract-

Today the incidence of diabetes mellitus is increasing devastatingly, and cataracts are one of the most common causes of visual impairment. Advances in cataract surgery techniques and instruments have generally improved outcomes. However, surgery may not be safe or effective for certain people with preexisting retinal disease or vision loss. Functional vision is essential in our everyday vision. Different tasks in our daily lives use different parts of the visual system, which reflects our perspective in real-world situations where we need to see both small, high-contrast and large, low-contrast images. This review article addresses different aspects related to cataracts in people with diabetes. Most cataracts are caused by the aging of the eye lens, which continues to grow throughout life as new lens fibers continue to be laid down in the lens of the eye rather than replacing existing ones. It is maintained by many interdependent factors that contribute to optical homogeneity.

Key Words- Cataract, Eye, Eye lens, Etiology, Surgery

Introduction-

The implantation of an intraocular lens (IOL) during cataract surgery is one of the most popular surgical procedures worldwide. According to the World Health Organization, 32 million cataract operations will be worldwide in 2020. Following cataract surgery, mono-focal, multifocal, accommodating, and extended-depth-of-focus (EDOF) IOL options are currently available [1].

Since conventional mono-focal IOLs can only focus a patient's vision at one distance (either distant or near), patients who receive mono-focal IOLs frequently need to wear glasses after surgery to enhance their near or intermediate vision. Multifocal IOLs are made to divide incident light into two or more points of focus; however, these IOLs are constrained by the need to balance the focused and out-of-focus images while minimizing optical aberration [2].

Multifocal IOLs are linked to glare or halos despite the benefit of improved near vision and independence from glasses. Multifocal IOLs are made to divide incident light into two or more points of focus; however, these IOLs are constrained by the need to balance the focused and out-of-focus images while minimizing optical aberration [2]. Multifocal IOLs are linked to glare or halos despite the benefit of improved near vision and independence from glasses. Multifocal IOLs are made to divide incident light into two or more points of focus; however, these IOLs are constrained by the need to balance the focused and out-of-focus images while minimizing optical aberration [2]. Multifocal IOLs are linked to glare or halos despite the benefit of improved near vision and independence from glasses. Multifocal IOLs are made to divide incident light into two or more points of focus; however, these IOLs are constrained by the need to balance the focused and out-of-focus images while minimizing optical aberration [2].

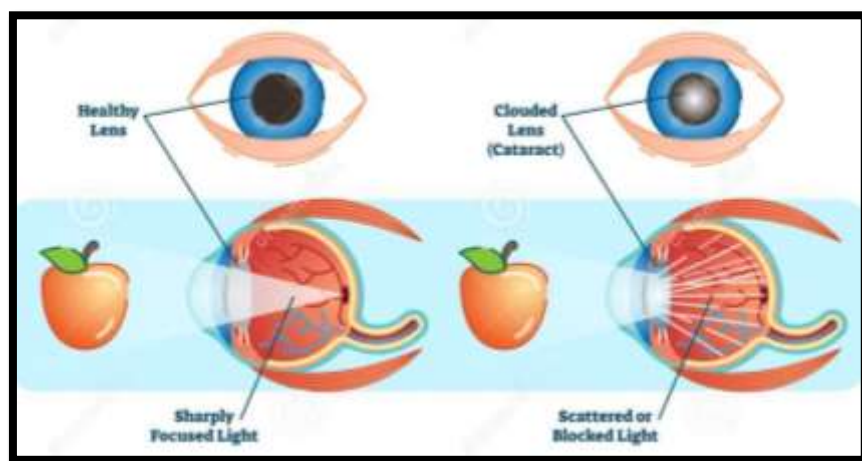


Figure Number 01- Cataract Condition

Cataracts remain the leading cause of blindness worldwide, affecting approximately 18 million people.² Because cataracts develop at an early age and are two to five times more common in people with diabetes, vision loss affects the working population. ^{3, 4} Overall, it is estimated that up to 20% of all cataract surgeries are performed on people with diabetes. A Wisconsin study found that the 10-year cumulative incidence of cataract surgery was 27% for those with early-onset diabetes and 44% for those with early-onset disease. Share the same favorable results. Some studies have reported that cataract surgery may have side effects such as progression of retinopathy, vitreous hemorrhage, iris neovascularization, and decreased or lost vision.⁸⁻¹⁰ Complications with an emphasis on clinical aspects [4, 5].

Functional vision-

Functional vision is our everyday vision. Different tasks in our daily life use different parts of the visual system. This reflects our perspective in real-world situations where we need to see both small, high-contrast images and large, low-contrast images. Our perception, the health of our visual system, and the processing function of our

brain all play an important role in how well we see the world. I am particularly interested in how well it converts. This is how our eyes and brains work to transform images into visuals. The retina/brain system filters images into different sizes and contrast levels. At the cortical level, many properties come into play that influence the final processing of visual information [6-10].

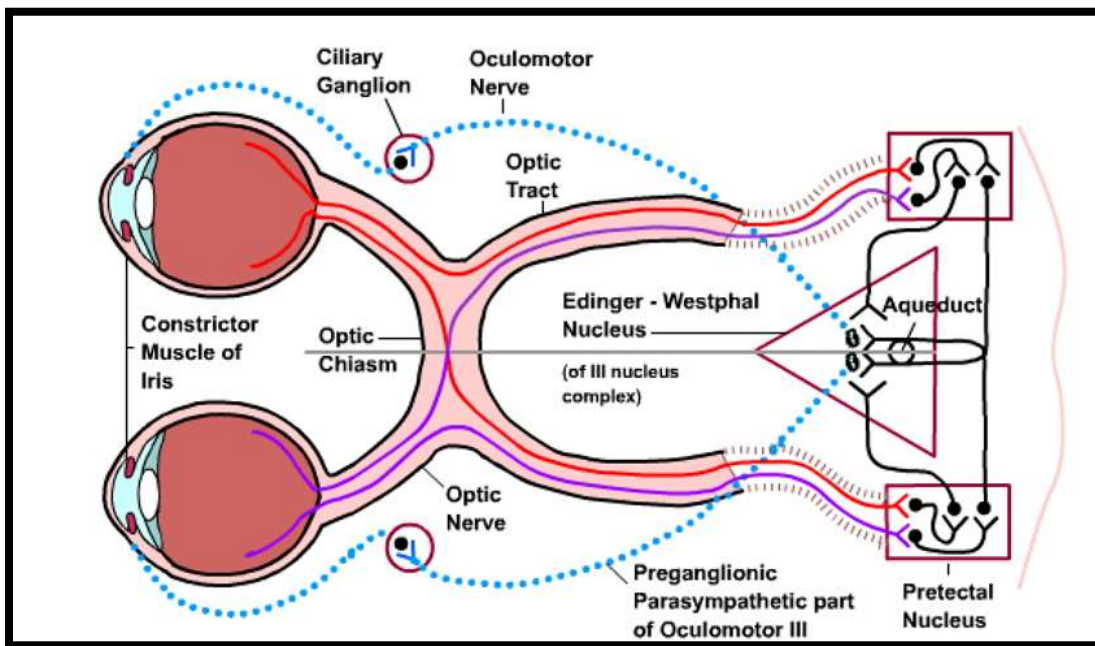


Figure Number 02 - The mechanism of healthy vision

These include attention, anticipation, memory, discrimination, and other perceptual-cognitive properties. Examining the complexity of the visual system makes it easy to see how the quality of input influences the quality of the visual experience. The canal model describes how different visual cells or canals process different aspects of vision, such as color, size, shape, contrast, and movement. Each visual channel collects different information about these different aspects of vision and transmits them separately to the brain. processed in the brain and assembled into a complete image [11].

Everything we see is resolved into a series of spatial frequencies or channels. Channels are size-selective. Our visual system uses these different channels to see in high and low-contrast situations. Our vision is a combination of all these channels. The channels used to see letters in the 20/20 vision test may differ from those used to see things in everyday life. Since these channels are independent, the sensitivity of each channel must be tested separately to determine how well objects of various sizes are seen [12].

Etiology-

Most cataracts are caused by aging of the eye lens. The lens is unusual in that it is one of the few structures in the body that continues to grow throughout life, as new lens fibers continue to be laid down in the lens of the eye, not replacing existing ones. A lens' clarity is maintained by many interdependent factors that contribute to its optical homogeneity. This includes its microscopic structure and chemical composition. With age, a tan pigment gradually accumulates on the inside of the lens, reducing light transmission. There are also structural changes in the lens

fibers that disrupt the regular structure and arrangement of fibers required to maintain optical clarity. Extrinsic factors associated with cataract formation vary due to socioeconomic and geographic differences [13, 14].

A variety of factors appear to be important in developing countries, including malnutrition, acute dehydration at an early age, and excessive UV exposure. Cataracts are common in young adults in many developing countries. It is commonly associated with atopic disease and its treatment, and diabetes. Other causes of cataracts include various forms of trauma (direct penetration, crushing, radiation, electrical or metabolic), and congenital defects. This overview is for age-related cataracts only [15, 16].

Risk factors for Cataracts in Diabetes-

One of the earliest complications of diabetes mellitus is cataracts. According to research by Klein et al³ and others, people with diabetes mellitus have a 2–5 times higher risk of developing cataracts than people without the disease; for diabetics under 40, this risk may be as high as 15–25 times. ¹⁶ It has been suggested that impaired fasting glucose (IFG), a pre-diabetic condition, is a risk factor for the onset of cortical cataracts. ¹⁷ In a study from Iran, Janghorbani and Amini¹⁸ assessed 3,888 type 2 diabetic patients who had no cataracts at their initial visit and found that, after a mean follow-up of 3.6 years, there was a rate of cataract formation of 33.1 per 1000 person-years of observation [17, 18].

Prevention of Cataracts-

Non-enzymatic glycation of lens proteins, oxidative stress, and activated polyol pathways all appear to play a role in the development of diabetic cataracts. It would be premature to recommend a wide range of drugs in humans even though they have shown promise in preventing cataracts in animal models, including glycation inhibitors like Aspirin, Ibuprofen, Aminoguanidine, and Pyruvate, antioxidants like Vitamin C, Vitamin E, Carotenoids, Trolox, and Hydroxytoluene, and aldose reductase inhibitors like Zenarestat, Eplarestat, Imirestat [19-22].

Complications-

Extracapsular surgery using small incisions is safer than previous techniques, but complications still occur. The posterior capsule can rupture during surgery, which can result in the loss of some or all of the nucleus of the posterior segment. However, vitreous prolapse in the anterior segment is more common. Prolapsed vitreous should be carefully and carefully removed from the area of the incision and the lens implantation site. Posterior capsular rupture (with or without vitreous loss) has been reported in 2% to 4% of surgeries [23].

Capsular rupture is associated with an increased incidence of infected endophthalmitis, cystoid macular edema, and retinal detachment. Patients should be aware that some complications can result in loss of functional vision in the operated eye. Most surgeons estimate the risk to be around 0.1%, mainly due to three specific complications: infectious endophthalmitis, choroidal or suprachoroidal hemorrhage, and retinal detachment. This is of course especially important if the other eye does not have a useful field of view. Endophthalmitis remains a major problem

in developing countries. The regular occurrence of sporadic or clustered cases in mass cataract surgery 'camps' remains a challenge for involved organizations [24].

Cataract Surgery

Overall, cataract surgery in diabetic patients is more complicated. Phacoemulsification is associated with better visual outcomes, less inflammation, and less need for capsulotomy compared with extracapsular cataract surgery. In patients with diabetes, corneal hypoesthesia may occur. Common. Special care should be taken to protect the corneal epithelium during surgery. Corneal abrasions during or after surgery may heal slowly and lead to recurrent corneal erosions. Surgery through small incisions can minimize further loss of corneal sensation. Therefore, a posterior chamber intraocular lens (IOL) should be used whenever possible [25].

If the pupil is small preoperatively, it can be enlarged during cataract surgery using intracameral atropine and epinephrine cataract surgery, multiple sphincterotomies, dilated pupils, or a mechanical iris retractor. Peripheral retinal vision is improved with postoperative generous anterior capsulotomy and thorough cortical cleansing. an anterior capsulotomy is more common in diabetics, so the size of the capsulorhexis should be larger than usual and smaller than the diameter of the IOL optic to prevent opacification of the posterior capsule [26].

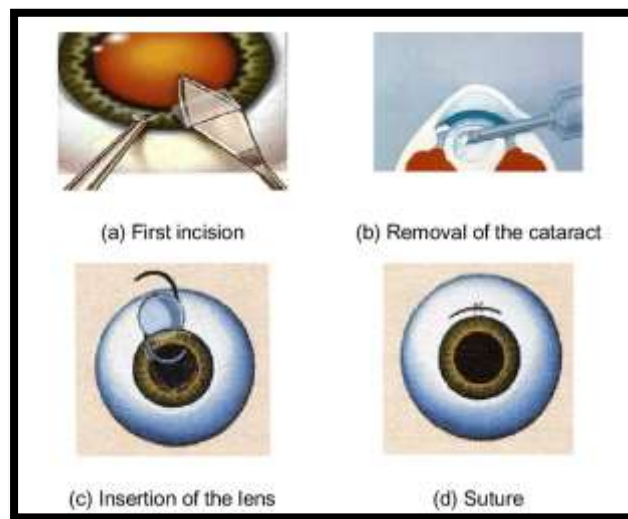


Figure Number 03 – The steps of cataract surgery

After surgery, it will be easier to diagnose and treat peripheral retinal pathology if the optic has a large diameter (6.0 mm or greater). Surgery time, the likelihood of intraoperative complications-, and postoperative inflammation are all impacted by the surgeon's skill. Longer and more difficult cataract procedures carry a higher risk of retinopathy progression and ensuing visual impairment.

In diabetic eyes, it is wise to take every precaution to reduce surgical trauma [27].

Patients with diabetes had a higher incidence of photic retinopathy during cataract surgery than patients without diabetes. They recommended that surgeons take the necessary precautions because diabetic patients may be more susceptible to phototoxic injury [28].

Combined cataract surgery and vitrectomy-

Numerous studies on combining cataract and vitrectomy surgery in diabetic patients have been conducted as a result of improvements in vitreoretinal and cataract surgical techniques. While cataracts frequently coexist in diabetic patients undergoing vitrectomy, lens opacities frequently worsen after vitrectomy. Combined surgery is comparable to sequential surgery and is safe and effective in terms of final visual outcomes [29].

A second operation can be avoided and surgical interventions in patients who are likely to need multiple procedures can be made simpler and more rapid with careful patient selection and the combination of the two procedures [30].

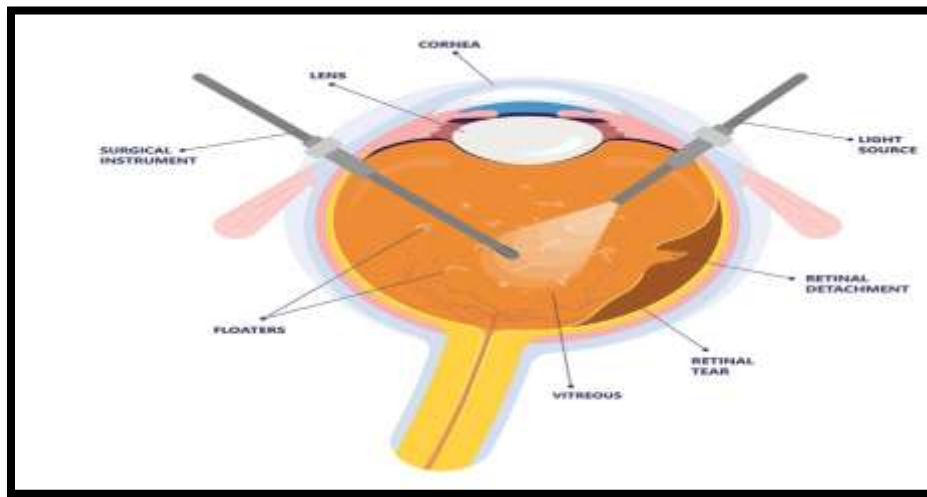


Figure Number 04 - Diagrammatic view of a vitrectomy

70-72 Numerous studies have suggested that the vitreoretinal interface plays a role in the development of persistent CSME after laser photocoagulation and have shown that combined surgery, when indicated, significantly improves anatomic and visual outcomes. 73-75 The choice of patient is essential for a successful outcome after combined procedures. After vitrectomy, patients over 60 are more likely to develop progressive lens opacification. Patients with cataracts that prevent membrane dissection or those with preexisting cataracts who are likely to experience a visual loss due to cataract progression in the next two years may benefit from combined surgery. Younger patients with little preoperative lens opacity may benefit from lens removal, while those with active rubeosis and severe traction and ischemia are less suitable candidates [31, 32]

Effect of cataract on other parts-

Effect of cataract surgery on retinopathy-

Numerous studies have been conducted on whether cataract surgery affects diabetic retinopathy. Although the progression of diabetic retinopathy after intracapsular (ICCE) and extracapsular (ECCE) cataract extractions is well documented, the efficacy of phacoemulsification remains controversial. Some studies have shown similar trends for the progression of diabetic retinopathy after phacoemulsification, while others have reported no significant changes [33].

These discrepancies may result from different criteria used to define the progression of diabetic retinopathy. Many authors believe that cataract surgery indeed independently influences the progression of diabetic retinopathy, while others believe that the natural history of the disease itself is more important than the effect of surgery [34].

Onset and progression of diabetic retinopathy in a retrospective study. Their data suggested that diabetic retinopathy was associated with male gender, disease duration, and poor glycemic control. Progression of preexisting diabetic retinopathy is associated with poor glycemic control. This study is limited by its retrospective character, a relatively small number of cases, and its inability to distinguish the natural course of the disease from the effects of surgery [35].

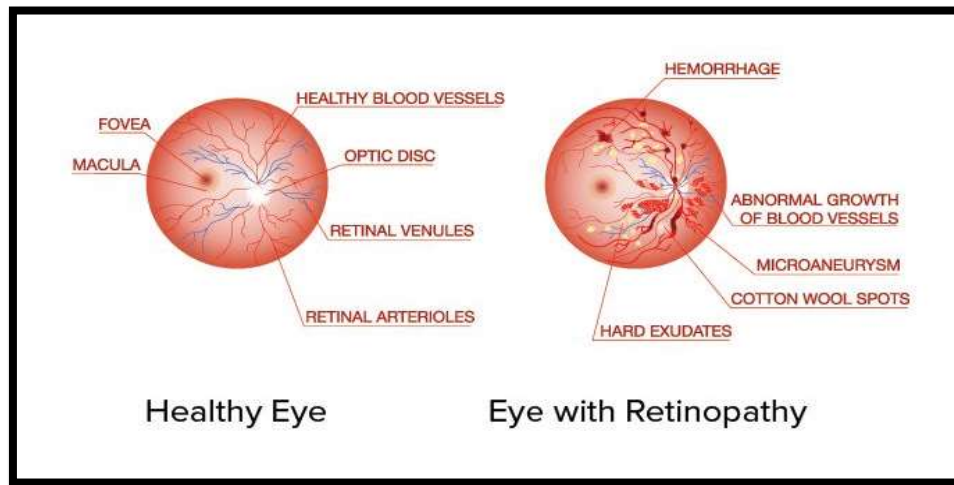


Figure Number 05 - Diagrammatic representation of retinopathy

To distinguish the effects of cataract surgery from the natural history of the disease, Dowler et al. A prospective study in which monocular surgery was performed and the other eye served as a control. These authors showed that uncomplicated cataract surgery with phacoemulsification does not accelerate the progression of diabetic retinopathy, in another prospective study by Squirrell et al. Monocular phacoemulsification was performed and the degree of diabetic retinopathy and diabetic maculopathy was assessed 12 months postoperatively in operated and non-operated fellow eyes [36].

This study also showed that uncomplicated phacoemulsification does not accelerate the course of diabetic retinopathy, and the observed progression likely represents the natural history of the disease.

It is characterized by low follow-up rates, well-documented BCVA measurements, accurate annual fundus photographs, and well-documented procedures. This report shows a trend for accelerated progression of retinopathy in operated eyes compared to other non-operated eyes. However, this trend did not reach statistical significance. The progression of diabetic retinopathy, especially in studies evaluating ECCE and ICCE, may be caused by disruption of the blood-ocular barrier or increased inflammation in diabetic patients after cataract extraction. The smaller incision size and shorter operative time of phacoemulsification may result in less inflammation and less disruption of the blood-ocular barrier [37].

Effect of cataract surgery on macular edema-

Changes in angiogenic factor levels after cataract surgery can exacerbate maculopathy. After uncomplicated cataract surgery, OCT imaging showed an increase in retinal thickness in diabetic eyes without retinopathy, which was comparable to non-diabetic patients but was not evident until 3 months after surgery. There was a trend towards increased retinal thickness in diabetic patients. In eyes without CSME at the time of surgery, the ETDRS report found a statistically significant difference in the prevalence of macular edema preoperatively and one year after surgery because the disease was either disease-free or successfully treated [38].

Another study reported that 56% developed new clinically detectable macular edema 1 year after surgery, compared with 50% within 6 months without treatment and 1 year. Spontaneous regression occurred in 75% within a year. Other data suggest that while macular edema is common after cataract surgery, it can follow a benign course and that many patients develop clinically significant macular edema postoperatively is not directly relevant. showed that it likely represents a progression in the natural history of the disease rather than the impact of surgery. Eyes with established CSME at the time of surgery behaved quite differently, with none resolving spontaneously within 1 year and the majority showing signs of clinical and angiographic deterioration [39].

Overall, his CSME present in diabetic eyes at the time of cataract surgery is unlikely to resolve spontaneously. A case report of severe macular edema after cataract surgery may explain the postoperative exacerbation of untreated preexisting macular edema due to lens opacification—diabetic macula after cataract surgery. Edema studies are difficult to conduct because they must be able to distinguish between diabetic macular edema and pseudocysts macular edema (Irvine-Gass syndrome) [40].

Fluorescein angiography can help distinguish. If angiography shows a petal pattern associated with papillary hyperfluorescence without retinopathy or microaneurysms, edema can be assumed to be the result of Irvine-Gass syndrome. However, some authors disagree that optic disc hyperfluorescence necessarily indicates the presence of pseudophakic macular edema. Postoperative laser coagulation for diabetic macular edema is controversial [41].

We conducted the first prospective controlled study to investigate the natural history of diabetic macular edema after cataract surgery. They found that only a minority of patients who developed macular edema required focal laser photocoagulation. Similarly, Dowler et al. reported that it did not resolve if present before, suggesting that early laser treatment in all cases of postoperative diabetic macular edema is unnecessary. As a rule, specialists perform argon laser treatment only 6 months after cataract surgery [42].

Posterior capsule opacification (PCO)-

Posterior capsular opacification (PCO) is a common complication of modern cataract surgery, with a reported incidence of 20-50% 5 years after surgery. A change in surgical technique and an improvement in his IOL technique resulted in a lower PCO rate. Lens epithelial cells (LECs) are the origin and cause of PCO. The proliferation of these cells is influenced by several factors, including optic edge design, optic haptic connections, and IOL material. Another important determinant is postoperative inflammation. The degree of postoperative

inflammation may be related to the development of PCOS. It has been suggested that surgical trauma and contact with IOLs stimulate residual LECs to produce cytokines [43].

These cytokines may affect her LEC in an autocrine or paracrine manner, inducing collagen production and fibrotic metaplasia. Diabetic eyes already have poor blood and water barrier function and are prone to postoperative inflammation. Many surgeons believe that PCOS is more common and severe in diabetic patients, but this issue remains controversial. Using retro illumination imaging, Zaczek and Zetterstrom showed that diabetic patients had less PCO than non-diabetic patients.

A new diagnostic system facilitates the assessment of PCOS. PCO density was quantitatively measured using the Scheimpflug slit image analysis system and showed no significant difference between diabetic and non-diabetic patients up to 12 months after cataract surgery. However, after 18 months, PCO increased significantly in the diabetic group. Their results also showed that diabetics were significantly more likely than controls to require laser capsulotomy [44].

Recent Development & Modern Techniques [45-50]-

Various improvements in surgical technique. Each is relatively small. Stacking up led to a significant increase in efficiency. Phacoemulsification devices have become more sophisticated, partly due to a better understanding of how they work and partly due to improved microelectronic controls. As a result, less physical energy is expended to rupture the core than it was a decade ago, allowing surgeons to use higher vacuums and aspiration speeds when aspirating debris.

A better understanding of some of the factors that lead to posterior capsular opacification, which can occur in the years following cataract surgery, may reduce its incidence from the 5-year incidence predicted 10 years ago⁴⁰. ~ 50% to about 10% now, or maybe even lower (although it's hard to get an exact number). Countermeasures include carefully removing all cortical strands from the equator of the capsule, incorporating sharp edges into the optics of the intraocular lens implant, and possibly choosing an appropriate lens material. There have been two major innovations in intraocular lens design.

Until recently, these lenses had spherical front and back surfaces. Light passing through the peripheral portion of such a spherical lens is diffracted more than light passing through the central portion, resulting in poor image quality (“spherical aberration”). Aspheric lenses have been the standard for decades in fields such as microscopy, astronomy, and photography. Some aspheric intraocular lenses are currently available and do not add or remove the eye's spherical aberration. Other lenses are designed to counteract the degree of positive spherical aberration present in most corneas. This improves image contrast in low light, but there is evidence that lower degrees of spherical aberration improve eye function. For example, some spherical aberration enhances the depth of field and reduce uncorrected reading acuity in patients with intraocular lenses designed to keep the eye free of aberrations. Another important aspect of the new lens design is the attempt to provide far, intermediate, and near vision without glasses. Bifocal or multifocal intraocular lenses have been in use for 20 years, but the latest version has significantly reduced side effects compared to previous designs, allowing many patients to become spectacle-free.

It seems that Due to competing interests, the authors have no direct financial relationship, but have received reimbursement for travel and lodging expenses from the company that manufactures intraocular lenses and phacoemulsification devices.

Conclusion-

The goal of this review article is to discuss various issues regarding cataracts. Most cataracts are brought on by the eye lens becoming older. Because new lens fibers continue to be laid down in the lens of the eye rather than replacing old ones, the lens is one of the few body structures that continues to grow throughout life. One of the most common surgeries worldwide is intraocular lens (IOL) cataract surgery with the transplantation of cataracts. Population growth, population aging, urbanization, sedentary lifestyles, and an increasing number of obese diabetics are contributing factors. Worldwide penetration of diabetes was estimated at 2.8% in 2000 It is expected to reach 4.4% by 2030.

Conflicts of interest-

There are no conflicts of interest or disclosures regarding the manuscript.

Acknowledgment-

The authors sincerely thank Dr. Vithalrao Vikhe Patil Foundation's College of Pharmacy, Ahmednagar, University Libraries, and all other sources for their cooperation and advice in writing this review.

References-

1. Feng L, Azhati G, Li T, Liu F. Macular vascular density changes following cataract surgery in diabetic patients: An optical coherence tomography angiography study. *J Ophthalmol.* 2021;2021.
2. Hong Y, Li H, Sun Y, Ji Y. A Review of Complicated Cataract in Retinitis Pigmentosa: Pathogenesis and Cataract Surgery. Vol. 2020, *Journal of Ophthalmology.* Hindawi Limited; 2020.
3. Fernández J, Rodríguez-Vallejo M, Martínez J, Tauste A, Piñero DP. From presbyopia to cataracts: A critical review on dysfunctional lens syndrome. Vol. 2018, *Journal of Ophthalmology.* Hindawi Limited; 2018.
4. Tewari D, Samoila O, Gocan D, Mocan A, Moldovan C, Devkota HP, et al. Medicinal plants and natural products used in cataract management. Vol. 10, *Frontiers in Pharmacology.* Frontiers Media S.A.; 2019.
5. Prokofyeva E, Wegener A, Zrenner E. Cataract prevalence and prevention in Europe: A literature review. Vol. 91, *Acta Ophthalmologica.* 2013. p. 395–405.
6. Auffarth GU, Gerl M, Tsai L, Janakiraman DP, Jackson B, Alarcon A, et al. Clinical evaluation of a new monofocal IOL with enhanced intermediate function in patients with cataracts. *J Cataract Refract Surg.* 2021 Feb 1;47(2):184–91.

7. Lim LL, Morrison JL, Constantinou M, Rogers S, Sandhu SS, Wickremasinghe SS, et al. Diabetic Macular Edema at the time of Cataract Surgery trial: a prospective, randomized clinical trial of intravitreal bevacizumab versus triamcinolone in patients with diabetic macular edema at the time of cataract surgery – preliminary 6-month results. *Clin Exp Ophthalmol*. 2016 May 1;44(4):233–42.
8. Nathan G Congdon. Prevention strategies for age-related cataract: present limitations and future possibilities. *WORLD VIEW* (Series editor: Emmett T Cunningham Jr) [Internet]. 2001;85(02):516–20. Available from: www.bjophthalmol.com
9. Ma LY, Rong A, Jiang Y, Deng SY. Effects of Femtosecond Laser-Assisted Cataract Surgery on Macular and Choroidal Thickness in Diabetic Patients. *Ophthalmol Ther*. 2021 Mar 1;10(1):137–50.
10. Nampradit K, Kongsap P. The visual outcomes and complications of manual small incision cataract surgery and phacoemulsification: long term results. *Rom J Ophthalmol*. 2021 Apr 15;65(1):31–7.
11. Panozzo G, Mura GD, Franzolin E, Giannarelli D, Albano V, Alessio G, et al. Early DMO: a predictor of poor outcomes following cataract surgery in diabetic patients. The DICAT-II study. *Eye (Basingstoke)*. 2022 Aug 1;36(8):1687–93.
12. Chu CJ, Johnston RL, Buscombe C, Sallam AB, Mohamed Q, Yang YC. Risk Factors and Incidence of Macular Edema after Cataract Surgery A Database Study of 81984 Eyes. *Ophthalmology*. 2016;123(2):316–23.
13. Chu CJ, Johnston RL, Buscombe C, Sallam AB, Mohamed Q, Yang YC. Risk Factors and Incidence of Macular Edema after Cataract Surgery A Database Study of 81984 Eyes. *Ophthalmology*. 2016;123(2):316–23.
14. Sheppard WEA, McCarrick D, Wilkie RM, Barnabas RC, Coats RO. A Systematic Review of the Effects of Second-Eye Cataract Surgery on Motor Function. *Frontiers in Aging*. 2022 Jun 22;3.
15. Jain S, Rajshekar K, Aggarwal A, Chauhan A, Gauba VK. Effects of cataract surgery and intra-ocular lens implantation on visual function and quality of life in age-related cataract patients: A systematic review protocol. *Syst Rev*. 2019 Aug 13;8(1).
16. Sheppard WEA, McCarrick D, Wilkie RM, Barnabas RC, Coats RO. A Systematic Review of the Effects of Second-Eye Cataract Surgery on Motor Function. *Frontiers in Aging*. 2022 Jun 22;3.
17. Ma LY, Rong A, Jiang Y, Deng SY. Effects of Femtosecond Laser-Assisted Cataract Surgery on Macular and Choroidal Thickness in Diabetic Patients. *Ophthalmol Ther*. 2021 Mar 1;10(1):137–50.
18. Mahmoud NA, Naguib Elmoteey G, Hamdy AM, Alyan AM. conditions of the Creative Commons Attribution (CC BY-SA) license (<http://creativecommons.org/licenses/by/4.0/>) Cataract Surgery Techniques and Effects in Mature Senile Cataract: Review Article [Internet]. Vol. 85, *The Egyptian Journal of Hospital Medicine*. 2021. Available from: <https://ejhm.journals.ekb.eg/>
19. Jain S, Rajshekar K, Aggarwal A, Chauhan A, Gauba VK. Effects of cataract surgery and intra-ocular lens implantation on visual function and quality of life in age-related cataract patients: A systematic review protocol. *Syst Rev*. 2019 Aug 13;8(1).

20. Chan LKY, Lin SS, Chan F, Ng DSC. Optimizing treatment for diabetic macular edema during cataract surgery. *Front Endocrinol (Lausanne)* [Internet]. 2023 Jan 25;14. Available from: <https://www.frontiersin.org/articles/10.3389/fendo.2023.1106706/full>
21. Chan LKY, Lin SS, Chan F, Ng DSC. Optimizing treatment for diabetic macular edema during cataract surgery. *Front Endocrinol (Lausanne)* [Internet]. 2023 Jan 25;14. Available from: <https://www.frontiersin.org/articles/10.3389/fendo.2023.1106706/full>
22. Ikegami Y, Takahashi M, Amino K. Evaluation of choroidal thickness, macular thickness, and aqueous flare after cataract surgery in patients with and without diabetes: A prospective randomized study. *BMC Ophthalmol*. 2020 Mar 14;20(1).
23. Kaur A, Gupta V, Christopher AF, Malik MA, Bansal P. Nutraceuticals in the prevention of cataract – An evidence-based approach. Vol. 31, *Saudi Journal of Ophthalmology*. Elsevier B.V.; 2017. p. 30–7.
24. Mahmoud NA, Naguib Elmoteey G, Hamdy AM, Alyan AM. conditions of the Creative Commons Attribution (CC BY-SA) license (<http://creativecommons.org/licenses/by/4.0/>) Cataract Surgery Techniques and Effects in Mature Senile Cataract: Review Article [Internet]. Vol. 85, *The Egyptian Journal of Hospital Medicine*. 2021. Available from: <https://ejhm.journals.ekb.eg/>
25. Mahmoud NA, Naguib Elmoteey G, Hamdy AM, Alyan AM. conditions of the Creative Commons Attribution (CC BY-SA) license (<http://creativecommons.org/licenses/by/4.0/>) Cataract Surgery Techniques and Effects in Mature Senile Cataract: Review Article [Internet]. Vol. 85, *The Egyptian Journal of Hospital Medicine*. 2021. Available from: <https://ejhm.journals.ekb.eg/>
26. Davis G. The Evolution of Cataract Surgery. *Science of Medicine*. 2016;10(25):58–62.
27. Alimaw YA, Hussen MS, Tefera TK, Yibekal BT. Knowledge about cataracts and associated factors among adults in Gondar town, northwest Ethiopia. *PLoS One*. 2019 Apr 1;14(4).
28. Alimaw YA, Hussen MS, Tefera TK, Yibekal BT. Knowledge about cataracts and associated factors among adults in Gondar town, northwest Ethiopia. *PLoS One*. 2019 Apr 1;14(4).
29. Ronald Yeoh. CATARACT SURGERY [Internet]. Vol. 12. *APACRS Principles of Preferred Practice*; 2011. 1–14 p. Available from: www.apacrs.org
30. Hoffer KJ, Savini G. Update on Intraocular Lens Power Calculation Study Protocols: The Better Way to Design and Report Clinical Trials. *Ophthalmology*. 2021 Nov 1;128(11):e115–20.
31. Kaur A, Gupta V, Christopher AF, Malik MA, Bansal P. Nutraceuticals in the prevention of cataract – An evidence-based approach. Vol. 31, *Saudi Journal of Ophthalmology*. Elsevier B.V.; 2017. p. 30–7.
32. Llop SM, Papaliadis GN. Cataract Surgery Complications in Uveitis Patients: A Review Article. *Semin Ophthalmol*. 2018 Jan 2;33(1):64–9.
33. Almansour AF, Alomar MA, Bahader AM, Shaynawy HM, Alotaibi SB, Alshahrani AS, et al. An Overview on Clinical Presentation and Diagnostic Approach of Cataract in Primary Healthcare Center. *International Journal Of Pharmaceutical Research And Allied Sciences*. 2022 Jan 1;10(4):52–6.

34. Taís Rena Ta Ribeira Pa Rede. Quality of vision in refractive and cataract surgery, indirect measurers: review article. *Artigo de Revisão*. 2012;6(76):1–5.
35. Chen XY, Song WJ, Cai HY, Zhao L. Macular edema after cataract surgery in diabetic eyes evaluated by optical coherence tomography. *Int J Ophthalmol*. 2016 Jan 18;9(1):81–5.
36. Bhadikar AS, Galphade R, Joshi S, Beke N. Effect of uneventful phacoemulsification cataract surgery in diabetic and non-diabetic patients on central macular thickness: A comparative study. *MedPulse International Journal of Ophthalmology* [Internet]. 2019;11(1):09–14. Available from: https://medpulse.in/Ophthalmology/html_10_1_3.php
37. Furino C, Boscia F, Niro A, D’addario M, Grassi MO, Saglimbene V, et al. DIABETIC MACULAR EDEMA AND CATARACT SURGERY Phacoemulsification Combined With Dexamethasone Intravitreal Implant Compared With Standard Phacoemulsification. Vol. 41, *RETINA*. 2021.
38. Nelson ML, Martidis A. Managing cystoid macular edema after cataract surgery. *Cataract surgery and lens implantation*. 2003;14(4):1–5.
39. Chu CJ, Johnston RL, Buscombe C, Sallam AB, Mohamed Q, Yang YC. Risk Factors and Incidence of Macular Edema after Cataract Surgery A Database Study of 81984 Eyes. *Ophthalmology*. 2016;123(2):316–23.
40. Prokofyeva E, Wegener A, Zrenner E. Cataract prevalence and prevention in Europe: A literature review. Vol. 91, *Acta Ophthalmologica*. 2013. p. 395–405.
41. Mahmoud NA, Naguib Elmoteey G, Hamdy AM, Alyan AM. conditions of the Creative Commons Attribution (CC BY-SA) license (<http://creativecommons.org/licenses/by/4.0/>) Cataract Surgery Techniques and Effects in Mature Senile Cataract: Review Article [Internet]. Vol. 85, *The Egyptian Journal of Hospital Medicine*. 2021. Available from: <https://ejhm.journals.ekb.eg/>
42. Mahmoud NA, Naguib Elmoteey G, Hamdy AM, Alyan AM. conditions of the Creative Commons Attribution (CC BY-SA) license (<http://creativecommons.org/licenses/by/4.0/>) Cataract Surgery Techniques and Effects in Mature Senile Cataract: Review Article [Internet]. Vol. 85, *The Egyptian Journal of Hospital Medicine*. 2021. Available from: <https://ejhm.journals.ekb.eg/>
43. Mahmoud NA, Naguib Elmoteey G, Hamdy AM, Alyan AM. conditions of the Creative Commons Attribution (CC BY-SA) license (<http://creativecommons.org/licenses/by/4.0/>) Cataract Surgery Techniques and Effects in Mature Senile Cataract: Review Article [Internet]. Vol. 85, *The Egyptian Journal of Hospital Medicine*. 2021. Available from: <https://ejhm.journals.ekb.eg/>
44. Hoffer KJ, Savini G. Update on Intraocular Lens Power Calculation Study Protocols: The Better Way to Design and Report Clinical Trials. *Ophthalmology*. 2021 Nov 1;128(11):e115–20.
45. West SK, Mu BE, Newland HS, Emmett EA, Taylor HR, et al. Lack of Evidence for Aspirin Use and Prevention of Cataracts. *Arch Ophthalmol* [Internet]. 1987;105(20):1229–32. Available from: <http://archophth.jamanetwork.com/>

46. Nelson ML, Martidis A. Managing cystoid macular edema after cataract surgery. *Cataract surgery and lens implantation*. 2003;14(20):1–5.
47. Allen D, Vasavada A. Clinical review Cataract and surgery for cataract. *BMJ Publication* [Internet]. 2006;333(15):1–5. Available from: www.v2020.org/main_page.asp
48. Congdon NG. Prevention strategies for age-related cataracts: Present limitations and future possibilities. Vol. 85, *British Journal of Ophthalmology*. 2001. p. 516–20.
49. Zarei-Ghanavati S. Cataracts in Diabetic Patients: A Review Article. *JOURNAL OF OPHTHALMIC AND VISION RESEARCH* [Internet]. 2008;03(01):52–65. Available from: <https://www.researchgate.net/publication/26587971>
50. Hamdy AM, Alyan AM. conditions of the Creative Commons Attribution (CC BY-SA) license Cataract Surgery Techniques and Effects in Mature Senile Cataract: Review Article Vol. 85, *The Egyptian Journal of Hospital Medicine*. 2021. Available from: <https://ejhm.journals.ekb.eg/>