



# INTERNATIONAL JOURNAL OF CREATIVE RESEARCH THOUGHTS (IJCRT)

An International Open Access, Peer-reviewed, Refereed Journal

## Bilateral Lens Ectopia In Marfan Syndrome.

Manal TABCHI, Zeinebou Hmeimett, abdellah amazouzi, noureddine boutimzine, lalla ouafa cherkaoui  
Université Mohammed V, Ophtalmologie A, Hôpital des Spécialités, Rabat, Maroc.

**Abstract:** Ocular manifestations of Marfan syndrome are common, the most frequent being ectopia of the lens. We report the case of a 5-year-old child with bilateral crystalline ectopia.

### INTRODUCTION

Ocular manifestations of Marfan syndrome are common, the most frequent being ectopia of the lens [1].

### observation

We report the case of a 5-year-old child from a consanguineous marriage, with no particular pathological history, admitted for a bilateral visual acuity drop limited to near finger count. Slit-lamp examination revealed a clear cornea with good anterior chamber depth and bilateral crystalline ectopia. Fundus examination revealed a physiologically excavated papilla with good foveolar reflex and no peripheral degenerative lesions. A general examination was ordered, revealing an elongated morphotype and arachnodactyly, consistent with Marfan syndrome, with no other malformations.

The child benefited from phacophagia with correction of aphakia by glasses, and follow-up for treatment of amblyopia.

### conclusion

Crystalline ectopias are often part of the symptoms of hereditary conditions such as Marfan's disease [2]. The discovery of a case requires etiological investigation and family screening.

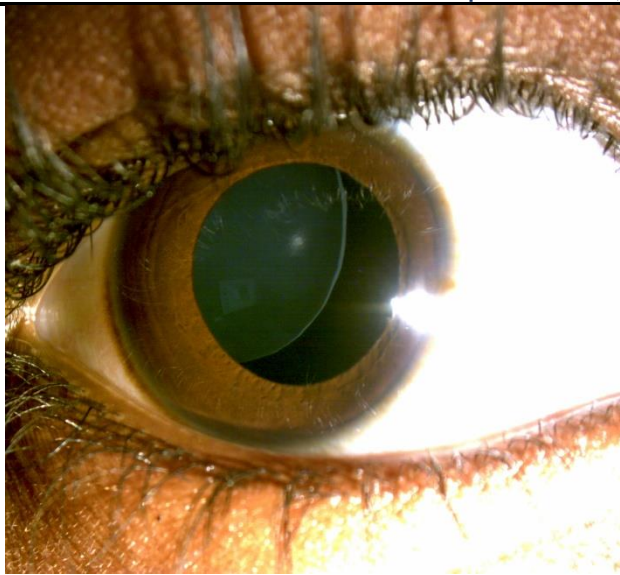


Figure 1 : crystalline ectopia of the right eye

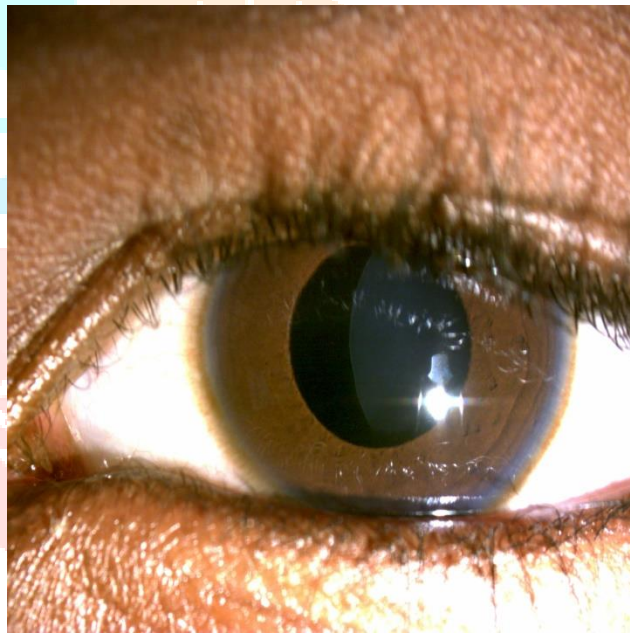


Figure 2 : crystalline ectopia of the left eye

## REFERENCES

- [1] Kanski. Ophtalmologie Clinique Salmon, John F., MD, FRCS, FRCOphth. Publié January 1, 2021. © 2021.
- [2]. Bui Quoc Réfractions, Chapitre 2, 69-99
- [3] Ophtalmologie. Robert, M.; Dénier, C.. Publié March 1, 2024. Volume 41, Issue 1. Pages 1-11. © 2023.