



Unlocking The Healing Potential Of Homeopathy In Management Of Herpes Zoster: A Case Solved With Keynote Prescription

Dr.Nisha Arvind Wanage

Associate Professor Department of Homoeopathic Materia Medica Hamsa Homeopathy Medical College, Hospital & Research Centre Ksheerasagar(V), Mulugu(M), Siddipet(D), Telangana, India.

Dr. Yashwanthi Nalla

Intern Batch 2018, Hamsa Homeopathy Medical College, Hospital & Research Centre Ksheerasagar(V), Mulugu(M), Siddipet(D), Telangana, India.

ABSTRACT -

The *Varicella-zoster* virus (VZV) or human herpes virus 3 is a neurotropic human alpha herpes virus responsible for chickenpox/varicella and shingles/*Herpes zoster* (HZ). This review will focus on HZ. Since HZ is secondary to varicella, its incidence increases with age. In children and youngsters, HZ is rare and associated to metabolic and neoplastic disorders. In adults, advanced age, distress, other infections (such as AIDS or COVID-19), and immunosuppression are the most common risk factors. HZ reactivation has recently been observed after COVID-19 vaccination. The disease shows different clinical stages of variable clinical manifestations. Some of the manifestations bear a higher risk of complications.

KEYWORDS: Homeopathy, Herpes Zoster, Case Study, Keynote Prescription, Management.

INTRODUCTION -

Herpes zoster, also known as shingles, is a viral syndrome caused by reactivation of the varicella-zoster virus. After an episode of varicella (chicken-pox), the varicella-zoster virus remains dormant in the nervous system. Herpes zoster typically occurs in adults or elderly.

The varicella-zoster virus is a neurotropic human herpes virus belonging to the genus *alpha herpesviridae*. It shows a worldwide distribution. The virus is responsible for primary infection resulting in herpes zoster representing a reactivation of latent infection. The varicella-zoster virus genome consists of about 125,000 base pairs of linear double-stranded DNA, and its nucleocapsid consists of 162 capsomers. The virus is highly cell-associated and only infects human cells, such as epithelial cells, T lymphocytes, and ganglionic neurons [1]. Virus entry into neural cells is mediated by heparin sulfate proteoglycan and the glycogen synthase kinase 3 (GSK-3) pathway [2]. Viral core glycoproteins B, H, and L participate in the core fusion complex. New virus particles can be released as soon as 9 to 12 h after cellular entry [3]

Varicella is acquired by airway contact with respiratory droplets or smears from vesicular varicella lesions and is one of the most contagious human disorders. The initial viral replication occurs in the respiratory tract, followed by invasion of local lymph nodes. Eventually, viremia occurs, associated with cutaneous vesicular eruptions. These lesions present a colorful picture of different stages, from early vesiculation to

crusted lesions and possibly scars. Varicella infection in pregnancy can spread via placenta, leading to fetal infection. Fetal varicella infection leads to disseminated life-threatening diseases. Vaccination protects the fetus [4]

INCUBATION PERIOD –

Varies between 10 and 21 days. Varicella is contagious from 1 to 4 days before the cutaneous rash and until all vesicular cutaneous lesions have dried up [5]

After primary infection, the varicella zoster virus becomes latent in neural tissue. Varicella zoster virus has been detected in dorsal root ganglia, cranial nerve ganglia, and various autonomic ganglia in the enteric nervous system, and in astrocytes. Nectin-1, which is highly expressed in neurons, seems to be involved in viral entry of axons and cell bodies [6].

Upon reactivation, varicella zoster virus replicates within cell bodies of neurons. In the next step, virus particles shed from the cell bodies down the nerve to the correlating dermatome. In the affected dermatome, the virus provokes inflammation and vesiculation. The pain caused by herpes zoster is due to inflammation of nerves affected by varicella zoster virus. The herpes zoster does not pose a risk to a developing fetus due to specific maternal antibodies that are transmitted via placenta to the fetus [7].

EPIDEMIOLOGY –

The incidence of herpes zoster ranges from 1.2 to 3.4 per 1000 persons per year among younger healthy individuals while incidence is 3.9 to 11.8 per 1000 persons per year among patients older than 65 years.[8]

CLINICAL FEATURES –

There are 3 clinical stages which explains the disease progression

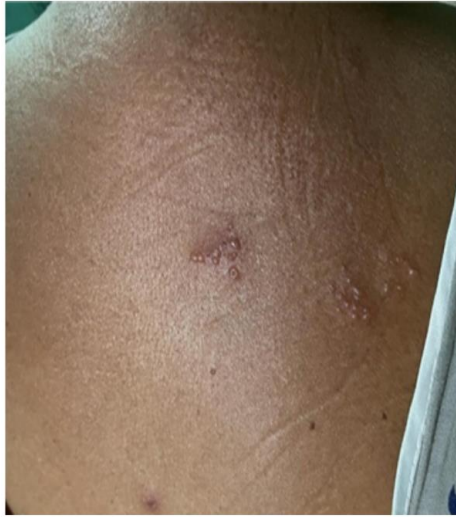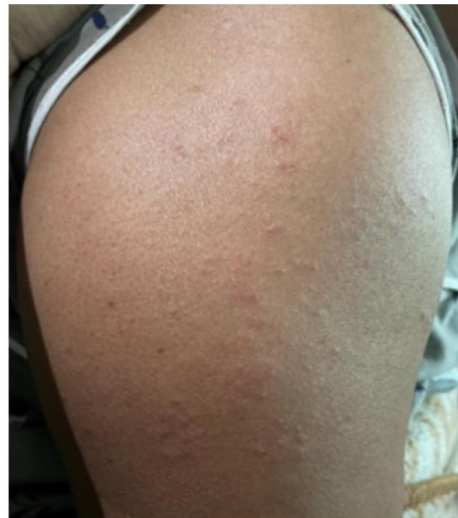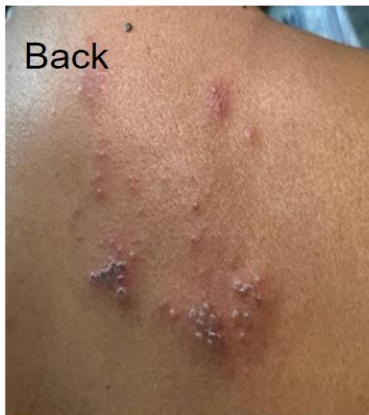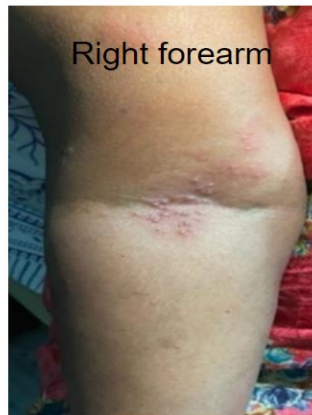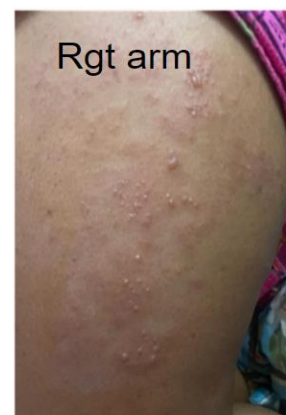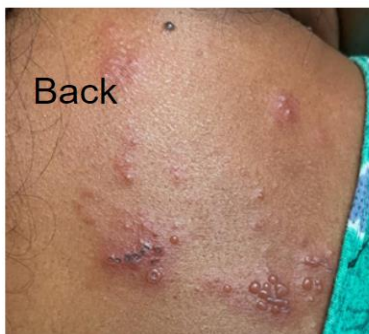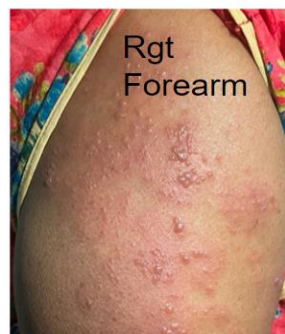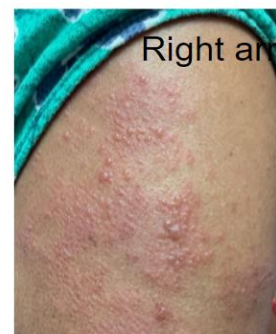1. Pre-eruptive stage presents with abnormal skin sensations or pain within the dermatome affected. This phase appears at least 48 hours prior to any obvious lesions. At the same time, the individual may experience headaches, general malaise, and photophobia.
2. The acute eruptive phase is marked by the vesicles and the symptoms seen in the pre-eruptive phase. The lesions initially start as macules and quickly transform into painful vesicles. The vesicles often rupture, ulcerate and eventually crust over. Patients are most infectious in this stage until the lesion dry out. Pain is severe during this phase and often unresponsive to traditional pain medications. The phase may last 2-4 weeks but the pain may continue.
3. Chronic infection is characterized by recurrent pain that lasts more than 4 weeks. Besides the pain, patients experience paresthesia's, shock-like sensations, and dysesthesias. The pain may last 12 months or longer.

PATIENT INFORMATION –

A 46 years old female presented in OPD on 07-02-2023 with the complaints of small fluid filled blisters with redness on the upper right back (right scapular region) with stinging pain and itching sensation, blisters gradually spreading towards the right arm.

HISTORY OF PRESENTING COMPLAINTS –

The patient was apparently healthy and suddenly developed small fluid filled blisters on the right scapular region with stinging pain and itching with positive signs of inflammation i.e. rubor, tumor, Calor, and dolor. There was H/O an unknown insect bite the day before the blisters appeared. Gradually the blisters have spread to the right arm followed by forearm with relentless stinging pain, itching and dragging pain in the right upper limb. Patient gradually experienced difficulty in raising the arm and with movement restrictions. The pains got aggravated during evenings, night causing disturbed sleep. There is no specific amelioration with cold packs also. In the following days the patient commenced with pyrexia, GI troubles being specific with nausea and diarrhea with 4-5 episodes a day. There was weeping, irritability, generalized weakness imputable to pain.

DAY 1 OF THE PRESENTING COMPLAINT**Back****Arm****PROGRESSION OF THE DISEASE.****Back****Right forearm****Rgt arm****Back****Rgt Forearm****Right arm**

There's H/O chicken pox at the age 6 years, Hypertension since 10 years uses allopathic mode of treatment, Hypothyroidism since 7 years uses allopathic mode of treatment.

LIFE SPACE INVESTIGATION –

Patient hails from upper middle-class family and is the younger daughter to her parents have 2 elder brothers and 2 elder sisters. There were no specific complaints in regards to childhood. She always maintained good interpersonal relations. Got married at the age of 22 years, have 2 kids. She's very joyful, mingles around easily, always helpful to others. Fastidious & strong personality.

PHYSICAL GENERALS –

Her appetite and thirst were moderate but altered due to complaints. Urine and bowels are clear and satisfactory. Sleep disturbed due to pain. Profuse perspiration on head. On view on thermals, she cannot tolerate extremes of cold and hot weathers.

Her menstrual history had no abnormalities, had a regular cycle. In regards to the obstetrics history it's G2P2L2A0 with LCSC.

SYSTEMIC EXAMINATION – DERMATOLOGY – Skin

- UPPER RIGHT LIMB AND BACK – Small fluid filled blisters with redness and mild swelling in inspection. On touch there's warmth and tenderness.

DIAGNOSTIC ASSESSMENT –

Based on the clinical picture and previous h/o varicella virus this case has been diagnosed as Herpes Zoster. The patient had multiple fluid filled blisters on one side of the body with stinging pains, itching, dragging all over the limb, pyrexia, movement restrictions, GI troubles. Normal general and systemic examinations, vitals in range.

CASE PROCESSING –

TOTALITY OF SYMPTOMS –

The symptoms narrated by the patient, as well as the symptoms observed by the physician, were considered for the totality. They are:

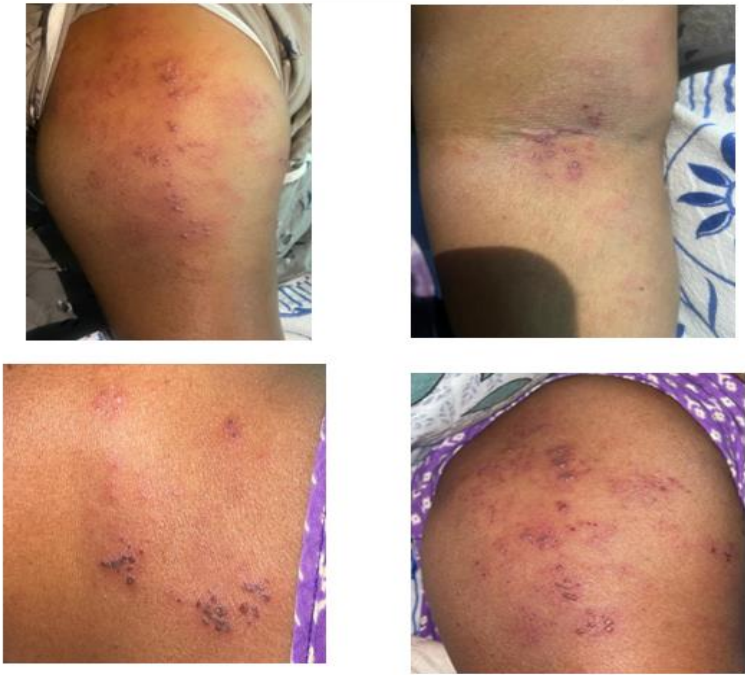- One sided presenting small blister.
- Stinging pains with itching.
- Dragging pain all over the limb.
- Positive signs of inflammation.
- Difficulty raising the arm.
- Pyrexia.
- H/O unknown insect bite.
- Previous history of varicella virus in childhood.

Basing on the totality keynote prescription was chosen.

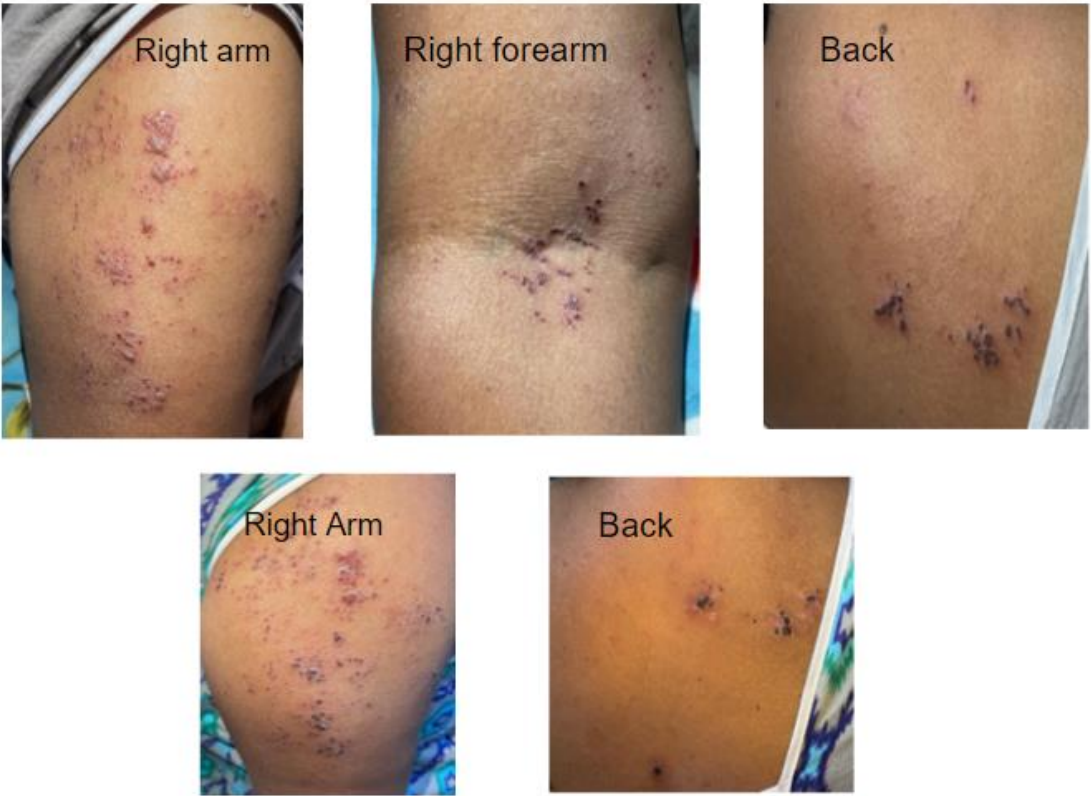
1. Initially on 07-02-2023 Apis Mellifica 200 1 dose was administered as there was h/o insect bite and presenting symptoms were eruptions with redness, mild swelling, stinging pains and itching.
 - RESULTS – Stinging pain slightly got reduced, itching was better. Swelling and redness remained the same.
 - But the eruptions have progressed into painful blisters with severe dragging pain in the upper limb.
2. As Apis have showed some improvement another dose of Apis Mel was administered on 09-02-2023
 - RESULTS – There was no improvement in the symptoms, intensity of the symptoms have increased. Patient developed pyrexia with intense pain in the upper limb with difficult and painful movements of the limb.
 - The blisters have progressed in size with tenderness +, warmth +, swelling +.
 - Systemic manifestation developed – general weakness. GI troubles.
3. At this point a proper conclusion for the diagnosis was made and have administered Rannunculus 30 water dose for every 1 hour on 11-02-2023.
 - RESULTS – pyrexia was regimented. General weakness slightly improved.
 - Swelling gradually reduced than before. The other symptoms were being endured.
4. Following Rannaculus 200 was administered for every 3 hours on 13-02-2023
 - RESULTS – GI symptoms got better. Pyrexia was regimented. General weakness improved.
 - Blisters manifestation was better than before. The dragging pain over the upper limb was slightly better than before. Stinging pain pains better than before and itching was reduced.
 - There was still difficulty in movements.
5. As it has shown relevant improvement Rannanculus 1M was administered on 17-02-2023 for the following days and have shown incredible results. The blisters gradually have dried out and

movements of the limb flattered. There persisted the dragging pain of the limb for a month after the blisters have disappeared.

DURING TREATMENT



DURING RECOVERY



CONCLUSION –

Homeopathy being the best complimentary alternate medical therapy evolves miraculously every time. It gives the best surprises for the treatment which any other mode could not show in the due time in regards with the principles narrated by Dr. Samuel Hahnemann. Homoeopathic remedies have helped the case miraculously when no specialized treatment could cure the varicella virus. In conclusion, the presented case report underscores the potential efficacy of homoeopathic treatment in managing Herpes Zoster. The holistic approach of homoeopathy, addressing all the aspects of the case has showcased a promising result in alleviating the discomfort and improving the overall well-being of the patient.

This case report encourages further exploration and research into the potential benefits of homoeopathy for such medical conditions where a delayed response is being witnessed in other modes of therapies. By embracing the innovative and holistic approaches, we pave the way for a more comprehensive understanding of integrative medicine, offering hope to individuals seeking alternatives for the management of every case possible.

REFERENCES –

1. Gershon A.A., Breuer J., Cohen J.I., Cohrs R.J., Gershon M.D., Gilden D., Grose C., Hambleton S., Kennedy P.G.E., Oxman M.N., et al. Varicella zoster virus infection. *Nat. Rev. Dis. Prim.* 2015;1:15016. doi: 10.1038/nrdp.2015.16. [PMC free article] [PubMed] [CrossRef] [Google Scholar]
2. Li Puma D.D., Marcocci M.E., Lazzarino G., De Chiara G., Tavazzi B., Palamara A.T., Piacentini R., Grassi C. Ca²⁺-dependent release of ATP from astrocytes affects herpes simplex virus type 1 infection of neurons. *Glia.* 2021;69:201–215. doi: 10.1002/glia.23895. [PubMed] [CrossRef] [Google Scholar]
3. Zerboni L., Sen N., Oliver S.L., Arvin A.M. Molecular mechanisms of varicella zoster virus pathogenesis. *Nat. Rev. Genet.* 2014;12:197–210. doi: 10.1038/nrmicro3215. [PMC free article] [PubMed] [CrossRef] [Google Scholar]
4. Kett J.C. Perinatal Varicella. *Pediatr. Rev.* 2013;34:49–51. doi: 10.1542/pir.34.1.49. [PubMed] [CrossRef] [Google Scholar]
5. Marin M., Leung J., Lopez A.S., Shepersky L., Schmid D.S., Gershon A.A. Communicability of varicella before rash onset: A literature review. *Epidemiol. Infect.* 2021;149:1–18. doi: 10.1017/S0950268821001102. [PMC free article] [PubMed] [CrossRef] [Google Scholar]
6. Rajbhandari L., Shukla P., Jagdish B., Mandalla A., Li Q., Ali M.A., Lee H., Lee G., Sadaoka T., Cohen J.I., et al. Nectin-1 Is an Entry Mediator for Varicella-Zoster Virus Infection of Human Neurons. *J. Virol.* 2021;95:e01227-21. doi: 10.1128/JVI.01227-21. [PMC free article] [PubMed] [CrossRef] [Google Scholar]
7. Blumental S., Lepage P. Management of varicella in neonates and infants. *BMJ Paediatr. Open.* 2019;3:e000433. doi: 10.1136/bmjpo-2019-000433. [PMC free article] [PubMed] [CrossRef] [Google Scholar]
8. Nair P.A., Patel B.C. *StatPearls [Internet]* StatPearls Publishing; Treasure Island, FL, USA: 2021. *Herpes zoster* [Google Scholar]