



# ASSESSMENT OF BONE INJURY IN RECURRENT SHOULDER DISLOCATION USING CT AND SURGICAL CORRELATION IN A RURAL HEALTH SET UP

PRESENTING AUTHOR: Dr Nikita Sridhar

CO-AUTHORS: Dr Dayananda Kumar R, Dr Rachegowda, Dr Puttaraju

AFFILIATION: MVJ Medical College and Research Hospital

## INTRODUCTION :

Glenohumeral joint stability has two components- soft tissue and bone support. Adequate soft tissue coverage is required both anteriorly and posteriorly.

Anterior shoulder dislocation frequently causes bone loss on the anterior aspect of the glenoid with fracture of the posterosuperior aspect of the humeral head, known as Hill-Sachs deformity. Glenoid bone loss decreases the glenohumeral contact area which increases joint instability and the possibility of further dislocation. (13)

The anatomy of the glenoid cavity is intricate, complex and varies between individuals. Plain CT scan of the shoulder allows us to evaluate the glenoid cavity and its rim, and 3-D reconstruction allows both the radiologist and the surgeon to visualise the defect on a bony model. 3D reconstructed images gives us the maximum amount of information regarding details of osseous injury and its severity. (4,5,6,7)

The evaluation of osseous injury and glenoid bone loss helps the surgeon to select the most appropriate treatment - be it arthroscopic procedures such as arthroscopic soft tissue stabilisation or open procedures, or whether bone grafting is required.

## AIMS & OBJECTIVES:

1. To determine the percentage of bone loss using 3 dimensional CT.
2. To study degree of accuracy of preoperative CT imaging in relation to surgical intervention and findings.

## MATERIALS AND METHODS:

**Source of data:** Patients coming to Orthopedics department in MVJ Medical College and Research Hospital for unilateral recurrent shoulder dislocation from August 2022 to December 2023.

**Method of collection of data:** 30 patients enrolled after taking informed consent. Patients with unilateral recurrent shoulder dislocation presenting to Radiology Department for CT shoulder

**Study design:** Prospective study

**Material:** NCCT study of shoulder joint at MVJ MC & RH using GE Bravo 16 slice CT machine

**Sample:** Patients attending MVJ Medical College and Research Hospital, Hoskote, Bangalore, Karnataka.

**Time period:** 16 months

**Sample size: 30 cases**

**Inclusion criteria:**

1. Patients with recurrent, unilateral shoulder dislocation, occurring more than or equal to 3 times
2. Patients who are willing for surgical management.

**Exclusion criteria:**

1. Patients who have previously undergone surgery on the affected side.
2. Patients with bilateral recurrent shoulder dislocation
3. Patients with contraindications for CT scanning, such as pregnancy.
4. Patients who have epilepsy or seizure disorder.

**Method:**

3D reconstructions of the humeral head and glenoid of both shoulder joints with 16 slice scans converted to 3-D CT reconstructions by combined standard and bone algorithms were performed.

Linear method used to calculate the amount of bone loss of the injured glenoid compared to the uninjured contralateral glenoid.

The first step in the process was obtaining an en face view of the uninjured glenoid with the 3-D CT scan. The most superior aspect of the glenoid is labeled as A1. The most inferior aspect of the glenoid is the farthest point from A1 and is labeled B1. A line is then drawn connecting A1 to B1 (A1B1). The line A1B1 corresponds to the normal glenoid height (H1) of the uninjured shoulder (A1B1 = H1).

The second line drawn (C1D1) is perpendicular to A1B1 and is adjusted up or down until it is at the widest portion of the inferior glenoid. The line C1D1 corresponds to the normal inferior glenoid width (W1) of the uninjured shoulder (C1D1 = W1).

The intersection of lines A1B1 and C1D1 is labeled O1. The line O1D1 corresponds to the radius of the normal inferior glenoid circle (R1) of the uninjured shoulder (O1D1=R1). The length of the glenoid is measured as the uninjured glenoid and line A2B2 (H2) is drawn. The radius of the inferior glenoid circle was then calculated through basic proportions. Because  $R1/H1 = R2/H2$ , R2 could be calculated by the following formula:  **$R2=(R1/H1)*H2$** .

Therefore, the geometric center of the inferior glenoid circle (O2) could be found a distance equal to R2 from the point B2.

A new line is drawn that crosses point O2 and is perpendicular to line A2B2. This line is labeled C2D2 and represents the inferior width of the injured glenoid (W2).

The predicted preinjury width of the injured glenoid (W2') can then be calculated with the following formula:  **$W2' = (W1/H1)*H2$** .

The glenoid index is calculated as the ratio of the post injury width of the injured glenoid to the preinjury width of the uninjured glenoid using the following formula:  **$\text{glenoid index} = W2/W2'$** .

**RESULTS:****Age distribution:**

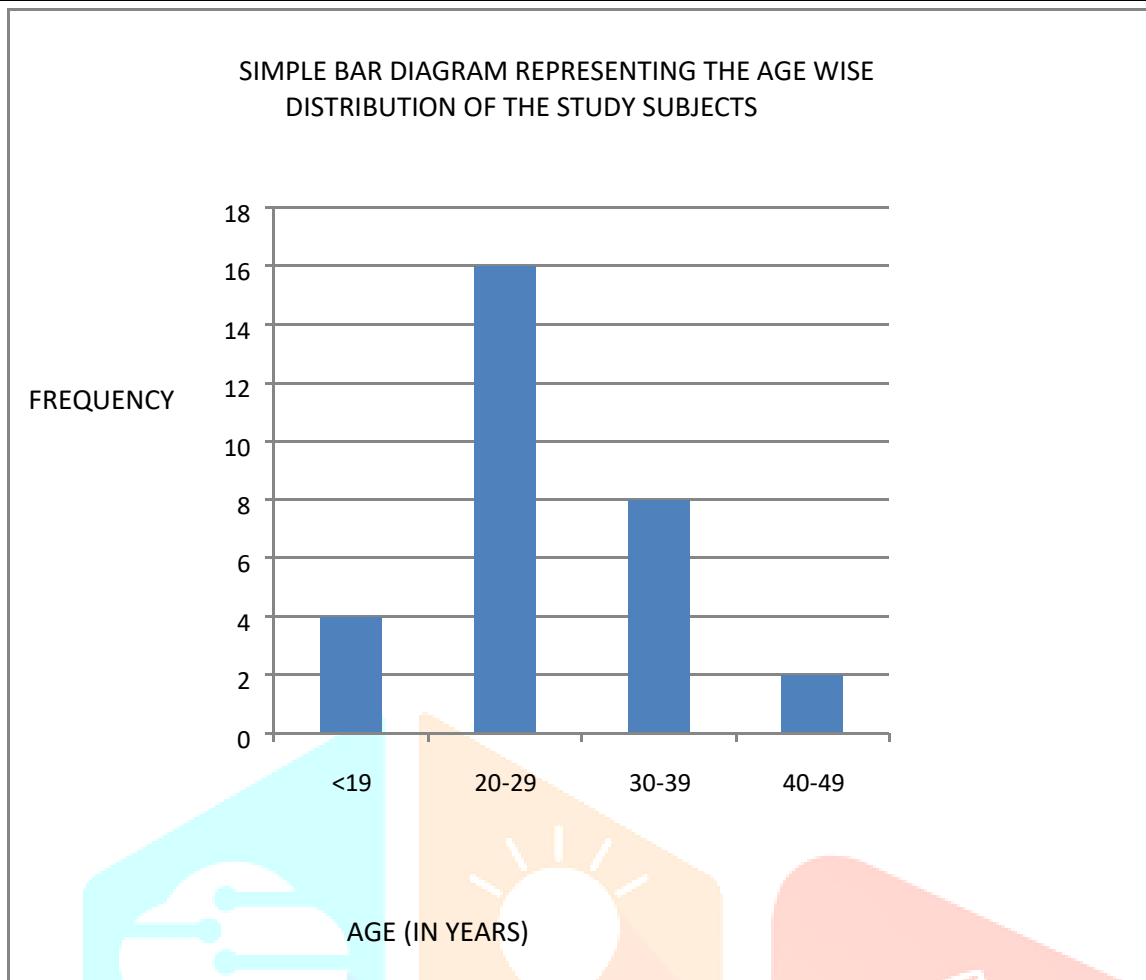
Out of 30 cases, patients below 19yrs of age were 13.3%(4), 20-29 years of age - 53.3%(16), 30-39 yrs of age - 26.7%(8), 40-49years of age - 6.7%(2).

**Table 1: Age distribution chart**

Age (in years)	Frequency	Percent
<19	4	13.3
20-29	16	53.3
30-39	8	26.7
40-49	2	6.7
Total	30	100.0

**Descriptive Statistics**

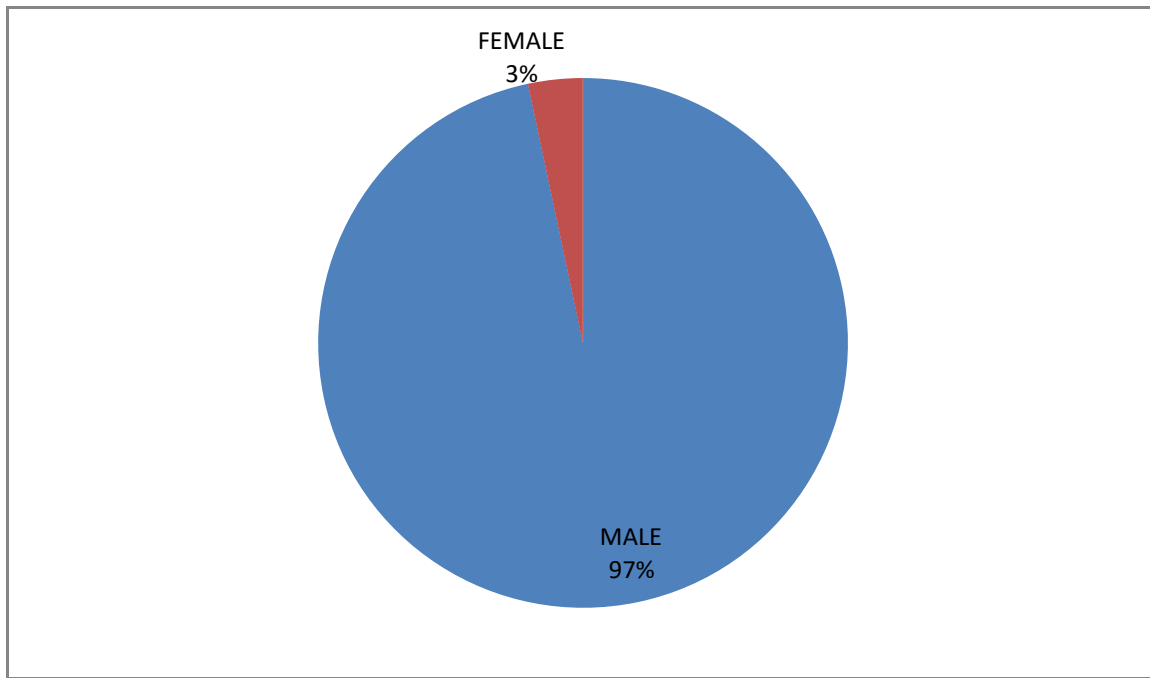
	N	Minimum	Maximum	Mean	Std. Deviation
AGE	30	17	47	27.37	7.223



**Chart 1: Age distribution chart**

**Table 2: Gender distribution**

GENDER	NO OF CASES	%AGE
MALE	28	93.33
FEMALE	2	6.66
TOTAL	30	100



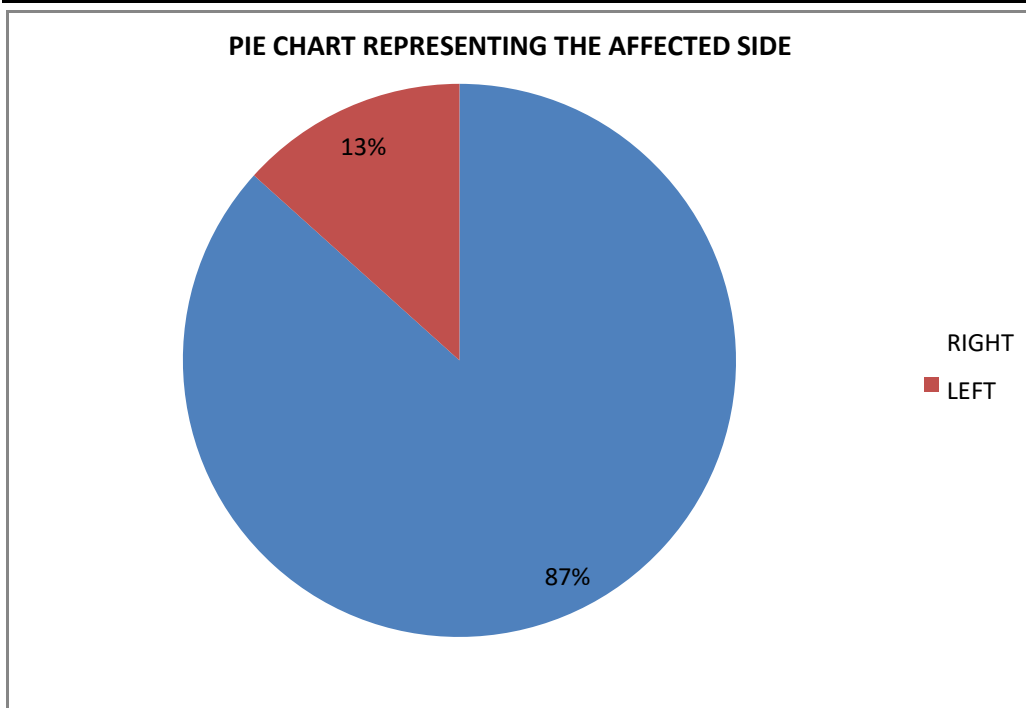
**Chart 2: Gender distribution**

**Side Involved**

86.7% (28) of the subjects were affected on the right and 13.3%(4) were affected on the left.

**Table 3: Side Involved**

Side	Frequency	Percent
T RIGH	26	86.7
LEFT	4	13.3
Total	30	100.0



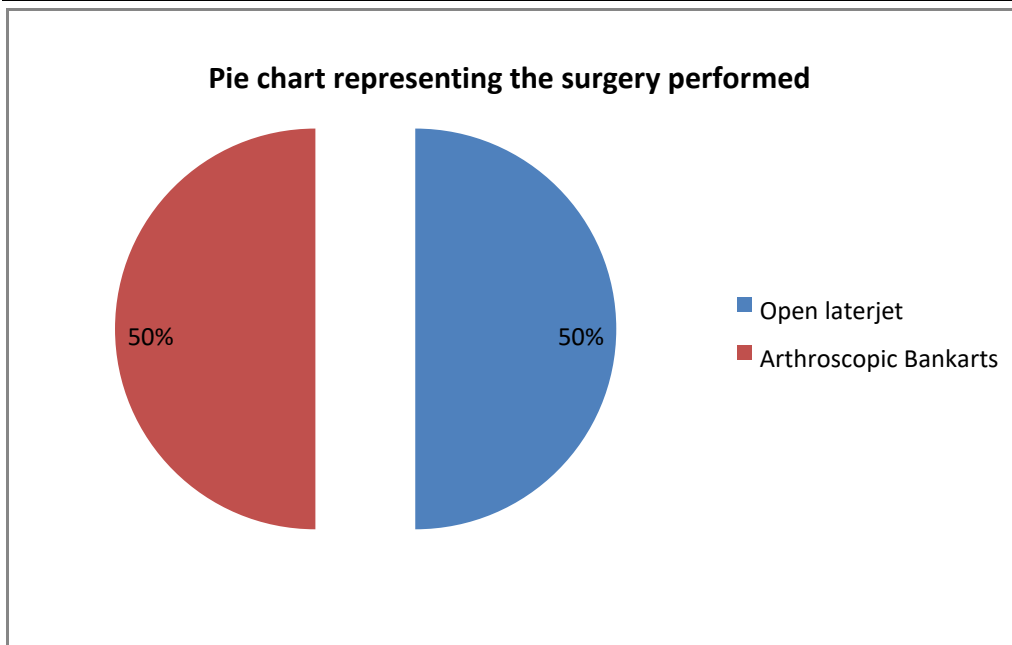
**Chart 3: Side Involved**

### Types of Surgery performed

50% (15) of the patients underwent an Arthroscopic Bankarts repair and the remaining 50%(15) underwent an Open Laterjet procedure.

**Table 4: Types of Surgery performed**

<b>SURGERY</b>	<b>Frequency</b>	<b>Percent</b>
Arthroscopic Bankart	15	50.0
Open Laterjet	15	50.0
Total	30	100.0



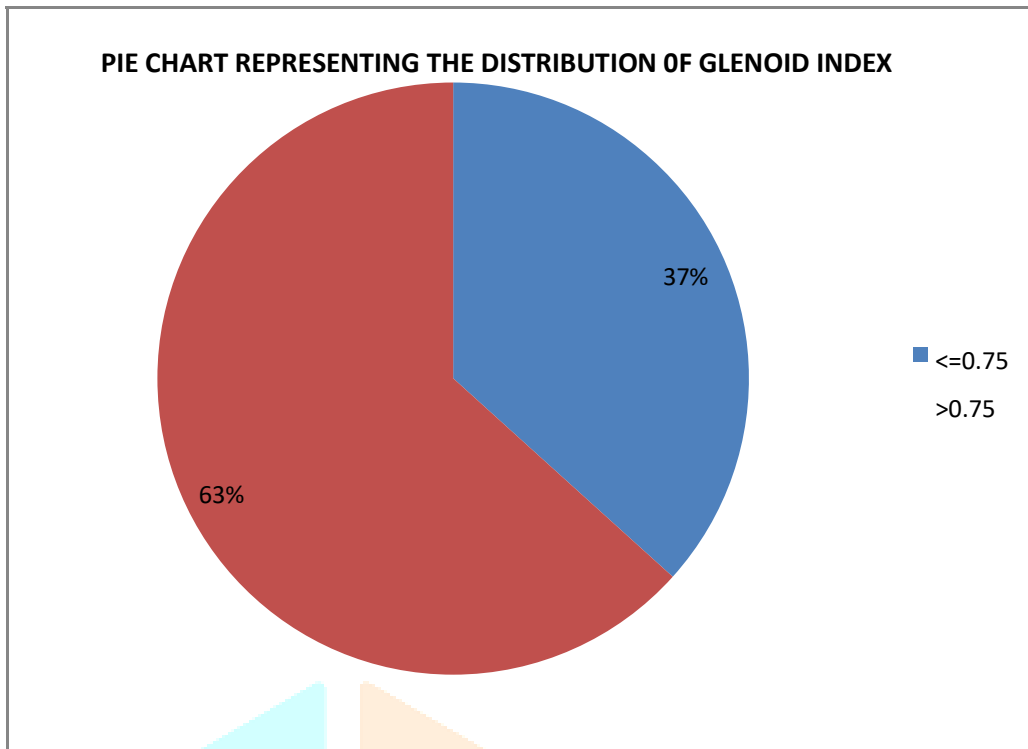
**Figure 4: Types of Surgery performed**

#### Glenoid Index

63.3% (19) of the patients had a glenoid index of more than 0.75 and 36.7%(11) .

**Table 5: Glenoid Index**

GLENOID INDEX	Frequency	Percent
Valid <=.75	11	36.7
>.75	19	63.3
Total	30	100.0



**Chart 5: Glenoid Index**

**Group Statistics**

	<b>GROUP</b>	<b>N</b>	<b>Mean</b>	<b>Std. Deviation</b>	<b>Std. Error Mean</b>
W2	OPEN LATERJET	14	2.268	.9029	.2413
	ARTHROSCOPIC	16	1.831	.8948	.2237
W2'	OPEN LATERJET	14	3.1986	1.66556	.44514
	ARTHROSCOPIC	16	1.9806	.96239	.24060
GI	OPEN LATERJET	14	.6836	.09476	.02533
	ARTHROSCOPIC	16	.8886	.04603	.01151



**Ranks**

	<b>GROUP</b>	<b>N</b>	<b>Mean Rank</b>	<b>Sum of Ranks</b>
W2	OPEN LATERJET	14	17.64	247.00
	ARTHROSCOPIC	16	13.63	218.00
	Total	30		
W2'	OPEN LATERJET	14	19.57	274.00
	ARTHROSCOPIC	16	11.94	191.00
	Total	30		
GI	OPEN LATERJET	14	8.43	118.00
	ARTHROSCOPIC	16	21.69	347.00
	Total	30		

W2 (P>0.05 NON SIGNIFICANT)

W2' (P<0.05 SIGNIFICANT DIFFERENCE IN W2' BETWEEN 2 SURGERIES PERFORMED)

GI (P<0.001 VERY HIGH SIGNIFICANT DIFFERENCE IN G INDEX BETWEEN THE 2 SURGERIES PERFORMED)

**Percentage bone loss**

63.3% (19) had a percentage bone loss of less than 25% and 36.7%(11) had a percentage bone loss of more than 25%.

**Table 6: Percentage bone loss**

	<b>Frequency</b>	<b>Percent</b>
<=25%	19	63.3
>25%	11	36.7
Total	30	100.0

**Post imaging surgery**

11 patients with a GI of less than 0.75 and 4 patients with a GI of more than 0.75 underwent an Open Laterjet procedure(73.3%) 15 patients with GI more than 0.75 underwent an Arthroscopic surgery.

**Table 7: Post imaging surgery**

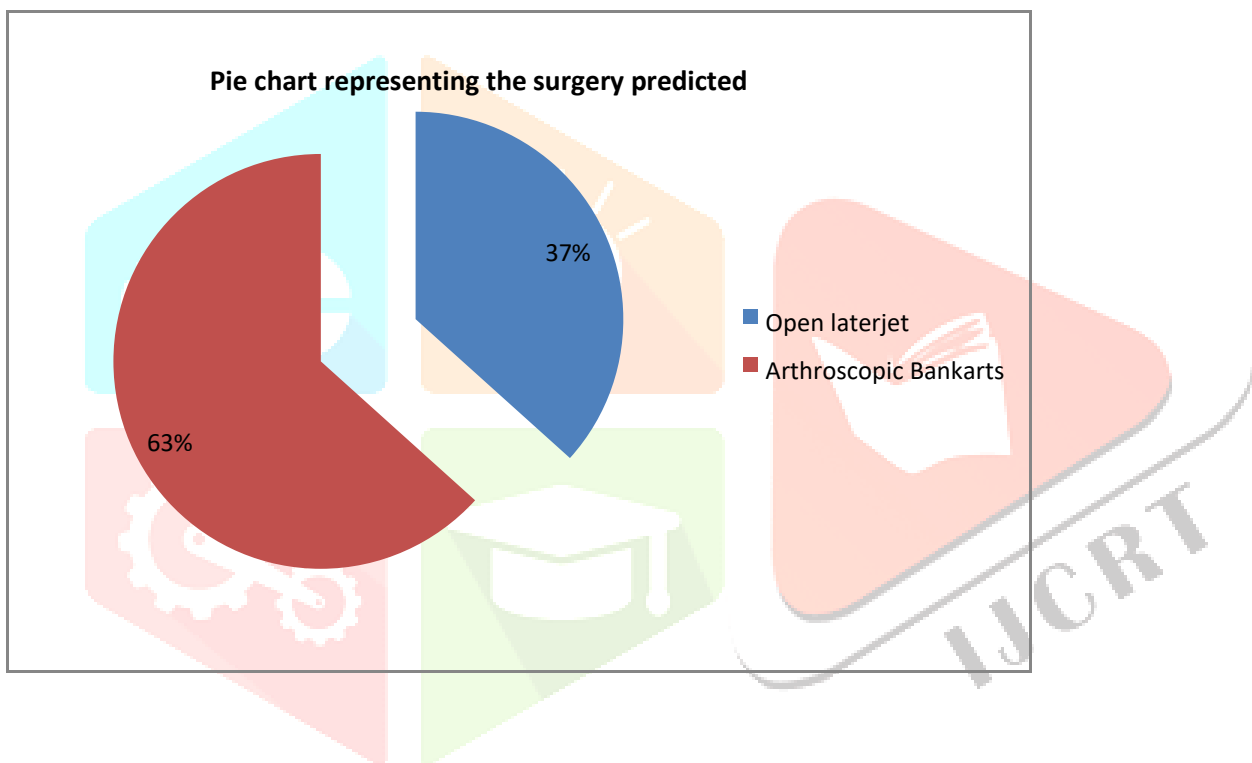
			SURGERY_PERFORMED		Total
			Open Laterjet	Arthroscopic Bankarts	
GLENOID CODED	<=.75	Count	11	0	11
	>.75	Count	4	0	4
Total			100.0%	100.0%	100.0%

**Table 8: Surgery Performed to the predicted surgery Crosstabulation**

			predicted surgery		Total
			open laterjet	arthroscopic	
SURGERY PERFORMED	open laterjet	Count	11	4	15
	arthroscopic	Count	0	0	0
			73.3%	0%	

Total	%	Count		
	%		36.7%	63.3%
				100.0%

Very highly significant. 73.3 % of the open laterjet surgery performed were predicted for open laterjet. P<0.001 Hence vhs association was found between the surgery performed and surgery predicted



**Chart 6: Pie chart representing the surgery predicted**

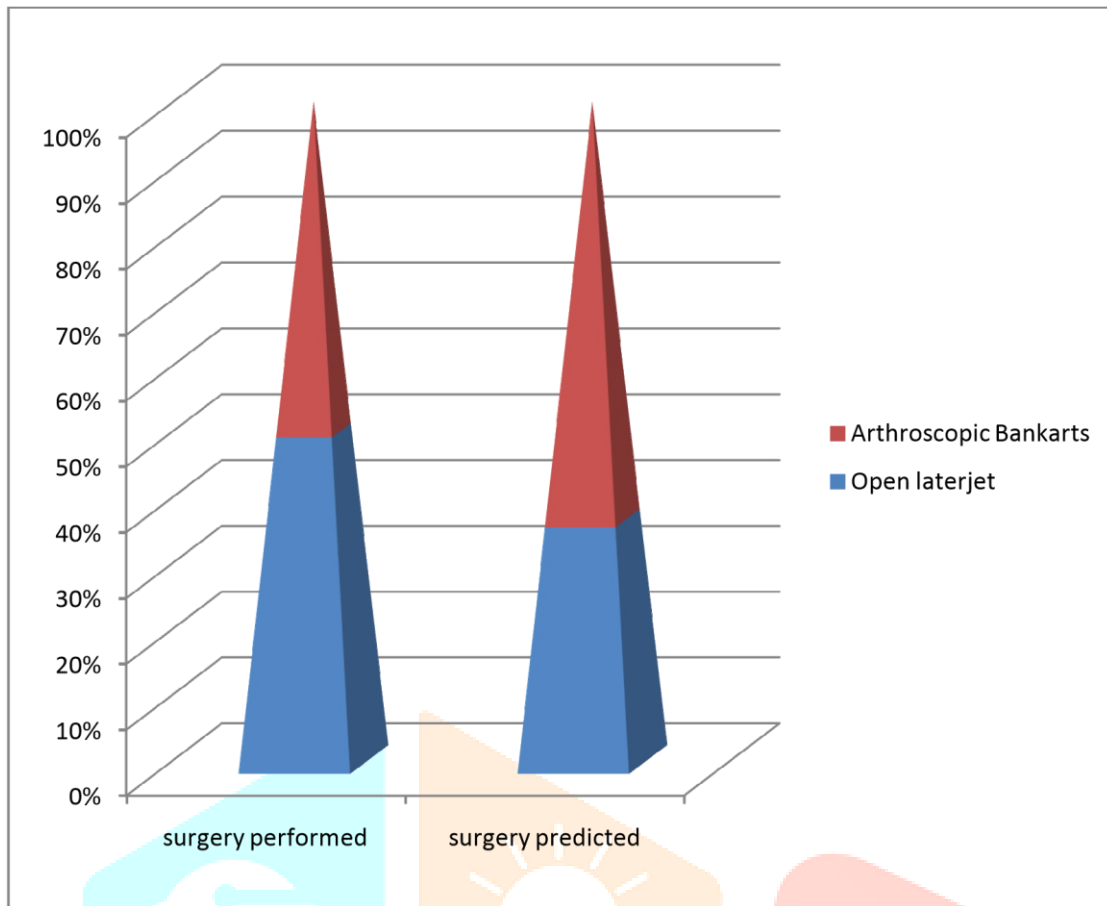
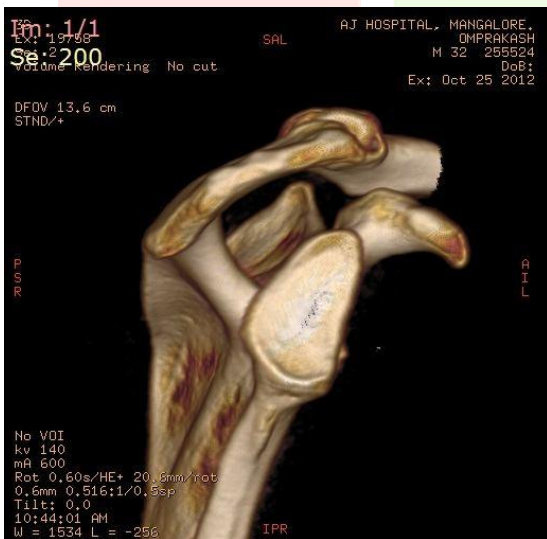

Chart 7: Component bar diagram representing the surgery performed and predicted



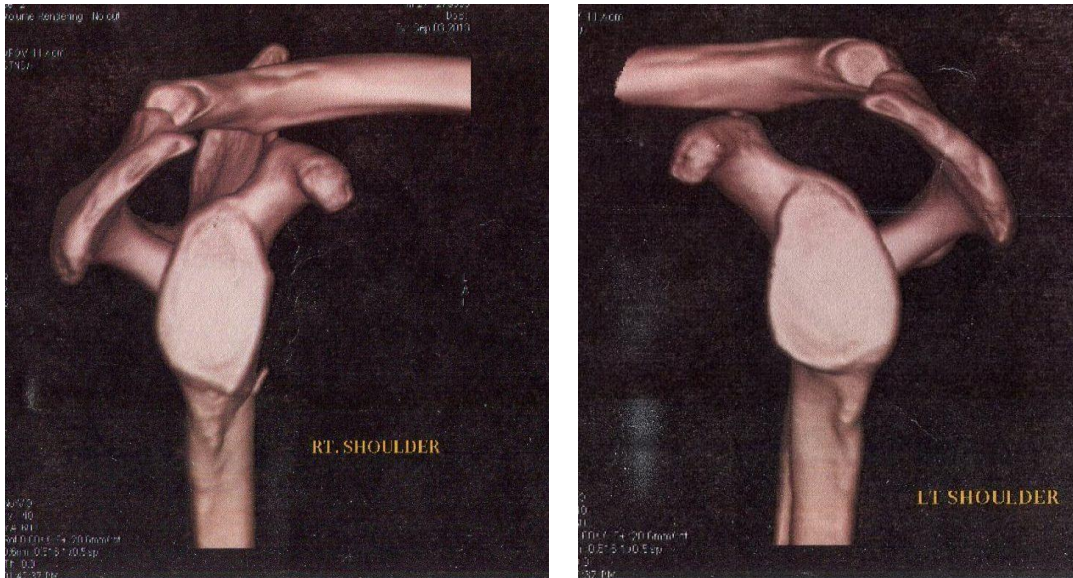
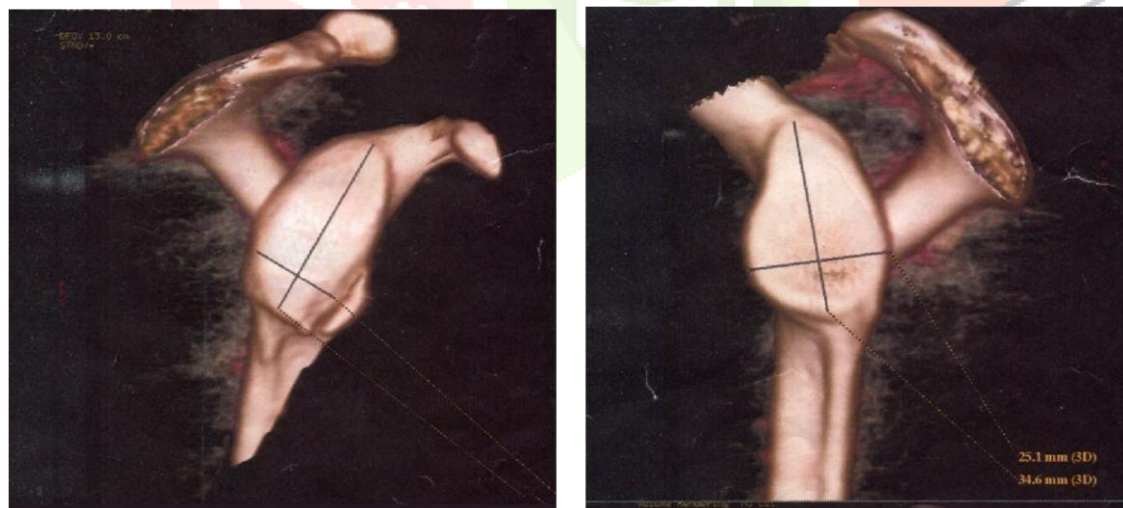


Fig 3.a- 3D reconstruction of affected side showing

bone loss of about 13 %

Fig 3.b- glenoid showing normal contour

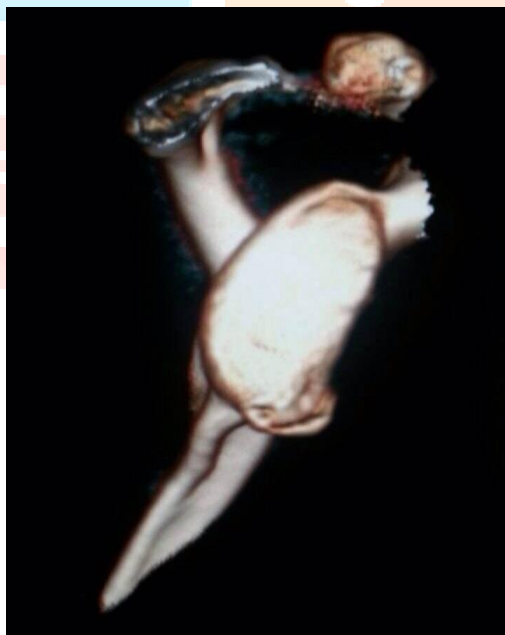
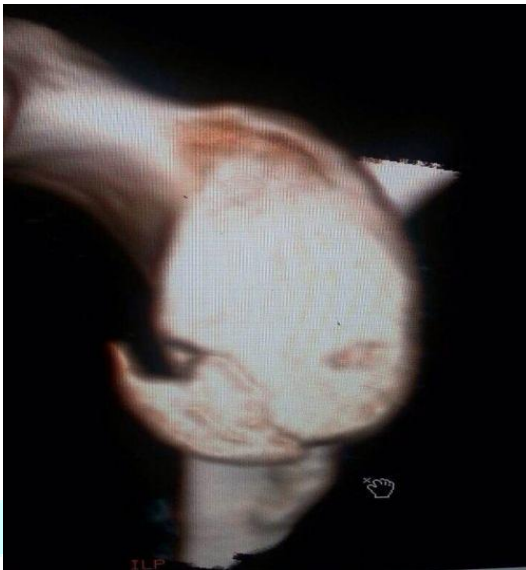3.c-3D reconstruction of the affected side showing bone loss of about 23%



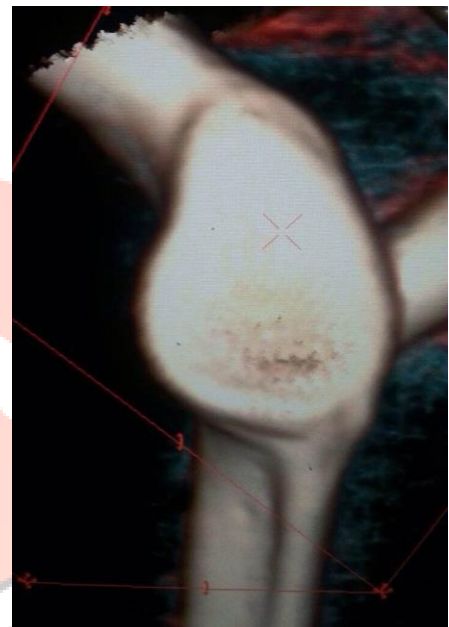**Fig d: 3D reconstruction of the glenoid showing a normal contour**

**Fig e: 3D reconstruction of the affected side showing bone loss of about 11%**

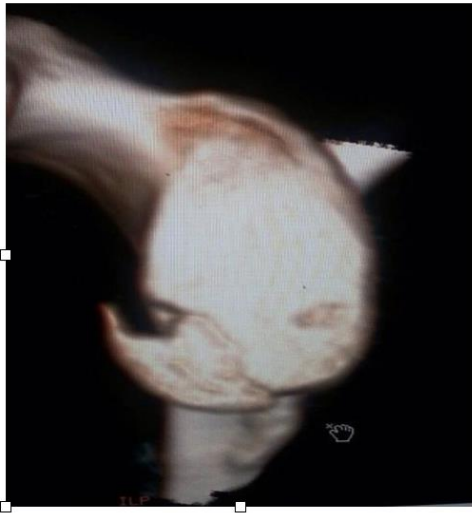**Fig f: 3D reconstruction of the glenoid showing a normal contour**



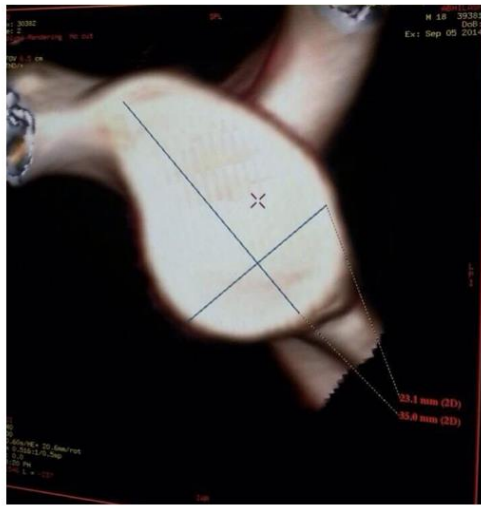
**Fig g: 3D reconstruction of the affected side showing severe bone loss of about 27%**



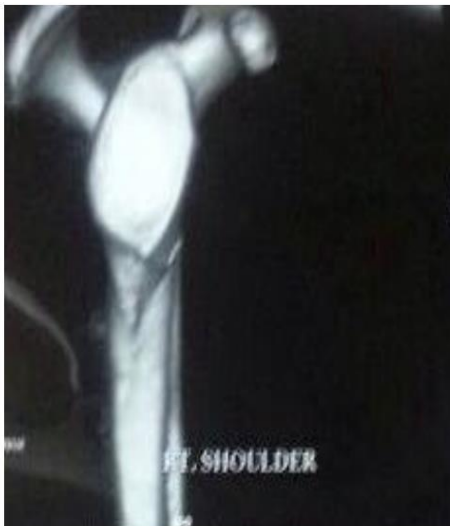
**Fig h: 3D reconstruction of the glenoid showing a normal contour**



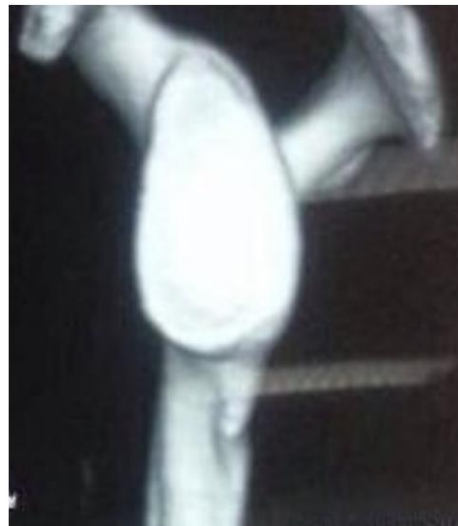**Fig i: 3D reconstruction of the glenoid showing fracture showing the inferior**



**Fig j: 3D reconstruction of the glenoid showing a normal contour aspect**



**Fig k: 3D reconstruction of the affected side showing severe bone loss**



**Fig l: 3D reconstruction of the glenoid showing a normal contour of about 28%**

## DISCUSSION

In this study, indicators of bone loss was evaluated using 3-D CT only, as bone margins are easily identifiable with 3-D imaging.

Defect in the glenoid length measurements were the most accurate with 3-D CT due to clearly demarcated bony endpoints at the start and end of each defect. Although, selecting anatomic landmarks for height and width measurements was more challenging due to natural irregular, nonplanar surface of the glenoid fossa at its most superior and inferior aspects.

This prospective study was carried out in 30 patients who were referred with unilateral recurrent shoulder dislocation from the Department of Orthopedics in MVJ MC & RH. The patients had more than or equal to 3 episodes of shoulder dislocation.

All the patients underwent CT scan with additional scanning of opposite shoulder joint for comparison.

Patients were evaluated for Glenoid Index & percentage bone loss and were subsequently subjected to Arthroscopic surgery or Open Bankarts repair accordingly.

Although patients of all age groups were added in this study, most of the patients in our study belonged to the age group of 20-29yrs (53%) with a mean age of 27.37 and standard deviation of 7.233.

James .F. Griffith et<sup>13</sup> al have shown in their study that recurrent shoulder dislocation is more common in younger patients, with further dislocation occurring in 80% of those younger than 20 years, 60% of those 20–40 years old, and fewer than 15% in those older than 40 years. This study also observed that, Hill-Sachs deformity was not more common ( $p=0.21$ ) but was more severe ( $p = 0.008$ ) in recurrent than in single dislocations. A weak positive correlation was seen between glenoid bone loss and increasing severity of Hill- Sachs deformity ( $r = 0.24$ ,  $p = 0.03$ ). In this study, 14 of the 30 patients had a Hill- Sachs deformity.

In this study, most of the patients had right shoulder involvement (86.7%) compared to the left (13.3%).

Out of 30 patients 8 patients had fracture of the interior glenoid.

In our study of 30 patients, 11 patients(36.7%) were calculated to have a percentage bone loss of more than 25% and 19 patients(63.3%) had a loss of less than 25%.



In a study conducted by Tai-Yuan Chuang et al, 13 out of 25 patients underwent an open Latarjet procedure and 12 patients underwent an arthroscopic Bankart repair. Based on the procedural diagnostic benchmark of 0.75 for the glenoid index, 12 (92%) of the 13 patients who underwent an open Latarjet procedure and all 12 of the patients who underwent an arthroscopic Bankart repair were correctly classified, so that a total of 24 (96%) of 25 procedures were accurately predicted (Fisher exact test;  $P < .001$ )

In our study 19 out of 30 patients were calculated to have Glenoid index of more than 0.75( 63.3%) and 11 patients of Genoid index of less than or equal to

0.75(36.7%).

15 patients out of 30 (50.0%) underwent an Open Laterjet procedure and 15 patients (50.0%) underwent Arthroscopic Bankarts repair based on the imaging findings and results and pre-surgical evaluation.

11 patients out of 30 had a glenoid index of less than or equal to 0.75. The surgery performed for all these 11 patients was an Open Laterjet (100%)

19 patients out of 30 had a glenoid index of more than 0.75. It was observed that among them 15 patients underwent an Arthroscopic Bankarts repair (78.9%) and the remaining 4 patients underwent an Open Laterjet procedure (21.1%).

Hence, It was observed that there was VERY HIGH STATISTICAL SIGNIFICANCE with  $p < 0.001$

## SUMMARY AND CONCLUSION

This prospective study was done to quantify bone loss with surgical and CT correlation in unilateral shoulder dislocation.

This study was carried out at the Department of Radiodiagnosis and Imaging ,MVJ MC & RH.

All the 30 patients with more than 3 episodes of unilateral shoulder dislocation were subjected to CT of bilateral shoulder joint and later surgery, including both genders and all ages. Most of the patients belonged to the age group of 20-29yrs of age with the mean age of 27.3.

Out of 30, 28 patients were males ,and 2 patients were females.

Detailed clinical history of the patients was obtained.

Right shoulder was found to be more commonly involved.

Majority of the patients had a bone loss of less than 25% (63.3%) and hence Glenoid indices of less than or equal to 0.75(63.3%).

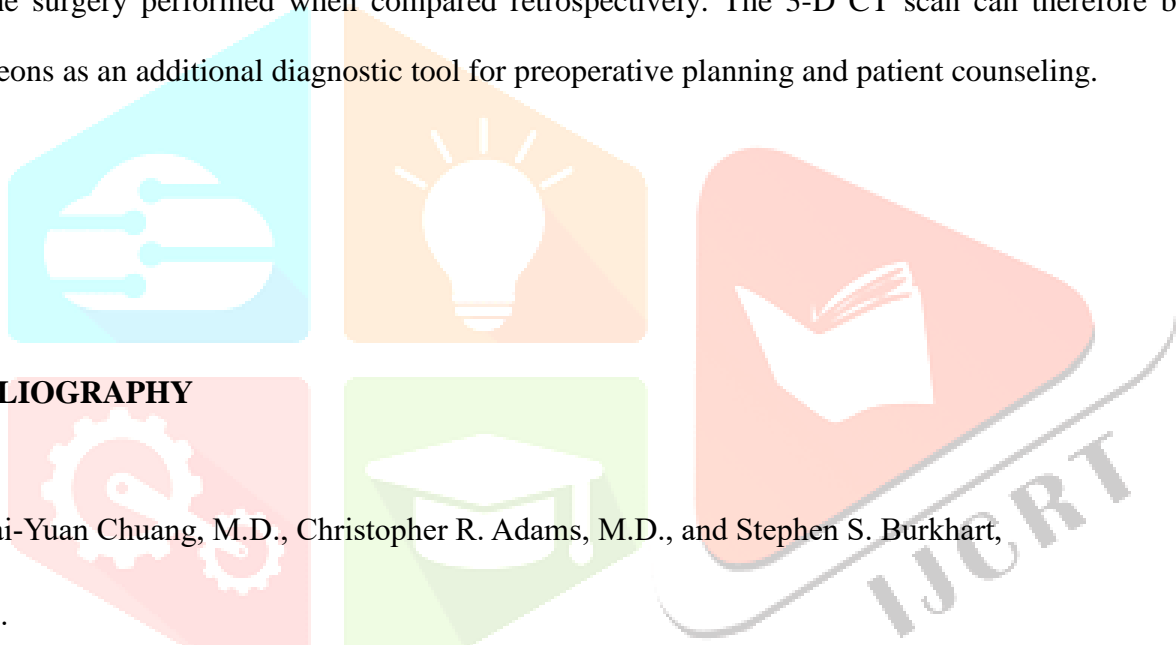
Of the 30 patients included in this study, 15 patients (50.0%) underwent an Open Laterjet procedure and 15 patients (50.0%) underwent an Arthroscopic Bankart repair.

Based of the benchmark of 0.75 for the glenoid index, 11 of the 30 patients (73.3%) underwent an Open surgery had glenoid index of more than 0.75(63.3%) and going retrospectively were predicted to do well with an Open Laterjet procedure for that value.

**73.3 % of the open laterjet surgery performed was predicted for open laterjet.  $P < 0.001$ , hence very high significance difference was found between the surgery performed and surgery predicted**

19 of 30 patients that were predicted to have done well with an Arthroscopic Bankart repair, only 15 patients (78.9%) underwent the Arthroscopic procedure and the remaining 4 patients (21.1%) underwent an Open surgery. The glenoid indices in these four patients were more than 0.75 however, we believe that in these patients, the CT scan did not accurately show the glenoid bone loss because of a technical or artifactual problem with the scan.

To conclude, Glenoid index as calculated from the 3-D CT scan accurately predicted the surgery required to the surgery performed when compared retrospectively. The 3-D CT scan can therefore be used by surgeons as an additional diagnostic tool for preoperative planning and patient counseling.



## **BIBLIOGRAPHY**

1. Tai-Yuan Chuang, M.D., Christopher R. Adams, M.D., and Stephen S. Burkhart, M.D.
2. Lee SB, Kim KJ, O'Driscoll SW, Morrey BF, An KN. Dynamic glenohumeral stability provided by the rotator cuff muscles in the mid-range and end-range of motion. A study in cadavera. *J Bone Joint Surg Am* 2000;82:849-857.
3. Burkhart SS, Lo IK. Arthroscopic rotator cuff repair. *J Am AcadOrthopSurg*2006;14:333-346.
4. Sugaya H, Moriishi J, Dohi M, Kon Y, Tsuchiya A. Glenoid rim morphology in recurrent anterior glenohumeral instability. *J Bone Joint Surg Am* 2003;85:878-884.
5. Saito H, Itoi E, Sugaya H, Minagawa H, Yamamoto N, Tuoheti Y. Location of the glenoid defect in shoulders with recurrent anterior dislocation. *Am J Sports Med* 2005;33:889-893.
6. Griffith JF, Antonio GE, Tong CWC, Ming CK. Anterior shoulder dislocation: Quantification of glenoid bone loss with CT. *AJR Am J Roentgenol*2003;180:1423-1430.

7. Kwon YW, Powell KA, Yum JK, Brems JJ, Iannotti JP. Use of three-dimensional computed tomography for the analysis of the glenoid anatomy. *J Shoulder Elbow Surg* 2005;14:85-90
8. Latarjet M. Techniques in the treatment of recurrent dislocation of the shoulder. *Lyon Chir* 1965;61:313-318.
9. Bigliani LU, Newton PM, Steinmann SP, Connor PM, McIlveen SJ. Glenoid rim lesions associated with recurrent anterior dislocation of the shoulder. *Am J Sports Med* 1998; 26:41-45.
10. Burkhart SS, De Beer JF. Traumatic glenohumeral bone defects and their relationship to failure of arthroscopic Bankart repairs: Significance of the inverted-pear glenoid and the humeral engaging Hill-Sachs lesion. *Arthroscopy* 2000;16:677-694.
11. Burkhart SS, Debeer JF, Tehrany AM, Parten PM. Quantifying glenoid bone loss arthroscopically in shoulder instability. *Arthroscopy* 2002;18:488-491.
12. Lo IK, Parten PM, Burkhart SS. The inverted pear glenoid: An indicator of significant glenoid bone loss. *Arthroscopy* 2004; 20:169-174.
13. Griffith JF, Antonio GE, Yung PSH, et al. Prevalence, pattern, and spectrum of glenoid bone loss in anterior shoulder dislocation: CT analysis of 218 patients. *AJR Am J Roentgenol.* 2008;190(5):1247-1254
14. Griffith JF, Antonio GE, Tong CWC, Ming CK. Anterior shoulder dislocation: quantification of glenoid bone loss with CT. *AJR Am J Roentgenol.* 2003;180(5):1423-1430.
15. Burkhart SS, DeBeer JF, Tehrany AM, Parten PM. Quantifying glenoid bone loss arthroscopically in shoulder instability. *Arthroscopy* 2002; 18: 488–491
16. Ian Beggs. *Ultrasound of the Shoulder and Elbow.* Orthop Clinics of North America. 2006: 277-285
17. C. Whitley Vick et al, *Rotator Cuff Tears : Diagnosis With Sonography*, *American Journal Of Radiology*
18. Pekka Paavolainen M.D, et al, *Ultrasonography And Arthrography in the Diagnosis Of Tears of the Rotator Cuff.* *The Journal of Bone and Joint Surgery (Br)*. March 1994 ; Vol 76-A. No.3 : 335-339
19. Lenchik L, Rogers LF. The shoulder and humeral shaft. In: Rogers LF, ed. *Radiology of skeletal trauma*, 3rd ed. New York, NY: Churchill Livingstone, 2002:593–683. *Journal of Bone and Joint Surgery* Jan 1990 ; 154 :121-123
20. Resnick D. Physical injury: extraskeletal sites. In: Resnick D, ed. *Diagnosis of bone and joint disorders*, 4th ed. Philadelphia, PA: Saunders, 2002: 2377–2480
21. Sugaya H, Moriishi J, Dohi M, Kon Y, Tsuchiya A. Glenoid rim morphology in recurrent anterior glenohumeral instability. *J Bone Joint Surg Am* 2003; 85:878–884

22. Saito H, Itoi E, Sugaya H, Minagawa H, Yamamoto N, Tuoheti Y. Location of the glenoid defect in shoulders with recurrent anterior dislocation. *Am J Sports Med* 2005; 33:889–893
23. Griffith JF, Antonio GE, Tong CWC, Chan KM. Anterior shoulder dislocation: quantification of glenoid bone loss with CT. *AJR* 2003; 180:1423– 1430
24. Edwards TB, Boulahia A, Walch G. Radiographic analysis of bone defects in chronic anterior shoulder instability. *Arthroscopy* 2003; 19:732–739
25. Burkhart SS, De Beer JF. Traumatic glenohumeralbone defects and their relationship to failure of arthroscopic Bankart repairs: significance of theinverted-pear glenoid and the humeral engagingHill-Sachs lesion. *Arthroscopy* 2000; 16:677–694
26. Millett PJ, Clavert P, Warner JJ. Open operative treatment for anterior shoulder instability: when and why? *J Bone Joint Surg Am* 2005; 87:419– 432
27. Boileau P, Villalba M, Hery JY, Balg H, Ahrens P, Neyton L. Risk factors for recurrence of shoulder instability after arthroscopic Bankart repair. *J Bone Joint Surg Am* 2006; 88:1755–1763
28. Burkart SS, DeBeer JF, Tehrany AM, Parten PM. Quantifying glenoid bone loss arthroscopicallyin shoulder instability. *Arthroscopy* 2002; 18: 488–491
29. Griffith JF, Yung PSH, Antonio GE, Tsang PH, Ahuja AT, Chan KM. CT compared with arthroscopy in quantifying glenoid bone loss. *AJR* 2007; 189:1490–1493
30. Rowe CR, Patel D, Southmayd WW. The Bankart procedure: a long-term end-result study. *J Bone Joint Surg Am* 1978; 60:1–16
31. Latarjet M. A propos du traitement des luxationsre´cidivante de l'e´paule. *Lyon Chir* 1954;49:994-1003.
32. Patte D, Debeyre J. Luxationsre´cidivantes de l'e´paule. *Encycl Med Chir Paris. Tech ChirOrthop* 1980;44265. 4.4-02
33. J. S. Torg, F. C. Balduini, C. Bonci et al., "A modified Bristow-Helfet-May procedure for recurrent dislocation and subluxation of the shoulder. Report of two hundred and twelve cases," *Journal of Bone and Joint Surgery A*, vol. 69, no. 6, pp. 904–913,1987.
34. Lunn JV, Castellano-Rosa J, Walch G. Recurrent anterior dislocation after the Latarjet procedure: outcome after revision using a modified Eden-Hybinette operation. *J Shoulder Elbow Surg* 2008;17:744-50.doi:10.1016/j.jse.2008.03.002
35. Gagey OJ, Gagey N. The hyperabduction test. *J Bone Joint Surg Br* 2001;831:69-74. doi:10.1302/0301-620X.83B1.10628
36. Bernageau J, Patte D, Bebeyre J. Interet du profile glenoidiendans le luxationsrecidivantes de l'e´paule. *Rev ChirOrthop* 1976;62:142-7.

37. Edwards TB, Boulahia A, Walch G. Radiographic analysis of bone defects in chronic anterior shoulder instability. *Arthroscopy* 2003;19: 732-9. doi:10.1016/S0749-8063(03)00684-4
38. Edwards TB, Walch G. The Latarjet procedure for recurrent anterior shoulder instability: rationale and technique. *Oper Tech Sports Med* 2002;10:25-32. doi:10.1053/otsm.2002.28776
39. Warner JJ, Gill TJ, O'Hollerhan JD, Pathare N, Millett PJ. Anatomical glenoid reconstruction for recurrent anterior glenohumeral instability with glenoid deficiency using an autogenous iliac crest bone graft. *Am J Sports Med* 2006;34:205-12. doi:10.1177/0363546505281798
40. Gerber C, Nyffeler RW. Classification of glenohumeral joint instability. *ClinOrthopRelat Res* 2002;65-76. doi:10.1097/00003086-200207000-00009
41. Huijsmans PE, Haen PS, Kidd M, Dhert WJ, van der Hulst VP, Willems WJ. Quantification of a glenoid defect with three-dimensional
42. Yamamoto N, Itoi E, Abe H, Kikuchi K, Seki N, Minagawa H, et al. Effect of an anterior glenoid defect on anterior shoulder stability: a cadaveric study. *Am J Sports Med* 2009;37:949-54. doi:10.1177/0363546508330139
43. M. Latarjet, "Traitement de la luxation récidivante de l'épaule. Treatment of recurrent dislocation of the shoulder," *Lyon Chirurgical*, vol. 49, pp. 994-997, 1954
44. Jouve F, Graveleau N, Nove-Josserand L, Walch G. [Recurrent anterior instability of the shoulder associated with full thickness rotator cuff tear: results of surgical treatment]. *Rev ChirOrthopReparatriceAppar Mot* 2008;94:659-69. doi:10.1016/j.rco.2008.03.032
45. Slabaugh MA, Friel NA, Wang VM, et al. Restoring the labral height for treatment of Bankart lesions: a comparison of suture anchor constructs. *Arthroscopy*. 2010;26(5):587e591.
46. Lazarus MD, Sidles JA, Harryman II DT, et al. Effect of a chondral-labral defect on glenoid concavity and glenohumeral stability. A cadaveric model. *J Bone Jt Surg Am*. 1996;78:94e102. [PubMed Abstract].
47. Baumgarten KM, Wright RW. Ease of tying arthroscopic knots. *J Shoulder Elbow Surg*. 2007;14:438e442.
48. McFarland EG, Neira CA, Gutierrez MI, et al. Clinical significance of the arthroscopic driven through sign in shoulder surgery. *Arthroscopy*. 2001;17(1):38e43. [PubMed Abstract].
49. Lippitt S, Matsen F. Mechanism of glenohumeral joint stability. *ClinOrthopRelat Res* 1993; (291):20-28
50. Abboud JA, Soslowky LJ. Interplay of the static and dynamic restraints in glenohumeral instability. *ClinOrthopRelat Res* 2002; (400):48-57

51. Hill HA, Sachs MD. The grooved defect of the humeral head. *Radiology* 1940; 35:690–700
52. Rowe CR, Zarins B, Ciullo JV. Recurrent anterior dislocation of the shoulder after surgical repair: apparent causes of failure and treatment. *J Bone Joint Surg Am* 1984; 66:159–168
53. Bühler M, Gerber C. Shoulder instability related to epileptic seizures. *J Shoulder Elbow Surg* 2002; 11:339–344
54. Miniaci A, Berlet G, Hand C, Lin A. Segmental humeral head allografts for recurrent anterior instability of the shoulder with large Hill-Sachs defects: a two to eight year follow-up. *J Bone Joint Surg Br* 2008; 90(suppl 1):86
55. Bock P, Kluger R, Hintermann B. Anatomical reconstruction for reverse Hill-Sachs lesions after posterior locked shoulder dislocation fracture: a case series of six patients. *Arch Orthop Trauma Surg* 2007; 127:543–548
56. Chen AL, Hunt SA, Hawkins RJ, Zuckerman JD. Management of bone loss associated with recurrent anterior glenohumeral instability. *Am J Sports Med* 2005; 33:912–925
57. Gerber C, Lambert SM. Allograft reconstruction of segmental defects of the humeral head for the treatment of chronic locked posterior dislocation of the shoulder. *J Bone Joint Surg Am* 1996; 78:376–382
58. Miniaci A, Gish MW. Management of anterior glenohumeral instability associated with large Hill-Sachs defects. *Tech Shoulder Elbow Surg* 2004; 5:170–175
59. Sekiya JK, Wickwire AC, Stehle JH, Debski RE. Hill-Sachs defects and repair using osteoarticular allograft transplantation biomechanical analysis using a joint compression model. *Am J Sports Med* 2009; 37:2459–2466
60. Cho SH, Cho NS, Rhee YG. Preoperative analysis of the Hill-Sachs lesion in anterior shoulder instability: how to predict engagement of the lesion. *Am J Sports Med* 2011; 39:2389–2395
61. Yamamoto N, Ito E, Abe H, et al. Contact between the glenoid and the humeral head in abduction, external rotation, and horizontal extension: a new concept of glenoid track. *J Shoulder Elbow Surg* 2007; 16:649–656