



A CASE STUDY IN ABNORMAL VAGINAL DISCHARGE WITH ARAGWADHADI YONIVARTI

Dr. Ankita Meena¹, Dr. A. Neelima²

Department of Prasutitantra and Striroga, Post-Graduate Institute of Ayurveda, Dr Sarvepalli Radhakrishnan Rajasthan Ayurved University, Jodhpur, Rajasthan, India, 342037

ABSTRACT-

Abnormal Vaginal Discharge is one of the most common presenting symptoms at gynecological clinics. Majority of women bear the problems silently without seeking advice and treatment. Vaginal Discharge has substantial impact on female reproductive ability, mental health, and ability to work and to perform routine physical activities. Improper or delayed management results in greater morbidity and mortality. Early recognition, initiating appropriate treatment of vaginal infections is necessary because many women who experience vaginal discharge mistreat their condition by taking over-the-counter medication. Taking necessary precautions are essential in protecting and improving women's health. In comparison to the therapeutic procedure of different systems of medicine, Ayurveda has a potent approach towards the treatment by both internal and external medication. With this background, an effort is made to evaluate the effect of Aragwadhadi Yonivarti in Abnormal Vaginal Discharge. Ayurvedic varti preparations can be considered as a modified vaginal suppository.

A 27-years old married woman visited the OPD of Department of Prasuti Tantra and Stri Roga at Dr. Sarvapalli Radhakrishnan Rajasthan Ayurved University, Jodhpur. She had complaints of whitish discharge per vagina associated with vulval itching, burning micturation & generalized weakness. To address the goal of Successful control, cure & prevents recurrence of Abnormal Vaginal Discharge & associated complaint vulval itching, burning micturation & mid relief in generalized weakness .

Conclusion: -

Abnormal vaginal discharge kapha - vata predominant tridoshaja vyadhai so Aragwadhadi yonivarti was selected because it has Tridoshashamaka especially Kaphavata Shamaka, Krimighna, Vranashodhana, Ropana, Putihara, Kandughna properties as well as antimicrobial, antifungal effect which leads to Samprapti Vighatana of Disease and Successful control, cure & prevents recurrence of Abnormal Vaginal Discharge.

Keyword – Abnormal Vaginal Discharge, Yonivarti, Vaginal suppositorie.

INTRODUCTION:

Abnormal Vaginal Discharge is one of the most common presenting symptoms at gynecologic clinics.¹ The World Health Organization (WHO) defined vaginal discharge syndrome as Abnormal Vaginal Discharge in amount, color, and odor with or without lower abdominal pain or specific symptoms or specific risk factors (WHO, 2003).² Different levels of society reported the incidence of abnormal vaginal discharge of 12.1 to 30 %.³ In the healthcare setting, approximately 11% to 38.4% of Indian women suffer from vaginal discharge.⁴ Each year, an estimated 10 million women visit primary care centers with complaints of excess or abnormal vaginal discharge.⁵ It is not a disease, it is a symptom of further ailments as reproductive tract infections (RTIs) and sexual transferred diseases.⁶ Majority of women bear the problems silently without seeking advice and treatment.

CASE REPORT: -

Presenting concerns

A 27-years old married woman visited the OPD of Department of Prasuti Tantra and Stri Roga at Dr. Sarvapalli Radhakrishnan Rajasthan Ayurved University, Jodhpur. She had complaints of whitish discharge per vagina associated with vulval itching, burning micturation & generalized weakness.

Clinical finding

The patient have complaint of white discharge per vagina 7 months ago, she took some allopathic medicines and got relief. But the symptoms recurred after stopping medication. Her complaints aggravated since 2 month and the discharge was curdy white in colour with vulval itching & generalized weakness. No history of similar problem in any of the family members. Personal history of the patient revealed that her appetite, sleep, burning micturition on & off and bowe habit normal. There was no relevant history of hypertension, thyroid disorder, diabetes mellitus and no history of surgical intervention for the patient.

Menstrual history

Age of Menarche – 13 years

LMP: 09/02/2023

Interval: 28-32 days

Duration: 4- 5 days

Character: regular with mild pain.

Obstetric history: G₃P₂L₂A₁D₀

Contraception history: nil

Per speculum: On per speculum examination, moderate curdy white discharge present.

Per vaginal : Cervix was healthy and no other abnormalities were noted.

Diagnostic Assessments:

- **Complete Blood Count:** WNL
- **Urine Routine and microscopic:** Pus cell – 4 to 5 / hpf, Epithelial cell- 3-4 cells/ hpf
- **ESR:** 46 mm 1st hr.
- **High Vaginal Swab Culture:** Few pus cell, moderate epithelial call seen, Candida Albicans .
- **Vaginal pH:** 4
- **Pap smear (18/02/23):** Negative for intraepithelial lesion or malignancy.
- **USG before treatment (18/02/23):** Normal USG finding no free fluid seen in POD

Therapeutic intervention:

| | |
|--------------------------------|-----------------------------------|
| Name of Drug | Aragwadhadi Yonivarti |
| Dose | 5gm OD |
| Route of administration | Vaginally |
| Duration of drug trial | 7 Days for two consecutive cycles |

Drug Administration –

Varti will be given after cessation of menses one time daily for 7days. During administration of *Yoni Prakshalan* with *Sukhoshshna jala* and Varti should be inserted deep into the vagina. After the retention period of one *Muhurta* Varti should be taken out and *Yoni Prakshalan* should be carried out with *Sukhoshshna Jala*.

Follow-up & Outcomes

The patient's treatment was started on 22 February 2023. Her treatment was continued with yonivarti for two months. After 2 months patient symptoms no vaginal discharge, no vulval itching, no burning micturition, mid relief in generalized weakness.

After 2 months of treatment laboratory investigation evaluated which shows following results-

- **Complete Blood Count:** WNL
- **Urine Routine and microscopic-** Pus cell – 0 to 1 / hpf, Epithelial cell- 1-2 cells/ hpf
- **High Vaginal Swab Culture:** Few Pus cells, few epithelial cell present
- **Vaginal pH:** 4.5
- **ESR-** 22mm at 1 hr.

Discussion –

Abnormal Vaginal Discharge is predominantly caused by replacement of normal vaginal flora by pathogenic bacteria. Concerning pathogenesis of disease, it can be concluded that due to faulty diet & life style there is imbalance of doshas in the body, & when aggravated Kapha dosha consequently reaches yoni (vagina) through vitiated Vayu and combine with Pitta then white coloured, thin or thick, foul smelling fluid discharge from the vagina called as Abnormal vaginal discharge. Abnormal vaginal discharge kapha - vata

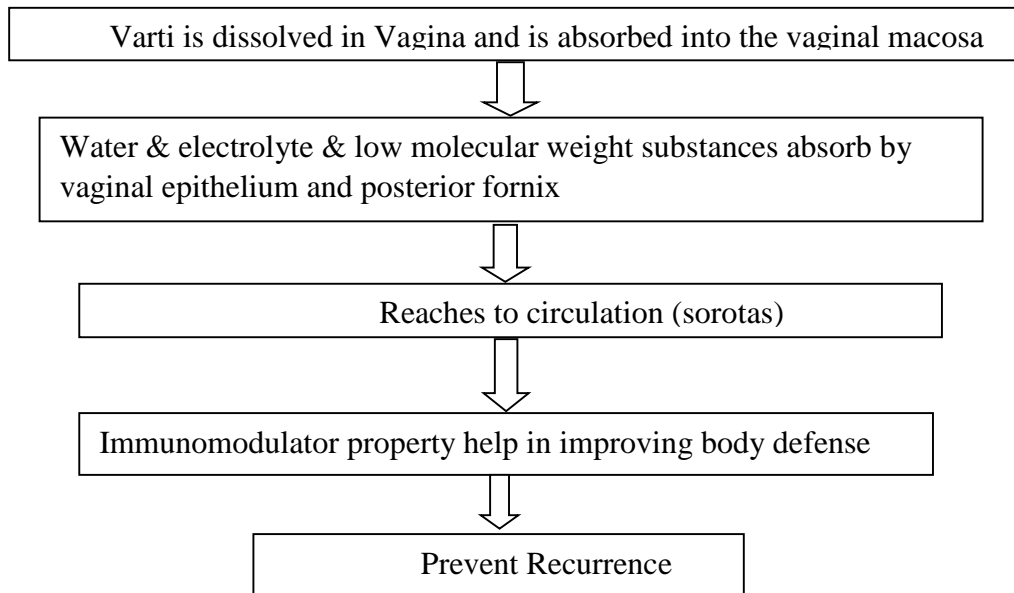
predominant tridoshaja vyadhai so Aragwadhadi yonivarti was selected because it has Tridoshashamaka especially Kaphavata Shamaka, Krimighna, Kandughna, Stambhana, Shoshana, Samgrahi, Kledaghna, Kaphaghna, Putihara, Vranasodhana, Vranaropana, as well as antimicrobial, antifungal, antibacterial properties which lead to Samprapti Vighatana and successfully control and cure vaginal discharge, Vulval itching, and burning micturition.

Aragwadhadi varti possesses mainly Kashaya Rasa. Kashaya Rasa is mainly formed by conjugation of Vayu and Prithvi Mahabhuta. Vayu is Ruksha in quality and dries up the excessive fluids present in the tissues while Prithvi by virtue of Kathinya and Sthira Guna which are opposite to Drava and Sara Guna reduces the Srava. So, Kashaya Rasa by virtue of its Guna restrains Srava. The second dominant Rasa in Aragwadhadi varti is Tikta & Madhura Rasa. Tikta rasa is a combination of Vayu and Akasha Mahabhuta. These two Mahabhutas are having qualities opposite to Kapha. Tikta Rasa is having Kandughna, Kleda, Puya and Kapha shoshna pharmacological properties which alleviate the symptoms of Kadu (vulval itching). Some of the ingredients of Aragwadhadi varti possess Madhura Rasa which is Vata and Pitta Shamaka and also has Prinana, Jeevana property it will help in reducing symptoms of burning micturition. Balya, Poshana Karma of Madhura Rasa helped in promotion of healing by Dhaturvardhana (re-growth of the tissue) leading to minimal inflammation. Katu Rasa also has Shothaghna, Kandughna and Abhishyanda-Kleda-Sneha Upahanti properties. By these properties it eases Srava as well as reduces Shotha.

Most of the ingredients of Aragwadhadi varti possess Laghu Guna. By the virtue of this property this may pacify vitiated Kapha and Kleda and supports the function of the other Rasas. Snigdha and Guru Guna are predominant in some ingredients. So, these ingredients alleviate vitiated Vayu. Thus, ultimately help to stop secretion. The equal ingredients of Aragwadhadi varti are having Sheeta & Ushna Virya. Sheeta Virya drugs normalize the condition of vitiated Pitta & UshnaVirya drugs pacify vitiated Vata and Kapha. Thus, Aragwadhadi varti may alleviate the vitiated Vata, Pitta and Kapha which eradicates vaginal discharge by Stambhana action .

So, Probable mode of action of Aragwadhadi varti can be understood as:-

- Yoni Shodhana- Clean the vagina- by Vrana Shodhana Property.
- Restrain Srava - Kashaya, Tikta and Katu Rasa property & Laghu Guna.
- Kill causative microorganism - Krimighna, antimicrobial, antibacterial, anti fungal, antiviral properties.
- Rejuvenate the epithelium – Antioxidant and Madhura Rasa property like Prinana, Jivana etc.

Mode of action yonivarti: ⁷**Conclusion –**

Abnormal vaginal discharge kapha - vata predominant tridoshaja vyadhai so Aragwadhadi yonivarti was selected because it has Tridoshashamaka especially Kaphavata Shamaka, Krimighna, Vranashodhana, Ropana, Putihara, Kandughna properties as well as antimicrobial, antifungal effect which leads to Samprapti Vighatana of Disease .

Aragwadhadi varti Kashaya, Tikta and Katu Rasa have Krimighna property which directly inhibits the growth of Krimi and finally diminishes Srava. This drug show better effect in alleviating candida infection, relieving fungal hyphae and pus cell in vaginal swab culture. Drug administered in varti form because Yoinvarti has been indicated as the first line of treatment in the context of Sleshmala Yonivyapat. It has immune modulator property help in improving body defense system and Successful control, cure & prevents recurrence of Abnormal Vaginal Discharge.

REFERENCES: -

- ¹Chenchit Chayachinda, M.D.*, Kittipoom Chinhiran, M.D.***, Rossaphorn Kittiyaowamarn, M.D.***, Surasith Chaithongwongwatthana, M.D.***, Nipat Teeratakulpisarn, M.D.**** The Thai 2022 Sexually Transmitted Infections Treatment Guideline: Abnormal Vaginal Discharge ,Thai Journal of Obstetrics and Gynaecology July 2022, Vol. 30, No. 4, Pp. 222-233
- ²Aqila Homood S Al Shammari¹, Reem Hamoud S Alshammari², Dnya Saleh A Alanazy², Atheer Bader F Alanzi², Abnormal Vaginal Discharge (Avd) Among Women of Saudi Arabia: Community Based Cross Sectional Study, 2021 Discovery Scientific Society, Issn 2321–7359 Eissn 2321–7367
- ³Anandan V, Kayalvizhi Va, Vijayabhaskar C, Sobimeena Rm. A Study on Vaginal Discharge In Females Attending Sexually Transmitted Diseases Outpatient Department. Int J Res Dermatol 2022;8:314-9.
- ⁴C. Zemouri, T. E. Wi, J. Kiarie Et Al., “The Performance of The Vaginal Discharge Syndromic Management In Treating Vaginal And Cervical Infection: A Systematic Review and Meta-Analysis,” Plos one, Vol. 11, No. 10, Article Id E0163365, 21 Pages, 2016. View At: Publisher Site | Google Scholar
- ⁵Angotti Lb, Lambert Lc, Soper De: Vaginitis: Making Sense of Over-The-Counter Treatment Options. Infect Dis Obstet Gynecol. 2007, 2007:97424. 10.1155/2007/97424
- ⁶ Aqila Homood S Al Shammari¹, Reem Hamoud S Alshammari², Dnya Saleh A Alanazy², Atheer Bader F Alanzi², Abnormal Vaginal Discharge (Avd) Among Women of Saudi Arabia: Community Based Cross Sectional Study , 2021 Discovery Scientific Society, Issn 2321–7359 Eissn 2321–7367
- ⁷ Poonam Choudhary¹ Laxmipriya Dei² Sushila Sharma³, 2014; A Rct On The Efficacy Of Nimbadi Yoni Varti On Abnormal Vaginal Discharge In Reproductive Aged Women, Journal Of Ayurveda And Holistic Medicine (Jahm), Www.Jahm.In (Essn: 2321-1563), 2(6):1-12.