



# INTERNATIONAL JOURNAL OF CREATIVE RESEARCH THOUGHTS (IJCRT)

An International Open Access, Peer-reviewed, Refereed Journal

## A REVIEW LITERATURE ON MOUTH ULCER

Miss. Priyanka C.Sirsat<sup>1</sup>, Miss .Pratiksha D. Sonavane<sup>2</sup>

Mr. Sattyajit N. Takale<sup>3</sup>, Miss. Yojana A. Kunjir<sup>4</sup>

<sup>1-3</sup> Students, <sup>4</sup> Assistant Professor

**Mahadev Kanchan College of Pharmaceutical Education and Research Uruli Kanchan, Tal-Haveli Dist-Pune, 412202. Maharashtra India.**

### Abstract

An oral ulcer is a sore that forms on the lining of the mouth cavity. The definition states that there is "a breach within the mucosal surface of the buccal cavity." A mucous membrane or skin surface ulcer is an open sore where inflammatory dead tissue has been removed. Many diseases' etiopathogenesis is unknown, despite their high incidence. Redness, swelling, and bleeding are frequently present in addition to the regular pain. The mouth ulcer frequently hurts and is uncomfortable, and as it heals, it could change how someone likes to eat. They may be classified as acute or chronic depending on how they manifest and develop. Acute aphthous stomatitis is associated with trauma, recurrent aphthous stomatitis, Behcet's disease, bacterial and viral infections, allergic reactions, and negative medication reactions.

**Keywords :** oral ulcer, viral infection ,bacterial infection fungal infection , gene factor , tretement,classification

### Introduction

Aphthous stomatitis Or mouth ulcer is an ulcerative condition that is released to yellowish Or white depression with red lining of mouth cavity. which is break in continuityof the epithelium by molecular necrosis. mouth ulcer is a canker sore which lies on toungue, cheek, Or lips which interact with food and make it painful. it is generally generated by many of causes, such as some food allergies, insufficient sleep, biting of inner cheek, improper brushing of teeth and most important due to vitamin deficiency. The size of the mouth ulcer spot can vary from milimeter to less than diameter (1mm to 1cm in diameter

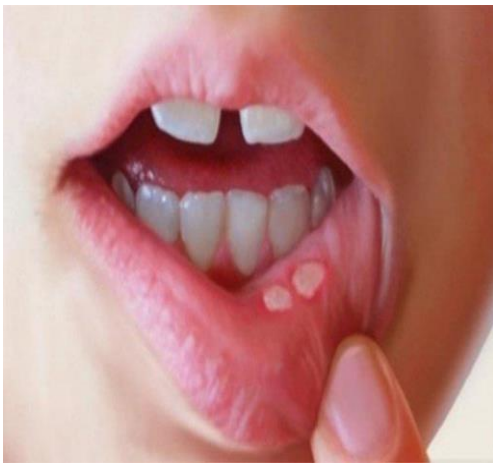

Fig. Aphthous stomatitis.

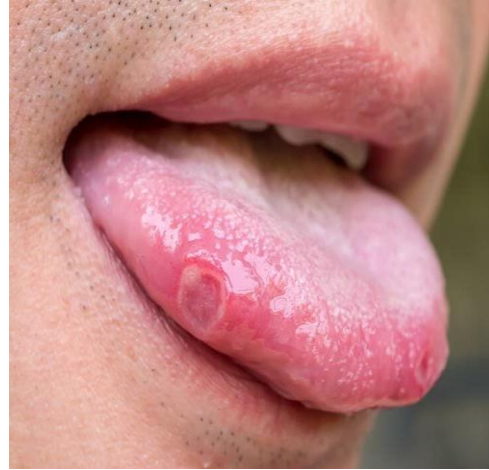

Fig. Aphthous stomatitis.

### Ulcer Infections Caused By Viruses

The clinical characteristics of the herpes virus in the mouth are influenced by whether the herpes virus contamination is primary or secondary [26]. The primary infection is known as primary herpetic gingivostomatitis. It can be asymptomatic or very mild in very young children, but as the kid becomes older, it is associated with more severe overall symptoms. The first sign is gingivitis, which is followed by the development of vesicles that are prone to rupture, leading to painful ulcers covered in a yellowish membrane that usually coalesces after two to three days. Still, the most typical sites are the lips, tongue, oral mucosa, palate, and pharynx [27]

### Herpes simplex viruses 1

Several infections have the potential to lead to oral ulcers. Herpes simplex type 1 (HSV-1) is the primary viral cause of ulcers. Those who are impacted may develop many, small, superficial ulcers on their oral mucosa. Frequent enlargement and ulceration of the gingiva resemble acute necrotizing ulcerative gingivitis. Despite the fact that it was once believed to be a disease of childhood, primary HSV-1 infection typically arises in the second or third decade of life [28]. About 5% of individuals with initial HSV-1 infection (cold sores) experience recurrent episodes of herpes labialis. This involves ulcers, vesiculation, pustulation, paraesthesia, and erythema at the mucocutaneous junctions of the lips and/or the nose. Herpes labialis risk factors include pregnancy, exposure to UV light, and concurrent illness [29,30].

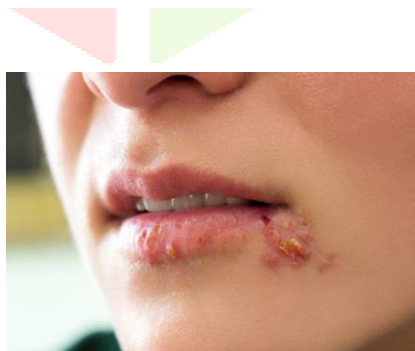

Fig. Herpes simplex viruses 1

### Epstein-Barr Virus (EBV):

Despite being rare, Epstein-Barr virus (EBV) ulcers can be a sign of infectious mononucleosis. The ulcers are a few tiny, superficial oral mucosal ulcers. EBV is more frequently connected to the ulcers that come along with different non-lymphomas. Hodgkin's [31] or tooth decay hairy leukoplakia (OHL), which can appear when the immune system is suppressed. OHL has been observed in inflammatory bowel disease patients on immune-suppressing drugs

**Ulcer caused by fungal infection****Candidiasis :**

The most frequent fungus infection in the oral cavity is called candidiasis, and it can present clinically in a number of ways, including ulceration [32]. About 40% of people without candidiasis symptoms or signs have the typical causative organism, *Candida Albicans*, in their oral flora. However, this fungus can infect people when the oral flora is disturbed. All instances of candidiasis require evaluation of predisposing factors. Dentures that don't fit well and inadequate vertical dimension are two instances. In edentulous patients and persistent situations involving edentulous people, systemic variables must be investigated. Immune deficiency diseases including acquired immune deficiency syndrome and uncommon genetic immune deficiencies are characterised by intractable mucocutaneous candidiasis. Patients using immunosuppressive medications for cancer, autoimmune disorders, or to prevent organ rejection frequently develop candidiasis.

Healthy tongue , Candidiasis infection Healthy tongue , Candidiasis infection Fig

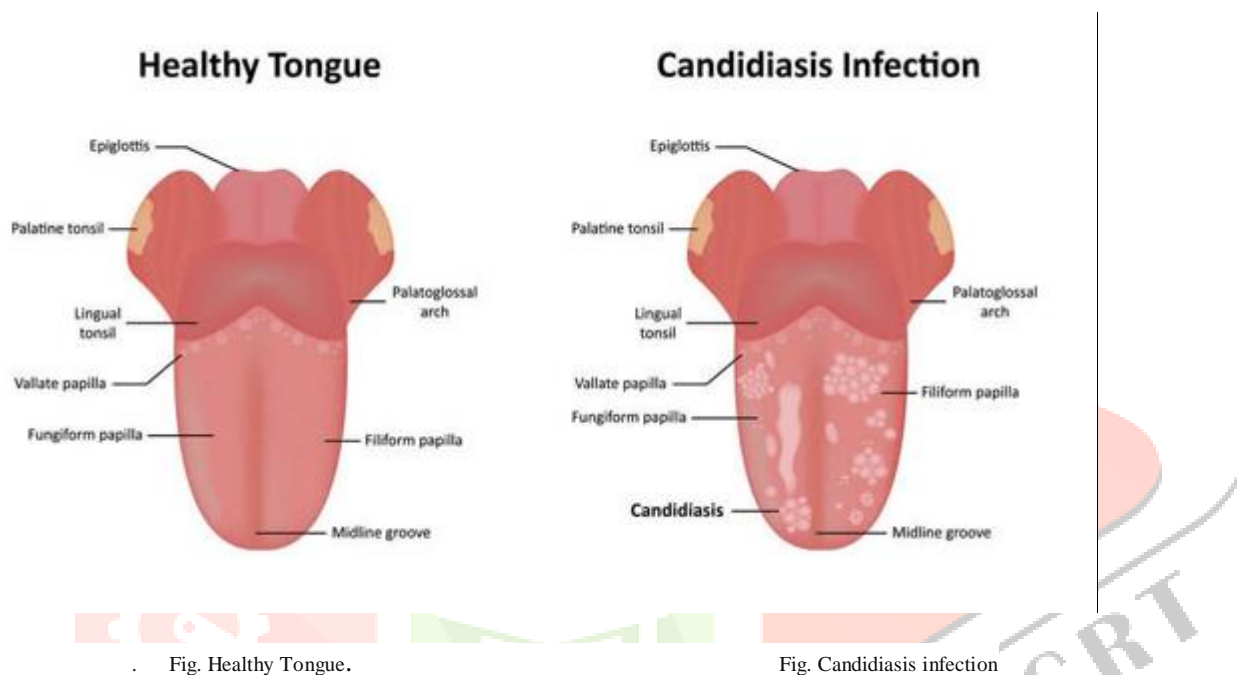


Fig. Healthy Tongue.

Fig. Candidiasis infection

**Acute necrotizing ulcerative gingivitis:**

A non-specific ulceration illness that almost exclusively affects the gingivae is acute destructive ulcerative periodontal. Diabetes with poor management, tobacco use, a weakened immune system, and perhaps psychological stress are all related contributing factors [34]. Cleaning and flossing, as well as minor trauma, typically hurt the patient. The gingiva might get desquamated or develop a bulla with blood if it is rubbed. Postmenopausal women are more likely to suffer from the condition, but they are not the only ones. A few of the conditions that could exhibit clinically with analogous lesions are bullous pemphigoid, allergic stomatitis, and erosive lichen planus [35].

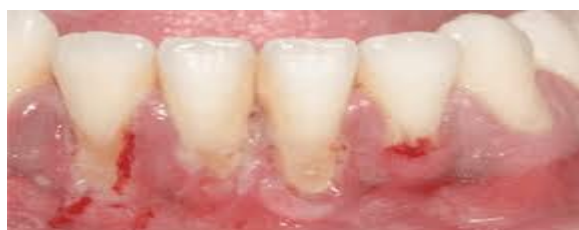

Fig. Acute necrotizing ulcerative gingivitis infection

## Mycobacterial infection

Sputum-borne The oral mucosa can get infected with Mycobacterium tuberculosis, leading to non-healing indurated ulcers. The most common cause of ulcers is chronic ulcers. Caseous necrosis and granulomatous inflammation both happen. Tissue culture is necessary for the diagnosis of these lesions since they are difficult to identify. Oral ulcers are long-lasting, indurated, and feature thick mucous material at the base along with an unevenly undermined edge. Tuberculous ulcers can be ragged and uneven, which can be uncomfortable. They are typically painless and persistent, with overhanging or undermined margins and a pale bottom. Anywhere in the mouth can experience secondary TB oral symptoms, with the tongue being the most frequently affected area. Additional sites affected include the mucous membrane, palate, gingiva, mouth floor, and lips [37,38].

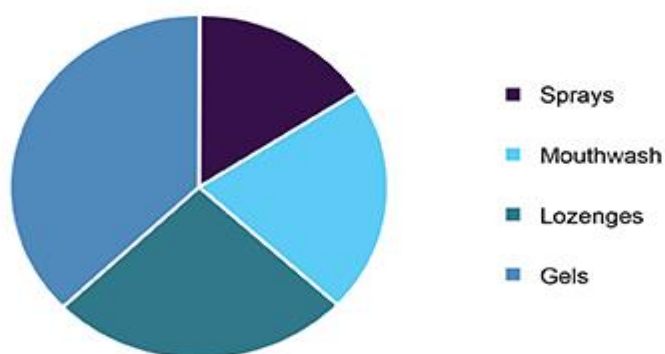
### Genetic factor:

About 30 to 40 percent of patients with aphthous ulcers have a family history, indicating that the condition has a genetic component [40]. Some patients have a history of recurrent aphthous ulcers in their families. The onset of symptoms at a young age and the severity of the symptoms share a similar characteristic. Recurrent aphthous ulcers are strongly related with identical twins [41].

### Tretements:

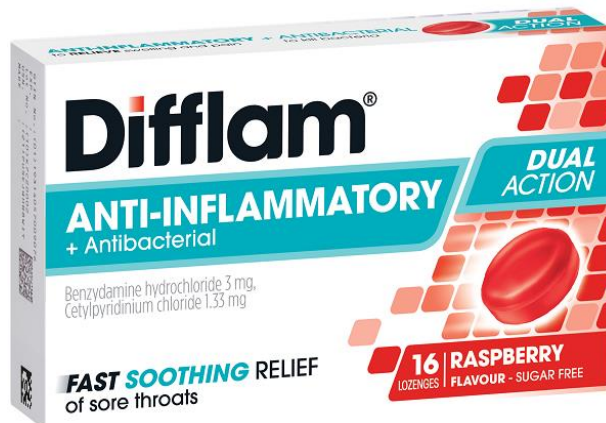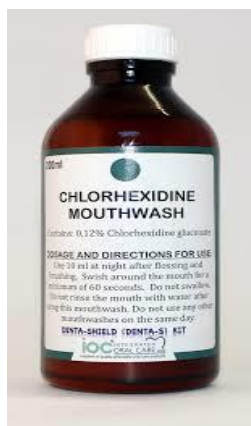A variety of gel lozenges, sprays, and mouthwashes are used to treat ulcers .mouthwashes with ingredients such povidone iodine, chlorhexidine, or chlorohexidine, as well as homemade salt and warm water mouthwashes and Aloclair mouthwash without alcohol.Gel with a liquid phase that generally seems thicker than other compounds is an example of a semisolid material.To relieve discomfort and lower the risk of complications, topically applied therapies are suggested.Usually, paracetamols, steroids, gel, ointment, and antibiotics such (doxycycline) are recommended to treat infections and suppress the immune system. Due to the numerous side effects and negative consequences these synthetic and semi-synthetic pharmaceuticals have nowadays, herbal medications are used .

Global mouth ulcers treatment market share, by formulation, 2017 (%)

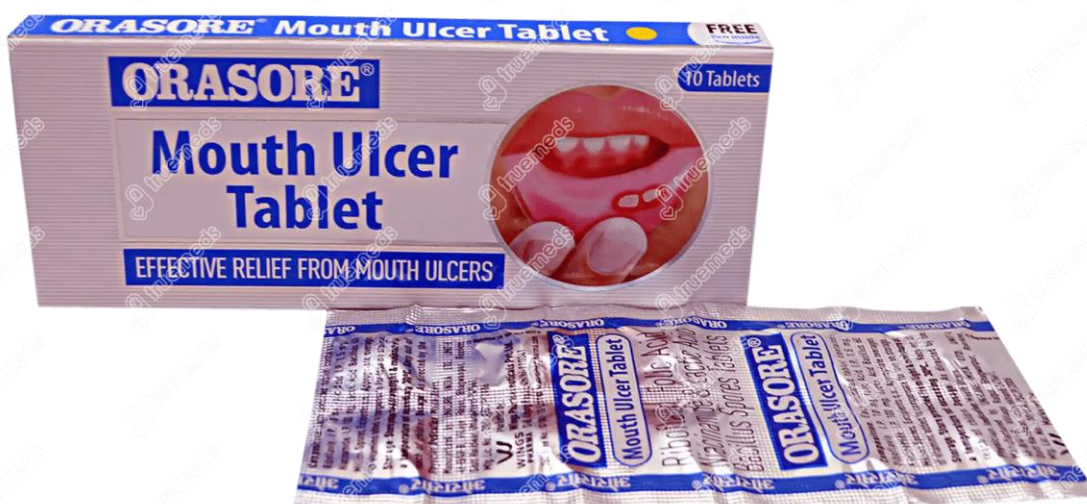

Source: www.grandviewresearch.com





F



Oral lesions			
	Acute ulcers	Chronic ulcers	Recurrent ulcers
Single ulcer	<ul style="list-style-type: none"> <li>Bite injury</li> <li>Thermal damage</li> <li>Chemical/toxic/drugs</li> <li>Mechanical irritation</li> <li>Radiation therapy</li> </ul>	<ul style="list-style-type: none"> <li>Traumatic ulcer</li> <li>CMV-associated ulcer</li> <li>Tuberculous ulcer</li> <li>Syphilitic ulceration</li> <li>Necrotizing sialometaplasia</li> <li>Fungal ulceration (Blastomycosis, Mucormycosis, Histoplasmosis)</li> <li>Sarcoidosis</li> <li>Sweet's syndrome</li> </ul>	<ul style="list-style-type: none"> <li>Behcet's disease</li> <li>Crohn's disease</li> <li>Coeliac disease</li> </ul>
Multiple ulcers	<ul style="list-style-type: none"> <li>Herpetic gingivostomatitis</li> <li>Herpes zoster/varicella</li> <li>Herpangina</li> <li>Hand-foot-and-mouth-disease</li> <li>Infectious mononucleosis</li> <li>Diphtheria</li> <li>Candidosis</li> <li>Erythema multiforme</li> <li>Reiter's syndrome</li> <li>Stevens-Johnson-Syndrome</li> <li>GvHD</li> <li>Chemotherapy induced</li> <li>Plasma cell stomatitis</li> </ul>	<ul style="list-style-type: none"> <li>Necrotizing ulcerative gingivitis</li> <li>Granulomatosis with polyangiitis</li> <li>Bullous pemphigoid</li> <li>Mucous membrane pemphigoid</li> <li>Pemphigus vulgaris</li> <li>Lichen planus</li> <li>Linear IgA disease</li> <li>Melkersson-Rosenthal Syndrome</li> </ul>	<ul style="list-style-type: none"> <li>Recurrent herpetic stomatitis</li> <li>Pyoderma gangrenosum</li> <li>Sjögren's Syndrome</li> <li>Deficiencies (Vitamin B 2, 6 or 12, folic acid, zinc)</li> <li>Systemic Lupus erythematoses</li> <li>PFAPA-Syndrome</li> <li>MAGIC-Syndrome</li> <li>Cyclic neutropenia</li> <li>Familial Mediterranean fever</li> <li>Hyperimmuno globulinemia D</li> <li>Oral hypersensitivity reaction</li> </ul>

## Classification of Oral Ulcerative Lesions:

Based on duration of ulcer spot or canker sore mouth ulcers classified as below

### A) Acute Ulcer : (short term ulcer)

#### 1 . Traumatic ulcers :

Traumatic ulcers are the most prevalent type of ulcer and are acute in character. The usual causes of the ulcers are physical, thermal, or oral mucosal chemical injury. When a patient is under local anaesthesia for a dental procedure, it is possible for physical trauma to occur during routine tasks like brushing or flossing their teeth, as well as from the sharp edges of dentures or teeth. 4 . The most frequent causes of thermal burns include hot foods or drinks like pizza, coffee, or tea, as well as heated dental instruments used during dental procedures. The inadvertent use of medicinal substances during dental operations, such as eugenol , formocresol , sodium hypochlorite, and others, can cause injury to the oral mucosa monomer, too. Patients who use aspirin tablets sublingually to treat pain report experiencing chemical burns as a result of the medication 5. Mouthwashes and other oral care products with a high alcohol concentration can also cause mucosal changes. Electric burns commonly occur on the lips. Food-related burns are minor and limited to the lips and hard palate. Depending on the severity of the trauma, these begin with pain and an area of erythema before developing into ulcers and taking several days to heal. The pseudo membrane around the ulcers is yellowish-white necrotic and has elevated, erythematous borders. Lip ulcers typically have crusts. If the cause is treated, the traumatic ulcers usually disappear within 7 to 10 days. It's critical to differentiate between squamous cell and traumatic ulcers. To rule out a serious fungal infection or cancer, a biopsy is advised if the ulcer does not heal within two weeks.

#### 2. Necrotizing Sialometaplasia:

Both chronic and acute sialometaplasia (NS) exist. It is a benign, non-neoplastic, self-limiting salivary gland inflammation that, both clinically and histopathologically, resembles cancer 7. It is most frequently observed in middle-aged men. The palate, lower lip, retro molar area, sublingual region, tongue, and larynx are the most often affected areas. The lesion first manifests as a painful swelling that is not ulcerated, but over time, the necrotic tissue sloughs off, leaving a crater-like ulcer. The ailment is bordered by well defined induration. Lesion sizes range from 1 cm to 5 cm, and the ulcer goes away on its own in 5 to 7 weeks.

#### 3. Primary Herpetic Gingivostomatitis:

Herpes simplex virus symptoms frequently present in the mouth as primary herpetic gingivostomatitis. infection with (HSV). HSV-1 is the primary cause of instances that arise above the waist in more than 90% of cases. Down below the waist, HSV-2 occurs. The culture of HSV-2 from oral lesions is common due to the shifting sexual practises. 9 . With a peak incidence of occurrence occurring between 2 and 3 years old, the age of occurrence is typically between 6 months and 5 years. Fever, nausea, anorexia, and irritability are some prodromal signs 10. By injecting contaminated fluids into the mucosa, skin, or eyes, the virus is first exposed, leading to primary infection. The the trigeminal ganglion travelling through the sensory nerve axons 4 is one example of how the virus creates a chronic latent infection in the sensory ganglia. Both the hard and soft palates develop clusters of vesicles and/or ulcers. Other sites include the buccal, labial, gingival, and tongue mucosa. The vesicles degrade into 1 to 5 mm-wide ulcers, which then combine to produce larger ulcers. The edges are scalloped and erythematous.

#### 4. Varicella-Zoster Virus Infection:

Early life is when chickenpox or primary VZV infection begins. Low grade fever, malaise, and the appearance of an ulcer were the first symptoms of the illness. A maculopapular rash that is extremely itchy is followed by "dewdrop-like" vesicles. When the maxillary branch of the trigeminal nerve is damaged, some individuals present with painful symptoms. Several patients feeling of tenderness and scorching 1. Clusters of ulcers are visible unilaterally on the gingiva or hard palate after the prodromal symptoms. These ulcerations combine to become larger, scalloped-bordered ulcers. These ulcers heal within 10 to 14 days

## 5. Erythema Multiforme:

Erythema multiforme has significant, minor, and persistent variants that can be distinguished clinically. The condition might exist, having common or uncommon skin lesions. The pathognomic manifestation for this disorder is target lesions on the extensor surfaces of the acral extremities. These lesions have an erythematous halo on the lesion's perimeter, a dusky core blister, and a dark red inflammatory zone encircled by a light ring of edoema. In addition to cutaneous lesions, lesions can also appear in the mucous membranes of the oral, ocular, or vaginal mucosa. 15 .25%–60% of patients with erythema multiforme had oral involvement.

## 6. Acute Necrotizing Ulcerative Gingivitis (Anug) and Acute Necrotizing Ulcerative Periodontitis (Nup):

Acute Necrotizing Ulcerative Gingivitis (Anug) and Acute Necrotizing Ulcerative PerANUG is also known as "Trench Mouth" since it was widespread among soldiers in the trenches during World War I. NUP and NUG both primarily related with immunological suppression, smoking, poor oral hygiene, and debilitation 17 .Pseudomembranous slough-covered crater-like depression and a punched-out ulcer are visible in the gingival at the crest of the interdental papilla 18. Both the connected and marginal gingiva are impacted. Early signs include halitosis, increased salivation, a metallic taste, gingival sensitivity, and bleeding. In individuals with compromised immune systems or malnutrition, NUG and NUP may proceed to Noma (Cancrumoris) 19.

## 7. Recurrent Aphthous Stomatitis:

The term aphthae is derived from the Greek word aphthi, which meaning "to set on fire" or "to inflame," and is used to describe Hippocrates is said to have coined the term to describe the discomfort associated with a prevalent oral illness during his day (possibly, aphthous stomatitis). 20 . Local damage, genetic factors, nutritional inadequacies, viral and bacterial infections, and immunological or endocrine disruptions have all been identified as etiological contributors of frequent mouth ulcers. Recurrent aphthous stomatitis (RAS) occurs in some patients when the aetiology is unknown .There are three forms of RAS: minor (>70% of cases), major (10%), and herpetiform (10%). The morphology, location, severity, and prognosis of these subgroups differ. Table 1. All kinds of RAS have an effect.

## 8. Behçet Disease [Bd] (Behçet Syndrome):

Behcet's disease (BD) is a multisystem inflammatory illness characterised by periodic episodes of oral aphthous ulceration, vaginal ulceration, and other symptoms. Ocular lesions, ulceration, and other skin lesions 23 .The cause of BD is uncertain, but it is thought to be connected to autoimmunity. It can affect people of all ages, however it is uncommon before puberty and after the age of 60. The most prevaare oral ulcerations, which are recurrent and tender in the majority of patients and are clinically and histologically indistinguishable from RAS. Some are small and recurring, while others are deep, big, and scarring.

## B) Chronic Ulcers :(long term ulcer)

## 9. Sustained Trauma:

The tongue, lips, buccal mucosa, and floor of the mouth at the lingual sulcus are the most typically affected areas. Traumatic ulcers heal in 7 to 10 days, however some lesions might last weeks or months due to persistent damage, irritation, or secondary infection. 25

## 10. Traumatic Ulcerative Granuloma (Eosinophilic Ulcer of the Tongue):

TUGSE (Traumatic Ulcerative Granuloma with Stromal Eosinophilia) is a persistent solitary oral mucosal ulcer. individuals over the age of 40 are more likely to be affected, however children and young individuals are also affected. The tongue is the most commonly affected site, followed by the buccal mucosa, retromolar region, mouth floor, and lips. These are traumatic ulcers, but the penetration of inflammation causes myositis. Buccal mucosa, labial mucosa, the floor of the mouth and vestibule, as well as areas with more underlying skeletal muscle, may all be affected. In The lesions can appear as an ulcerated, mushroom-shaped, polypoid mass on the lateral side of the tongue in some cases 27. The appearance of induration raises the possibility of squamous cell carcinoma (particularly if it is on the tongue) or another malignancy of the salivary gland or lymphoid system.

**Pemphigus and Pemphigoid:** These are autoimmune, life-threatening lesions characterised by blisters, eroded skin, and mucous membranes.

### 11. Pemphigus:

Pemphigus vulgaris is the most prevalent kind. The antibodies are directed at DSG3. When a lesion is restricted to the mucosa and DSG1 and DSG3 antibodies are being developed<sup>28</sup>. Oral lesions may begin as a bulla and then rupture to develop superficial ulcers. A thin layer of epithelium tears away, producing a denuded base known as Nikolsky's sign, named after Russian surgeon Pyotr Nikolsky (1858-1940)<sup>29</sup>. The lesions are most typically seen on the buccal mucosa along the occlusal plane. Other areas implicated include the palate and gingiva. The oral lesions last months longer than the skin lesions. However, the duration of the lesion is critical in distinguishing it from viral ulcers. There is a potential for recovery if the lesion is addressed early.

### 12. Pemphigoid:

Pemphigoid is divided into two types: mucous membrane pemphigoid and bullous pemphigoid. The autoantibodies are directed against the basement membrane proteins BP180 and BP230. Bullous oral lesions affect 30 to 50% of individuals. Oral lesions are smaller, grow more slowly, and are less painful than pemphigus. Such pemphigoid is characterised by early remission. The mucosal membrane pemphigoid lesions manifest as desquamative gingivitis, and the gingiva appears bright red, mimicking erosive lichen planus and pemphigus.

### 13. Mucormycosis:

Mucormycosis is an opportunistic infection caused by a saprophytic fungus found in soil or mould-rotting food. Infection develops in people with weakened host resistance, such as those with uncontrolled diabetes, haematological malignancies, chemotherapy, or immunosuppressive medication therapy. The fungus infiltrates arteries, causing thrombosis and ischemic damage. The oral lesions appear as ulcers on the palate as a result of necrosis caused by palatal vascular invasion. The ulcer is broad and deep enough to denude the lip, and alveolar ridge<sup>30</sup>.

### 14. Tuberculous Ulcers:

Granulomatous disorders can cause oral mucosal ulcers. Tuberculosis and leprosy can present as oral symptoms. Secondary to systemic disorders, but they are uncommon. Tuberculosis can be pulmonary or extrapulmonary in nature. Primary, secondary, and miliary tuberculosis are the three types of pulmonary tuberculosis. Primary tuberculosis is more commonly observed in children. It is usually asymptomatic, but it can cause a fever and a dry or productive cough. Oral lesions are relatively uncommon and occur as a result of the primary disease. The germs are most likely taken away in the sputum and enter the mucosal tissue through a small crack in the surface. Secondary TB oral symptoms can occur at any intraoral site, with the tongue being the most usually affected.

### 15. Syphilitic Ulcers:

The most prevalent cause of primary syphilitic ulceration is oro-genital or oro-anal contact with an infected lesion. The Because of its short duration, involvement of the oral cavity is extremely rare and rarely identified. 1 shows a deep ulcer with a jagged border. Chronic traumatic ulcers and squamous cell carcinomas are among the possible diagnoses. A brief history of sexual and social activities aids in the accurate diagnosis of such lesions. Secondary syphilis manifests as punched-out sores on the tongue. Tertiary syphilis manifests as a swelling with a yellowish centre that necrotizes, leaving a deep painless ulcer. The ulcer has rounded, soft edges with punched-out edges. The floor appears to be pallid and depressed. Serological assays have been found to be highly sensitive and specific.



## Factors affecting mouth ulcer

The exact cause of mouth ulcers is still not known and varies from person-to-person. Still, there are some common causes and several factors that may aggravate mouth ulcers, including the following:

- [quitting smoking](#) [Trusted Source](#)
- citrus fruits and other foods high in acidity or spice
- biting the tongue or inside of the cheek
- braces, poor-fitting dentures, and other apparatus that may rub against the mouth and gums
- a deficient filling
- [stress](#) or [anxiety](#)
- hormonal changes during pregnancy, [puberty](#), and [menopause](#)
- medications including [beta-blockers](#) and pain killers
- genetic factor

## conclusion

In the oral cavity, ulcers are typically common, and if they don't hurt, people ignore the lesions. Nevertheless, the It is the dentist's primary duty to examine such lesions even during routine appointments, counsel patients, and develop a treatment plan as necessary. To rule out malignancy, a proper history must be taken, including the patient's personal history and a comprehensive clinical examination. Dietary supplements and lifestyle changes can be used to cure or prevent canker sor

## Reference

- [1] Manju et al., IJPSR, 2021; Vol. 12(12): 6253-6259.
- [2] Mohd. Asif Dosani et al /Int.J. PharmTech Res.2011,3(3)
- [3] Cold sore, <http://www.medicinenet.com>.
- [4]Canker Sores / aphthous mouth ulcers, <http://www.TheraBreath.com>.
- [5] Martin T, mouth ulcers- a patient's guide, 1996 Oct 23 <http://www.medic8.com>
- [6] 1358-Article Text-2651-1-10-20201203 (1)
- [7 ]Medically reviewed by Christine Frank, DDS — By Jenna Fletcher on November 20, 2018
- [8] Livermore D.M, Intensive Care. Med. 26 ,2000 Suppl 1;S14–S21
- [9]Randle HW, et al. Treatment of oral ulcers. Dermatol Clin. 1993;11:801-808
- [10] Bruce AJ, et al. Acute oral ulcers. Dermatol Clin. 2003;21:1-5.
- [11]Woo SB, et al. Recurrent aphthous ulcers: a review of diagnosis and treatment. J Am Dent Assoc.1996;127:1202-1
- [12 ] Kolokotronis and Doumas S: Herpes simplex virus infection, with particular reference to the progression and complications of primary herpetic gingivostomatitis. Clin MicrobiolInfect 2006; 12: 202-11

[13] Hasan S, Jangra J, Choudhary P and Mishra S: Erythema Multiforme: A Recent Update. Biomed Pharmacol J 2018; 11: 167-70.

[14] <https://www.rroij.com/open-access/a-review-on-mouth-ulcer-and-its-various-treatment.php?aid=90551>

[15] Stoopler ET and Musbah T: Recurrent aphthous stomatitis. CMAJ:Can Med Assoc J 2013;185: E240-E241.

[16] Anura A: Traumatic Oral Mucosal Lesions: A Mini Review and Clinical Update. OHDM 2014; .

[17 ] Vujevich J and Zirwas M: Treatment of severe, recalcitrant, major aphthous stomatitis with adalimumab. Cutis. 2005; 76: 129-32.

[18 ] Sivapathasundharam B, Sundararaman P and Kannan K: Oral Ulcers - A Review. J Dent & Oral Disord. 2018; 4(4): 1098.

[19] Mouth Ulcers Treatment Market Size, Share Report 2018-2026

