



MANAGEMENT OF PILONIDAL SINUS BY EXCISION AND PRIMARY CLOSURE – A CASE STUDY

¹Dr Umar Shariff M Bellary, ²Dr Prabhakar H Taseen

¹Final year PG scholar. ² Professor

¹Dept of PG and PhD studies in Shalya Tantra

¹Ayurveda Mahavidyalaya and Hospital, Hubballi-580024, Karnataka

ABSTRACT: Pilonidal sinus is chronic acquired condition occurring at the midline pit situated in mid gluteal cleft at postanal region, which causes pain, discomfort, embarrassment and absence of mind from daily activities. Prolong sitting, obesity, repeated irritation due to hair. The incidence of the disease is calculated to be 26 per 100,000 people seen more in males than females, as males have more hairs, the buttocks moves and hairs breaks off by friction and collect in the cleft which makes local inflammation turns to sinus formation. In *Ayurvedic* science *acharya Sushruta* mentioned eight types of sinuses as *nadivrana*. Among these pilonidal sinuses can be considered under *shalyaj nadivrana* (sinus due to foreign body).

CASE STUDY

Aim and Objective: This study aims to estimate simple excision and tension free primary closure and to study its effectiveness in term of operating and healing time.

Result: The study involved a median age male patient (27 years). Mean operation time was 25-30 minutes. patient had full primary healing without any complication. No hematoma or seroma or wound infection and developed recurrence. hospital stay was 2 days, patient terms of healing time, complications, and rate of recurrence went back to his work within 3 weeks.

Discussion and conclusion:

Excision and tensionsfree primary closure have been found to be uncomplicated treatments associated to lower wound infection rates, shorter hospital stays, lower recurrence, early wound recovery, and brief absences from work. Surgery can be easily performed and preferred for cases of non-recurrent pilonidal sinus and cyst.

KEYWORDS: *Nadi vrana*, Pilonidal sinus, Primary closure.

I. INTRODUCTION

Pilonidal disease is a very common ano rectal problem that most often arises in the hair follicles of the natal cleft of the sacro coccygeal area most common in young adults of working age. Pilonidal Disease includes Pilonidal Sinus, Pilonidal Cyst and Pilonidal Abscess. Incidence was calculated to be 26 cases per 100000, affecting males twice as much as females. Men are thought to be at higher risk because of their hirsute nature. Pilonidal sinus is also associated with obesity (37%), sedentary occupation (44%) and local irritation or trauma (34%)¹.

Pilonidal disease is complex manifestation of acute abscess along with extensive, branching sinus tract formation. Though seen in other parts of the body, it is mostly occurred in the sacro- coccygeal area. This primary tract leads into a subcutaneous cavity, which contains granulation tissue and a nest of hairs projecting from the skin opening. Many patients have secondary lateral openings 2 to 5 cm above the midline pit. The skin opening and the superficial portion of the tract are lined with squamous cell epithelium, but the deep cavity and its extensions are not. Today pilonidal sinuses are widely accepted to be acquired abnormalities² as a result of the drainage of a hair follicle³ that ruptured in the subcutaneous fat, producing acute or chronic inflammation⁴ resulting in an abscess or a tract. The management of pilonidal sinus depends on its presentation and ranges from simple incision and drainage to a wide excision with extensive reconstructive procedures. There is no clinical consensus on the optimal management of the pilonidal sinus and our objective is to compare the methods used by our clinic and determine the outcomes in relation to healing, hospitalization time and recurrence.

In *Ayurveda* no direct reference to pilonidal sinus (PNS) as a disease entity is found. However, *Sushruta* has described that hair can be a root cause⁵. Pilonidal sinus is correlated to *Nadi Vrana* to some extent, where '*Nadi*' implies tract and '*Vrana*' is the ulcer. So, an ulcer or *vrana* which is having a tract or *nadi* can be named as *Nadi Vrana*.⁶ *Shalyaja* *Nadivrana* also called as *Agantuja nadivrana* holds better correlation with pilonidal sinus, as '*bala*' (Hair) is one of the prime causing factors in disease formation. *Acharya* has also given numerous minimally invasive treatment which includes *Pratisaraneeya kshara* karma, *Kshara sutra* karma, *Chedana*, and *Bhedana*.⁷

II. A CASE STUDY

2.1 Patient details

Name	Salman
Age/sex	27years/Male
Address	Hubli
Opd No	23006870
Occupation	Auto driver
Marital status	Married
Date	13/05/2022

A 27-year-old boy approached our hospital with complaints of Swelling associated pain and pus discharge from the sacrum region, with intermittent fever since 6month.

2.2 Place of study

P.G and PhD studies, department of *shalyatantra* Ayurveda Mahavidyalaya and Hospital, Hubballi.

2.3 History of Present illness

Patient was apparently normal 6 months back and he initially develops low back pain for prolonged sitting, and swelling in the sacrum region. He consulted local doctor, symptoms got reduced. Again, he developed swelling severe pain and pus discharge in natal cleft region with fever. So, he consulted our hospital for further management.

2.4 Past History

Patient was n/k/c/o HTN/DM/IHD/BA. There was no prior surgical intervention in the patient's history.

2.5 Family History - Nothing significant, all the family member healthy and have no H/O any other severe illness contributory to the patient condition.

2.6 Personal History

- Appetite- Normal
- Bowel- One time/day
- Micturition- 3-4 time a day
- Sleep- Disturbed
- Habits- Smoking, Chewing tobacco.

2.7 Systemic examination

- **RS – NVBS** no added sound
- **CVS S1 S2** heard at left 5th i/c space, no murmurs
- **CNS** Patient was conscious well oriented to time, place and person

2.8 Local Examination

INSPECTION

- Number of swellings:1
- Position/site: Natal cleft
- Discharge: Present
- Surrounding skin color: Whitish red in color.

PALPATION

- Warmth - present
- Tenderness – present

EXAMINATION WITH PROBE

During the probe insertion it showed a external opening but there wasn't another opening

Finding of examinations: "A scar measuring 6 cm at 6 O'clock position was found with external openings on end of the scar, at about 10 cm away from anal verge with tenderness"

2.9 Investigation

Hb%	11.5gm %
RBS	115.7 mg/dl
HIV	Negative
HBsAG	Negative
Blood Group	B positive
ESR	20 mm/hr
Bleeding time	1min 50 sec
Clotting time	3min 40 sec
CRP	3.5 mg/dl
Urine – Sugar	Nil
- Albumin	Nil
- microscopy	NAD

2.10 Diagnosis PILONIDAL SINUS (*NADI VRANA*)

2.11 Treatment advised

Excision and primary closure of the wound

2.12 PLAN FOR THE STUDY

The selected patient diagnosed as PILONIDAL SINUS (*NADI VRANA*) from O.P.D. of Shalya Tantra Department of Ayurveda Mahavidyalaya and hospital, Hubballi was admitted to the procedure with I.P.D. on 13/05/2022 with OPD/IPD No. 23006870 Base line data collection and laboratory investigations were done and informed consent was taken before EXCISION AND PRIMARY CLOSURE OF THE WOUND.

2.13 PROCEDURE IN DETAIL

Purva karma:

- Routine investigations were within normal limits.
- Part was prepared.
- Inj. Xylocaine (test dose) was given intra-dermally
- Inj. T.T was given intramuscularly

Pradhana karma:

- Patient was taken to operative theatre and made to lie in dorsal position part was painted with betadine solution followed spirit wash done and draping of the part was done with sterile cloth.
- Inj. Xylocaine with Adrenaline was infiltrated locally around the part of operation
- Intra-operatively, a syringe filled with Betadine solution was injected through the external opening to see if there was any connection with the anal canal. It was seen that the solution was coming from the natal cleft which confirmed a diagnosis of PNS and not *fistula in ano*.
- An elliptical incision was taken over the natal cleft till the pre-sacral fascia to excise the sinus, and a bunch of hair was removed.
- The tract measuring about 6 cm, extending from base of natal cleft to the external opening over the scar was extracted completely from the base, wound was scrapped followed by wound toileting/irrigation done with betadine solution and hydrogen peroxide and the wound was closed with vicryl suture material.

Paschat karma:

The post-operative course was uneventful. Patient was irregular for the follow-up dressing. Complete healing occurred after four weeks.

III. DISCUSSION

Different treatment methods for PNS ranges from an extreme conservative, non-surgical approach to extensive surgical procedures with full thickness flaps techniques. The ideal treatment of PNS remains a controversial. The ideal surgery should be simple, with short hospital stay, have a low recurrence rate, associated with minimum pain and wound problems. The commonly adopted surgical techniques in contemporary science for management of PNS. Broadly there are three types of Management -**Firstly**- Excision and Healing by secondary intention, **Secondly** -Excision and Primary closure is more cosmetically acceptable and is associated with shorter healing time and time off work, **Thirdly** -Excision with reconstructive procedures are more technically demanding. For unhealed, complicated and recurrent PNS and unhealed midline wound, more aggressive treatment with rhomboid flaps, Z plasty or gluteal mucocutaneous flap are used.

Surgery should remove the sinus tract and cleft in which the hair tends to accumulate but also aim to establish complete and fast healing and to prevent recurrence. Simple excision and healing by secondary intention causes more patient discomfort, needs more painful dressings, requires longer time for healing and more time off work. Primary closure provides an earlier wound healing, reduced hospitalization and less time off work when compared to lay open techniques or marsupialization. Obliteration of the concavity of natal cleft, gives better wound healing and minimizes recurrence, various methods have been proposed. Here the patient was excised the sinus tract and partial closure was done and left for healing and the wound was completely healed in 4 weeks.

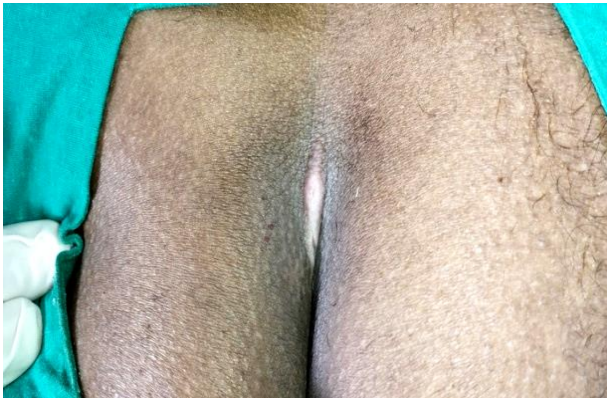IV. CONCLUSION

For uncomplicated pilonidal sinus, and sinus tract measuring upto 6 cm, excision and primary closure is a safe procedure. It is easy, simple, less interfering, painless, reducing hospital stay, quick healing, allowing early resumption of the work by patient and low recurrence rate.

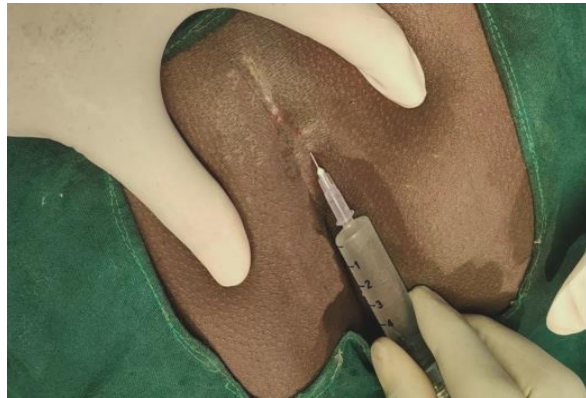V. REFERENCE:

1. Sondena K, Andersen E, Nesvik I. Patient characteristics and symptoms in chronic pilonidal sinus disease. *Int J Colorectal Dis.* . 1995;10:39–42. [[PubMed](#)] [[Google Scholar](#)]
2. King ES. The nature of the pilonidal sinus. *Aust N Z J Surg.* 1947;16:182–192. [[PubMed](#)] [[Google Scholar](#)]
3. Bascom J. Pilonidal disease: origin from follicles of hairs and results of follicle removal as treatment. *Surgery.* 1980;87:567–572. [[PubMed](#)] [[Google Scholar](#)]
4. Surrell JA. Pilonidal disease. *Surg Clin North Am.* 1994;74:1309–1315. [[PubMed](#)] [[Google Scholar](#)]
5. Yadavji Vaidya, Trikamji Acharaya T., editors. publisher Chaukambha Surbharati Prakashan; 2003. Sushruta Samhita With Nibhndha Sangraha Tika Of Dhalana; pp. 307–408. Varnasi, Nidanasthana 10th Chapter Page No. [[Google Scholar](#)]
6. Dr. Rajasree G, Dr. Anita K. Patel. A Review on Salyajanya Nadi Vrana (pilonidal sinus) with clinical approach. *J Ayurveda Integr Med Sci* 2019;2:85-89. <http://dx.doi.org/10.21760/jaims.4.2.16>
7. Vaidya Yadavji, Trikamji Acharaya., editors. *Chikitsa sthana 17th Chapter.* Varnasi: Chaukambha Surbharati Prakashan; 2003. Sushruta Samhita With Nibhndha Sangraha Tika Of Dhalana; p. 468. [[Google Scholar](#)]

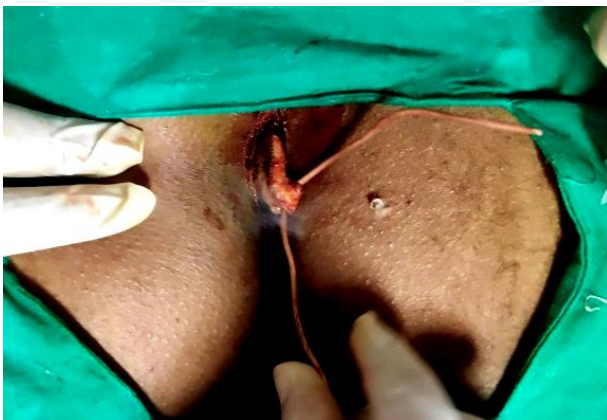VI. PICTURES



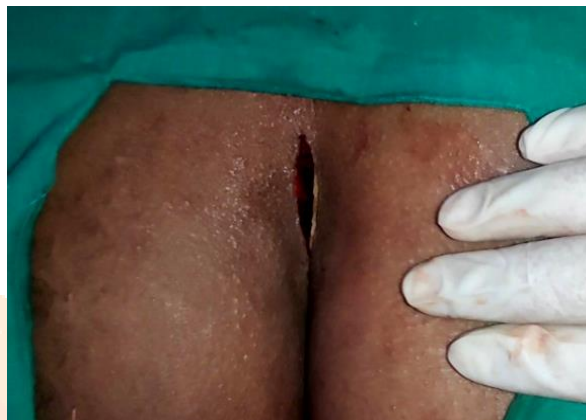Before treatment



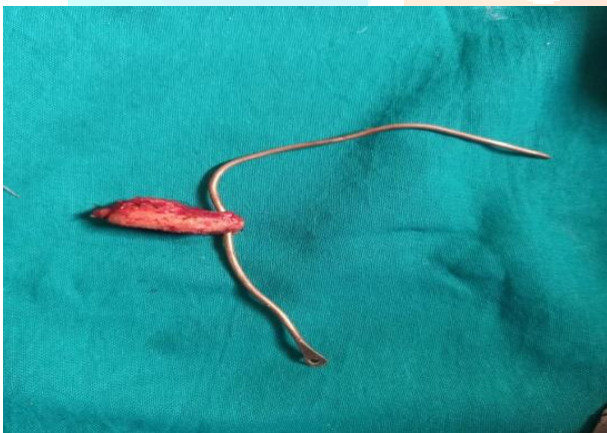Infiltration of local anesthesia



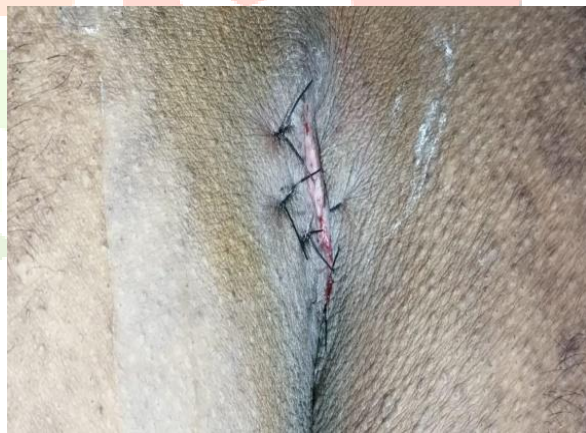Excision of the traced sinus tract



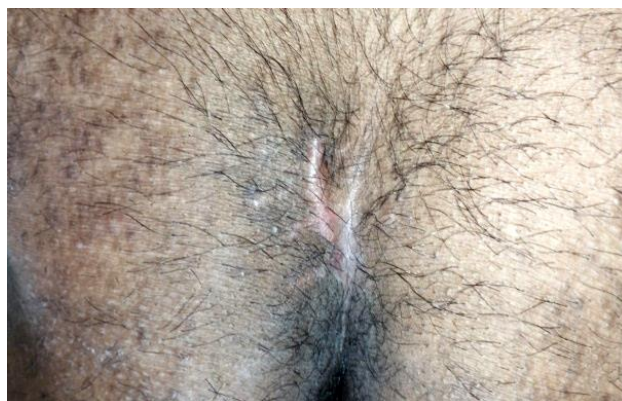
Elliptical incision taken



Excised sinus tract



Wound closure using suturing



After treatment