



“Review On: Mouth Ulcer”

¹Miss. Shinde. V. H , ²Miss.Telange Patil. P.V , ³Miss.Dupade . S. S · ⁴Miss Tagalpallewar .S. R

¹Assistant Professor,²Assosiat Professor,³ Student · ⁴Student.

¹Pharmaceutical Department,

¹College of Pharmacy, Paniv, Malshiras, Solapur, Maharashtra, INDIA

Abstract: An oral ulcer is a sore that develops on the oral cavity's membrane. “A breach within the mucosal surface of the buccal cavity,” according to the definition. Ulcers are uncovered sores of the surface or mucous membrane in which inflammatory dead tissue is removed. Despite their significant incidence, the etiopathogenesis of many diseases is unknown. It's frequently painful, and it's accompanied by redness, swelling, and bleeding in the affected area. The mouth ulcer commonly causes pain and discomfort, and it might affect a person's eating preferences as it heals. According to how they present and progress, they might be classed as acute or chronic. Trauma, recurring aphthous stomatitis, Behcet's illness, bacterial and viral infections, allergic reactions, and bad drug reactions are all linked to acute oral ulcers. chronic oral ulcers are linked to illnesses like oral lichen planus. Ulcer is common disorder which is among people. Many types of ulcer present but mouth ulcer is, healing it frequently causes pain and discomfort and may change the person's eating preferences. The two most frequent causes of oral ulceration are aphthous stomatitis and local trauma. A number of synthetic drug are available to treat mouth ulcers. But these drug are expensive and are likely produce more side effects when compared and to herbal medicines. The ideal aims of treatment mouth ulcer using hibiscus leaf extract and other exipients to from the formation. In the review attempts have been made to hibiscus leaf which may be used ayurvedic as well as modern science for to prevention of mouth ulcer.

Index Terms : ulcer, mucosal, buccal, illness, cavity,etc.

I. INTRODUCTION

Ulcers are an open sore of skin or mucus membrane characterized by inflamed dead tissue (1). Ulcer are lesions on the surface of the surface of the skin or a mucus membrane characterized by a superficial loss of tissue. Ulcers are most common on the skin of the lower extremities and in the gastrointestinal tract, although they may be encountered at almost any site. There are many types of ulcer such a mouth ulcer such a mouth

ulcer, esophagus ulcer, peptic ulcer, and genital ulcer. Of these peptic ulcer is seen among many people. The peptic ulcer are ersion of lining of stomach or a duodenum (2). Peptic ulcer is ab acid induce lesion of the digestive tract is usually located in the characterized by denuded and is extending into the sub mucosa or muscularis propria (3). The estimate prevalence of peptic ulcer disease in the general population is 5-10% (4) but recent epidemiology studies have shown a decrease with peptic ulcer (5,6,7,8,9,10,11,12). Most drug can caused different variation of pill esophagitis and be

presented in different spectrums of complications, such as mucosal inflammation, ulceration, bleeding penetration, perforation on transmitted infection facilitates various. It may be cause bleeding and it cases local HIV replication and increasing the odds of transmission from the index partner. In exposed partner, GUD provides a portal of entry and target cell available locally for HIV (13). Diabetes mellitus affects approximately 422 million people worldwide is responsible for an estimated 2 million deaths per years (14). Diabetic foot ulcer is a debilitating and severe manifestation of uncontrolled and prolonged diabetes that presents as an ulceration, usually located at the plantar as per of the foot. Approximately 15% of individuals with diabetes will require amputation of the ulcerated foot due to bone infection or other ulcer related complications (15). Based on the duration ulcers can be broadly classified into acute (short term) or chronic (long term). Acute ulcers persist no more than three weeks and regress spontaneously such as traumatic ulcers, aphthous ulcers, herpetic ulcer and chancres. Chronic ulcers persist for weeks and months such as major aphthous ulcers from odontogenic infection, malignant ulcer gummas, ulcers secondary to debilitating systemic disease and some traumatic ulcer (with a persistent traumatic element (16). Ulcers may arise local application of aspirin (17). Cocaine, or smoking crack (e.g on the palate)(18). Snorting cocaine may rarely cause necrosis, possibly associated with ischaemia, at the floor of base and eventual ulcers of the hard palate and oronasal fistula formation (19). Ulcers are recurrent lesions that to result in tissue loss. They are relatively common oral mucosa lesions that damage both the mucosa and the underneath connective tissue (20). In dentistry mouth ulcers are painful mucosal lesions, which are often

location in the tongue, gum cheek or lip (21). In the general population the incidence of mouth ulcers is 5-20% (22,23,24). Trial from recent studies showed that various types of extracts from all *H. rosa-sinensis* corridor displayed a wide range of salutary good analogous as cancer-diabetic, crack mending and abortifacient extraction (25). Hibiscus is one of Hawaii's admired national plants, and it is often seen worn in hair for cultural occasions (26). Family malvaceae, and it is one of the 300 species of the genus Hibiscus (27). Addition, the juice extracted for from the leaves and flowers has been used since a long time ago as natural remedy for some disease and painful symptoms, as well as in herbat cosmetics as wilted (28,29). The plant is commonly cultivated as a home garden crop in tropical regions including the Caribbean, central America, India, Africa, Australia, Hawaii Florida, and the Philippines(30). Hibiscus edible seed oil is used as substitute, for castor oil and to produce scrubs and soups. The flower are widely used as organic herbal tea and seed are often a coffee substitute. Hibiscus leaves are used for culinary purpose, the tea leaves are considered a vegetable (31). There is insufficient information about the safe use of hibiscus for pregnant women. It is better to taken doctors advices during this condition(32).

Scientific classification of hibiscus plant

Kingdom- plantae

Subkingdom- Tracheobionta

Super division- Spermatophyta

Division- Magnoliophyta

Class- Magnoliopsida

Subclass- Dilleniidae

Order- Malvales

Family- Malvaceae

Genus- Hibiscus

Species- Hibiscus rosa-sinesis

Origine- Tropical asia

X- 9

2n- 45, 54, 63, 72.

Floewr colour- White, Red pink, Yelloe

Hibiscus rosa-sinensis, known as the Chinese hibiscus, China rose and shoe flower.

An evergreen flowering shrub. A native of Southeastern Asia (China).

Most ornamental varieties are hybrids as the present wide range of cultivars is considered to be a complex of interspecific hybrids, between 8 or more different species.

The national flower of Malaysia.

Botany- Simple leaves, arranged in alternately, long and glossy green simple leaf.

Ovate- Lancolate, alternately arranged, leathery.

Inflorescence- Soliatry/Cymose.

Calyx- 5 sepals, fused, valvate, hypogynous.

Corolla- 5 petals, red in colour distinct,

Hypogynous.

Chemical constituent-

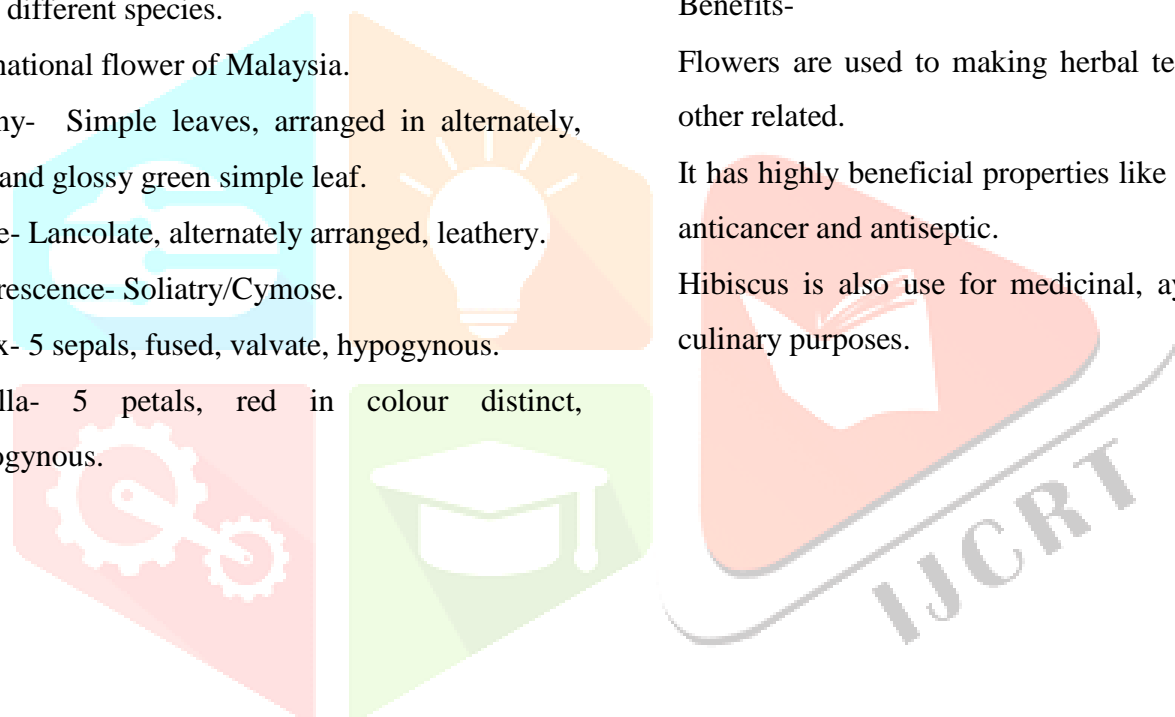
Different extract od Hibiscus rosa-sinensis plant revealed the presence of alkaloids, fatty materials, reducing sugars, resin, sterods and the lack of tannins and Saponins. Isolation of B-sitosterol, taraseryl acetate and four uncharacterized compound which included an alkaloid and three sterols has been reported in the leaves. The leaves of Hibiscus rosa-sinensis were also investigated for their fatty alcohol, fatty acids and hydrocarbon content. Two cyclic acids viz., malvalic and sterculic are also identified.

Benefits-

Flowers are used to making herbal tea, food and other related.

It has highly beneficial properties like antioxidant, anticancer and antiseptic.

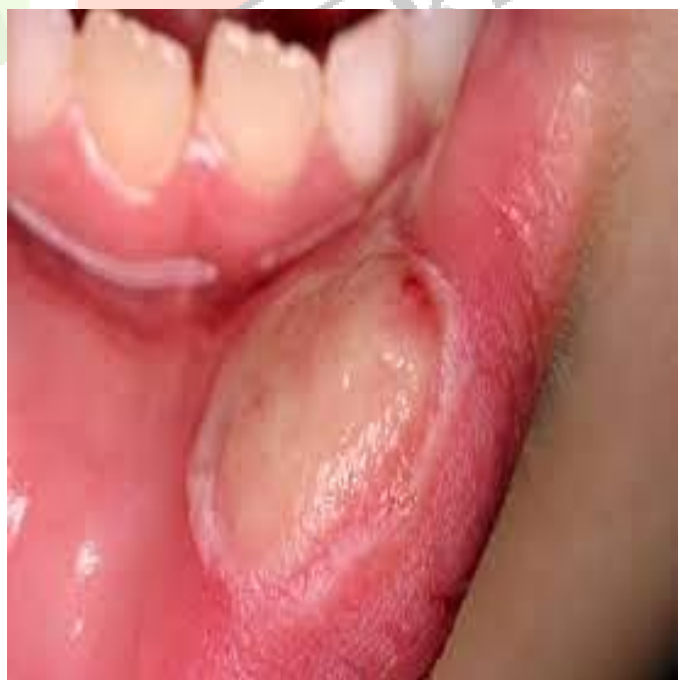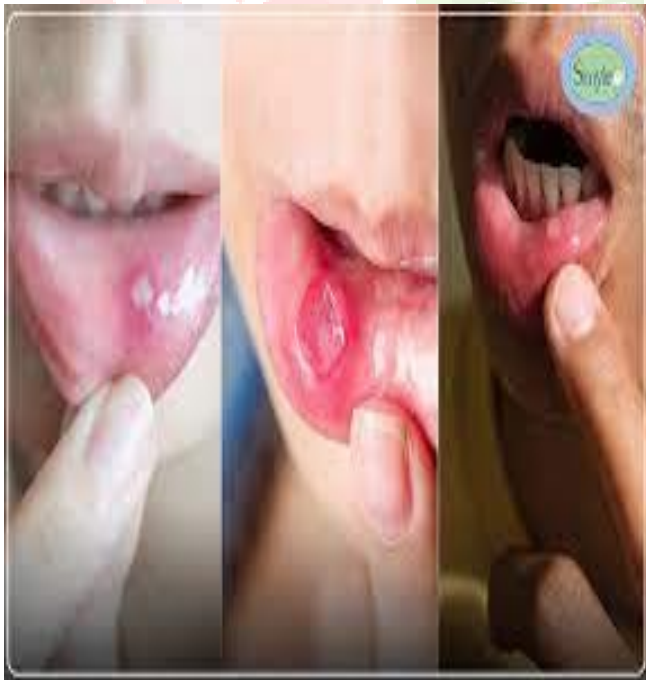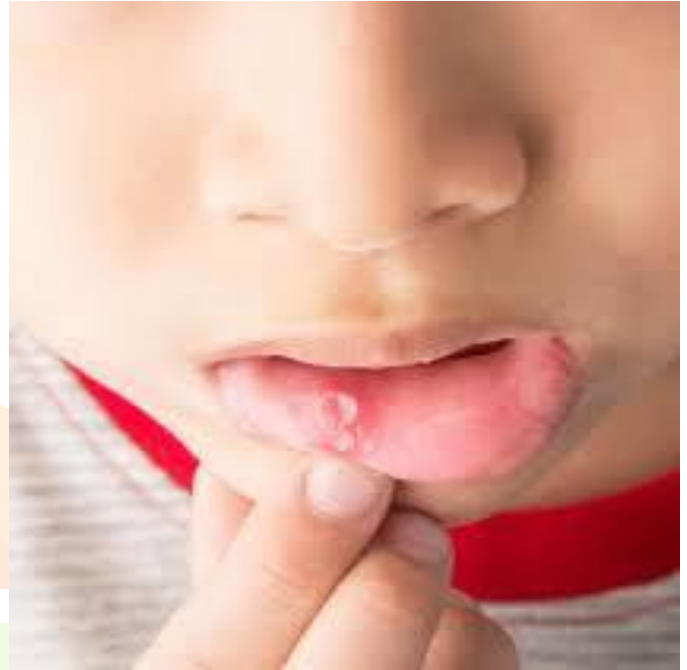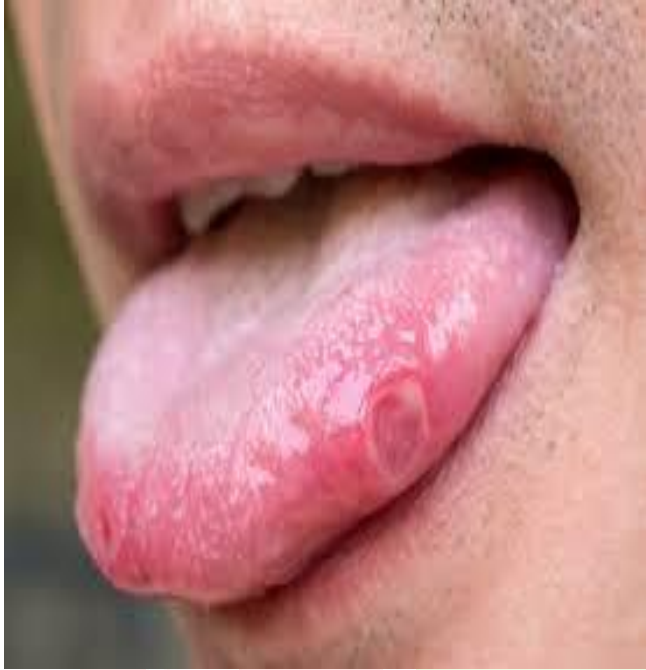Hibiscus is also use for medicinal, ayurvedic and culinary purposes.





2.Symptoms:

- The symptoms of a mouth ulcer deped on the cases, but may include
- one or more painful sores on part of the mucous membrane lining the mouth.
- Swollen and red mucous membrane around the sores.
- Problems with chewing tooth brushing because of the tenderness.
- Irritation of the sores by salty, spicy of sour foods.
- Irritation of the sores by dentures, orthodontic or mouth splints.
- On occasions on ulcer may not be sore. This can occurs in cause mouth cancer.



3.Pathophysiology

The pathogenesis of recurrent aphthosis stomatitis (RAS) poorly defined. It likely involve a predominantly cell-mediated inflammation involving T-cell and TNF-alfa (tumor necrosis factor-alpha) production. Light and electron-microscope examination of oral aphthous ulcers showed a penetrating, early, lymphomonocyte infiltration of the epithelium. According to a study by Lehner (33), under light microscopy, oral ulcer epithelium showed considerable intercellular edema and degenerative changes. There was epithelial hyperplasia and only the basement membrane adjacent to the ulcer was affected, the rest of the basement membrane appeared intact. Mononuclear cells normally infiltrate the basal cell and prickle cell layers of the epidermis and they are most commonly lymphocytes and monocytes, but superficial to and immediately adjacent to the ulcer neutrophil polymorphs were also found. According to Lehner (33), the intra-nuclear inclusion bodies were found in 3 out of the 25 biopsies examined by electron microscopy. The affected nuclei were slightly large and the nucleoli were uneven in shape. Inclusion bodies were not seen in the cytoplasm. Herpetic form ulcers differ from recurrent aphthous ulcers in that they showed epithelial vesicles and intra-nuclear inclusion bodies, suggesting a virus etiology. The immunology fluorescent studies showed predominantly IgG and IgM binding only in

autologous tissues from patients with aphthous ulcers (34). This reaction could indicate blood group antigens, trapped globulins due to the inflammatory reaction, non immunological physicochemical binding of the fluorescent conjugate, or normal immunoglobulin transport through the oral mucosa. An immune fluorescent examination couldn't detect specific globulin binding to salivary gland tissue in the oral aphthous ulcers, but they have an increase in the degree of severity of the pathological changes, There were no vascular abnormalities and fibrous necrosis noticed in recurrent oral ulcers. A three fold rise in mast cells was found in recurrent oral aphthous, in contrast to a decreased count in non specific ulcers. Mast cell count was present in all three groups of oral ulcers when it was compared with that in other oral lesions and normal tissue. Leukocytes have a normal chemotactic function in oral aphthosis but in Behcet's a chance that a few immunologically arbitrated mechanisms are playing an important role in the pathogenesis of oral aphthosis. It in the pathogenesis of oral aphthosis. It may be due to an unopposed or excessive production of IL-1 (interleukin) or IL-6, which is essential for its development, a concept that may explain why ulceration worsens after local injury, or cessation of smoking, or both (35).

4. Treatment

Allium sativa

The liliaceae family *Allium sativum* is usually referred to as “garlic”. The active ingredient in this plant is an acrid volatile oil, which is also found in starch, mucilage, albumen, and sugar. A seeds produce fragrant oil vitamin rich, supplementary compound (36). It reported by Randa after 8 weeks of garlic and black seed diet, plasma MDA showed a significant decrease, ($p < 0.001$), according to a study. MDA levels good indicators of lipid peroxidation as people get older. GSH-Px was considerably greater ($P < 0.05$) in erythrocytes after 8 weeks of ingestion of garlic black seed combination. Further more, SOD activities were also significantly higher ($P < 0.05$) after consumption of a the combination of garlic and black seeds for same period (37).

Ginger

In traditional medicine, ginger is one of the most commonly used herbs. A number of research have also confirmed and proved ginger's anti-inflammatory properties. Haghpanache et al. the researchers found that a bioadhesive, ginger film pain in RNA patients, however that the change in ulcer width, inflamed halod and bet healing duration were not substantially different from placebo (38, 39).

Aloe vera

The biological source of Aloe vera is *Aloe barbadensis*. It belongs to the family Xanthorrhoeaceae.

Morphology: Aloe vera is a stemless or very short stemmed plant growing to 60-100 cm (24-39) tall, spreading by offsets. The leaves are thick and fleshy, green to grey-green, with some varieties showing white flecks on their upper and lower stem surfaces. The margin of the leaf is serrated and has

small white teeth. The flowers are produced in summer on a spike up to 90 cm (35 in) tall, each flower being pendulous, with a yellow tubular corolla 2-3 cm (0.8-1.2 in) long. Like other Aloe species, Aloe vera forms arbuscular mycorrhiza, a symbiosis that allows the plant better access to mineral nutrients in soil.

Plant part used: Leaves, flowers, stems, roots, fruits, seed.

Chemical constituents: The chemical constituents in Aloe vera are Anthraquinones, Saccharides, Prostaglandins and fatty acid. **Other:** Enzymes, amino acid, vitamins, minerals. **Other compounds:** Cholesterol, triglycerides, steroids, uric acid, lignins, beta-sitosterol, gibberellins, salicylic acid.

Uses: It is analgesic, antibacterial, antiviral, antifungal, antioxidant immune modulating, antiseptic, anti-inflammatory. Aloe vera is used in the sites of periodontal surgery, toothpick injuries, chemical burns, aphthous ulcers, gum abscesses, dry socket, lichen planus, benign pemphigus and gingival problems associated with AIDS, leukemia, migratory glossitis, geographic tongue and burning mouth syndrome, denture sore mouth, candidiasis, desquamative gingivitis, vesiculobullous diseases, acute monocytic leukemia, xerostoma(40).

Hibiscus rosa sinensis

Hibiscus rosa sinensis (Malvaceae) is commonly known as “chajang rose.” It is locally called “chembaruthi”. It is native to China and grown widely as an ornamental plant through India. Chemical constituents in this plant are flavonoids, anthocyanins, quercetin, cyanidin, kaempferol, and hydrocitric acid(41).

The root of *H. rosa sinensis* is traditionally used for the treatment of ulcer among the Kani tribes in Kanyakumari district, Tamil Nadu, India(41).

Baseline treatment**Analgesia****Simple mouthwashes** (saline)

To relieve pain for traumatic ulceration. Made up with warm water and used frequently until discomfort and swelling subsides

Aseptic mouthwashes

To prevent secondary bacterial infection which can delay healing of any type of oral ulceration

**First line treatment****Topical corticosteroids**

(hydrocortisone oromucosal tablets, betamethasone soluble tablets)

Duration of treatment varies by case. Most effective in the 'prodromal' phase early in ulcer formation. Beclomethasone spray via inhaler device is sometimes used off-license.

NB risk of oral candidiasis with oral corticosteroid use

**Second line treatment****Topical anaesthetic** (lidocaine)

Limited role due to short duration of action when applied topically

Topical analgesics/anti-inflammatory agents

(benzydamine hydrochloride, flubriprofen, choline salicylate)

Excessive application or confinement under dentures may irritate mucosa and itself cause ulceration

Antibiotic rinses (doxycycline rinse)**Oral vitamin B12** (cyanocobalamin)

Consider use irrespective of serum vitamin B12 levels

**Further treatment****Systemic steroids**

(prednisolone)

A short course of systemic prednisolone may be prescribed for those with severe recurrent aphthous ulceration

Referral for specialist input

Ulcers refractory to treatment – low threshold for referral

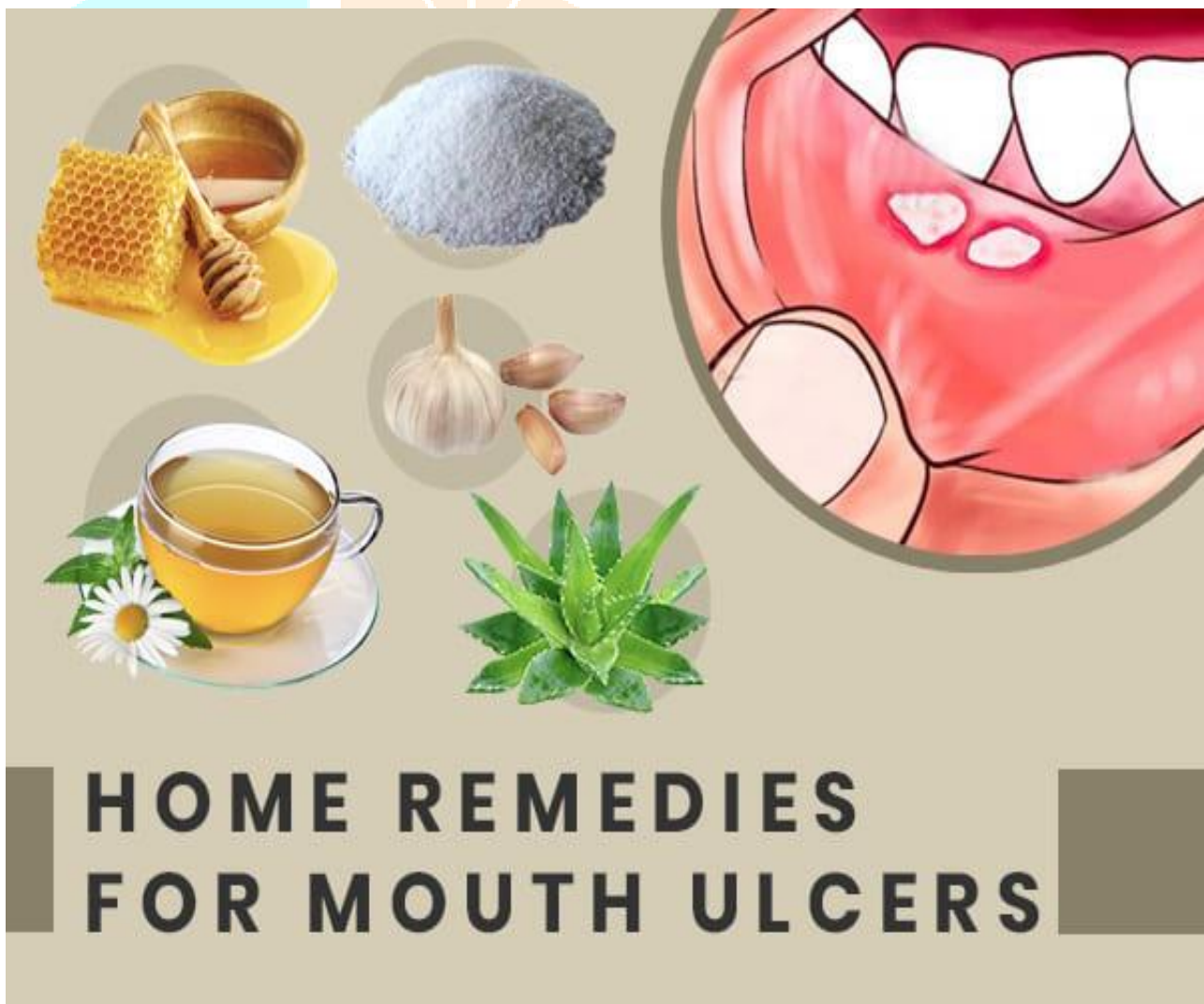5.Prevention:

- While you can't prevent mouth ulcers altogether, there are three things you can do to reduce your risk

brush your teeth twice daily and floss one daily for optimal oral health.

- Use a soft bristled tooth brush to avoid tissue irritation.
- Eat a healthy diet rich in fresh fruits and vegetables.
- Eat a healthy diet rich in fresh fruits and vegetables.

- Visit your dentist regularly for checkups and cleaning.
- Not chewing gum.
- Reducing stress and anxiety.
- Which may be a trigger for some people.
- Using toothpaste that doesn't contain sodium lauryl sulphate.
- Making sure that underlying conditions as well are well controlled.



6. Conclusion

Oral ulceration diagnosis is always challenging and need a thorough history taking and clinical examination. The fact cannot be denied that oral presentation may be a sign of some larger underlying systemic disease. Any ulcer that lasts longer than two weeks should be examined histopathologically. As you can see, many items cause mouth ulcers and irritate the tissue. It's best to eat these food in moderation. Cut down on the foods contributing to canker sores; you don't have to ban them entirely. Mouth ulcer done widespread disorder of mouth with recurrent release and several

complications also allopathic drugs used inare its treatment associated with adverse effect causing further damage to human health. As a aim this review are focusinr on herbal plant having therapeutically effectives. These herbal plants are rich, several phytochemical such as alkalords, tannins, flavonoids, phentos, saponins ets, isolated and use of these compound! Provides health benefits. Therefore the drug gastrointestinal medicinal plant having mouth ulcer potential were discussed here which are not only safe but are also relatively chea.

7. References:

1. F.K.L. Chan and D.Y. Graham, "review article preventionof non steroidal anti-inflammatory drug gastrointestinal complications review and recommendations based on risk assessment," *Alimentary pharmacology, and therapeutics*, vol. 19, no. 10, pp. 1051-1061,2004.
2. B. Debjit, C. Chiranjib, K.k. Tripathi, pankaj, and K.P. sampath Kumar, "Recent trends of treatment and medication peptic ulcer active disorder," *International Journal of pharm Tech Research*, vol.2, no-1, pp. 970-980,2010.
3. Narayanan M., Reddy K.M., Maricano E. Peptic ulcer disease and Helicobacter pylori infection. *Mo.. Med.* 2018; 115: 219-224.
4. Lanas A., Chan F.K.L Peptic ulcer disease. *Lancet..* 2017; 390: 613-624. Doi: 10. 1016/so140-6736[16]32404-7.
5. Lanas A., Garcia-Rodriguez L.A., Polo-Tomas M., Ponce M., Quintero E., Perez-Aisa M.A., Gisbert J.P., Bujanda L., Castro M., M unoz M., et al. The changing face of hospitalisation due to gastrointestinal bleeding and perforation. *Aliment. Pharmacol. Ther.* 2011; 33: 585-591. Doi: 10. 1111/1.1365-2036, 2010.04563.X.
6. Sonnenberg A. Review article: Historic changes of helicobacter pylori associated disease. *Aliment. Pharmacol. Ther.* 2013; 38: 329-342. Doi: 10.1111/apt. 12380.
7. Higuchi D, Sugawac, Shah SH, Tokioka S, LUCAS CE. Etiology, treatment and outcome of esophageal ulcers; a 10-year experience in an urban emergency hospital. *Gastointest surg* 2003;7:836-42.
8. Abid S, Mumtaz K, Jafri W, et al. Pill-induced esophageal injury: endoscopic features and clinical outcomes. *Endoscopy* 2005;37:740-4.
9. Bott S. Medication include esophageal injury: survey of the literature. *Am J Gastroenterol* 1987;82:758-63.
10. Yamaoka k, Takenawa H, Tajiri K et al. A case of esophageal per formation due to a pill-induced ulcer successfully treated with conservation measures. *Am j Gastroenterol* 1996;91:1044-5.
11. Pace f, Antinori S, Repici A. What is new "in esophageal injury infection, drug induced, caustic, stricture, perforation? *Curr opin Gastroenterol* 2009;25:372-9.
12. Bott's prakash C, McMallum RW. Medication induced esophageal injury: Survey of the literature. *Am J G astroenterol* 1987;82:758-63.
13. Fleming, DT.; Wasserherit, J.N., for epidemiological synergy to public health policy and practicr: The contribution of other sexually transmission diseases to sexual transmission of HIV infection sex: *Transm infect.*

14. GBD 2019 Diabetes in the Americas Collaborators Burden of diabetes and hyperglycaemia in adults in the Americas, 1990-2019: a systematic analysis for the Global Burden Study 2019. *Lancet Diabetes Endocrinol.* 2022;10:655-667.
15. University of California San Francisco. Vascular and Endovascular Surgery Diabetic foot ulcers. [Cited 22 October, 2012].
16. Munoz Corcuera M, Esparza a Gomez and Genzalez moles MA, Bascones Martinez A. Oral ulcers: Clinical aspects. A tool for dermatologists. Part1. Acute ulcers. *Clinical and experimental Dermatology.* 2009;34:289-294.
17. Dellinger TM, Livingston HM. Aspirin burn of the oral cavity. *Ann Pharmacother* 1998;31:1107.
18. Parry j. Porter S. Scully c, Flint S. Parry Mc. Mucosal lesions due to oral cocaine use. *Br Dent* 1996;180:462-4.
19. Lancaster J. Bello so A. Wilson (A, Mclormick M. Rare case of naso oral Fistula with extensive osteocartilaginous necrosis secondary to cocaine abuse: *Laryngol Otol* 2000;114:630-3.
20. Munoz-Corcuera M, et al. Oral ulcers: clinical aspects. A tool for dermatologists. Part II. Chronic ulcers. *Clinical and Experimental Dermatology.* (in *Dermatol.* 2009;34:456-461.
21. Yan H, Jin Z, Jin W, et al. A systematic review and meta analysis acupuncture treatment for oral u;cer. *Medicine (Baltimore).*
22. Bas Y, Seckin HY, Kalkan G, et al. Investigation of Behcet's disease and recurrent aphthous stomatitig freduency: the highest prevalence in turkey. *Balkan Med J* 2016;33:390-5.
23. Souza PRM, Duguia RP, Breunig JA, et al, Recurrent aphthous stomatitis in 18 year old adolereents. Prevalence and associated factors: a population based study. *An Bras Dermatol* 2017; 92:626-9.
24. Han M. Fang H, Li QL, et al. Effectiveness of laser therapy in the management of recurrent aphthous stomatitis; a systematic review. *Scientifica (Cairo)* 2016; 2016: 9062430.
25. Asmaa missouh, An update review on hibiscus rosasinesis phytochemistry and medicinal uses, *Journal of Ayurvedic and Herbal medicine* 2018 4(3): 135-146.
26. Bragli L Bruna S, Lanteri S, Mercuri A, Portis E, An AF/P. Based assessment of the gers genetic diversity within *Hibiscus rosa-Sinensis* and its place within the *Hibiscus* genes complex. *Scientia Horticulturae* 2010; 123(3):372 378.
27. Melzer MJ, Simbajion N, Carillo J, Borth WB, Freitas-Astua, KItajima EW, al. A cilevirus infect's ornamental hibiscus in Hawaii. *Archives of virology.* 2013;158(11):2421-2424.
28. Ready UK, Rajesh S Sindhy G Aruna B. Herbs used in formulation poly herbal hair oil. A review *Indo American Journal of pharmaceutical Research.* 2017;4(6):1527-1539.
29. Kymani OS, Rao NB, Reddy VK. Phytochemical analysis and anti microbial activity of *Hibiscus rosa-sinensis*, wold *Jouirnal of pharmacy and pharmaceutical Sciences.* 2015;4(5):766-771.
30. Shruthi AR, Roselle (*Hibiscus Sabdariffa*) as a source of natural colours: a review plant *Archives,* 2016;16(2):515-22.
31. Solangi A, Siddiqui A, Junejo S, Younisarain M, Aslam Ansari M, Talpur A, et al. Roselle (*Hibiscus sabdariffa* L). A Multipurpose medicinal plant and it uses: AReview. *Int J Biol Res.* 2017;5(1):21-24.
32. Jadhav V, Thorat R, Kadam V, Sathe N, Jadhav V, Traditional medicinal uses of *Hibiscus rosa- sinensis.* *Journal of pharmacy Reasearch.* 2009;2(8):1220-1222.
33. Lehner T. Pathology of recurrent oral ulceration and oral ulceration in Behcet's syndrome: light, electron and fluorescence microscopy. *J Pathol.* 1969;97(3):481-94.
34. Brozovic S, Vucicevic-Boras V, Bukovic D. Serum LfA, IgG, IgM and salivary LgA recurrent aphthous ulceration. *Coll Antropol.* 2001;25(2):633-7.
35. Scully C, Porter S. Oral mucosal disease: recurrent aphthous stomatitis. *Br J Oral Maxillofac Surg.* 2008;46(3):198-206.
36. Mostsfa RM, et al. Antioxidant effect of garlic (*Allium sativum*) and black seeds (*Nigella satival* in healthy postmenopausal women. *SAGE OPEN Med.* 2013;1:2050312113517501.
37. Babarand M, et al. Herbs in oral mucositis *J Cin Diagn Res* 2017;11:05.
38. Haghpanah P, et al. Muco-bioadhesive Containing ginger officinal extract in the management of recurrent aphthous stomatitis: A randomized clinical *j Intern Med.* 2015;6:3.
39. Chopra P et al. Homeopath AS holistic alternative therapy in periodontal patients. *Int J cont Dent.* 2012;3.
40. Amar Surjushe, Resham Vasani, D G Sable. Aloe vera a short review. *Indian journal of Dermatology.*2008;53(4):163-166.

41. Kunari Subitha T, Ayyanar M, Udayakumar M, Sekar T, Ethnomedicinal plants used by Kani tribals in Pechiparai forests of Southern Western Ghats, Tamilnadu, India. International Research Journal Plant Science.2011;2(12):349-354.

