



COMBINATION OF VARIOUS APPROACHES FOR TREATING JUVENILE SCOLIOSIS: - A CASE STUDY

¹Dr Sayali Sakpal, ¹Dr Akshada Deshmukh, ²Dr Sujit Vasava, ³Dr. Rajiv Limbasiya

¹ Internee, Shrimad Rajchandra college of Physiotherapy, Uka Tarsadia university, ²Assistant Professor, Shrimad Rajchandra college of Physiotherapy, Uka Tarsadia university, Bardoli, ³Principal I/c Associate professor, The saravjanik college of physiotherapy, Veer Narmad South Gujarat university, Surat

Background: Scoliosis is defined as a lateral curvature of the spine that is usually accompanied by rotation. Progression of the curvature during periods of rapid growth may result in significant deformity, which may be accompanied by cardiopulmonary compromise. When the spine develops a lateral curve, it is abnormal. It throws the well-adjusted spinal mechanism out of gear and poses the following problems: - a) A cosmetically unacceptable deformity. b) Deranges the load and force transmission mechanism through the spine. c) Jeopardizes the functions of vital organs like lungs, heart by overcrowding the ribs.

Methods: This is a retrospective case presentation involving a 6-year-old girl scoliosis patient who began an outpatient various physiotherapy exercise program and was monitored monthly for improvement in measurements of cobb's angle and chest expansion and improvement in limb length discrepancy measured. Photos were taken to document body image periodically throughout treatment.

Results: Within one month of beginning of various approaches of treatment the patient reported no more shoulder pain and within 3 months there were significant improvement in strength, limb length discrepancy and improve flexibility of hamstrings and rectus femoris muscles. The patient also benefitted from improved chest expansion, reduced scoliosis curve angles (Pre:26-degree, post-23 degree). She became more active and resumed all functional activity within 3 months of beginning physiotherapy treatment.

Conclusions: The combination of various approaches is effective for improving flexibility, strength, skeletal deviation and Cardiovascular fitness in juvenile idiopathic scoliosis. Future experimental studies should be done to examine the effectiveness of chiropractic care and mechanical traction, given the relative scarcity of research on this topic

Key word: Juvenile idiopathic scoliosis

INTRODUCTION

Scoliosis is defined as a lateral curvature of the spine that is usually accompanied by rotation. Progression of the curvature during periods of rapid growth may result in significant deformity, which may be accompanied by cardiopulmonary compromise.^[1] The most famous example of scoliosis is the “hunchback of Notre Dame.” Scoliosis in the cervical spine is called a torticollis. ^[2] When the spine develops a lateral curve it is abnormal. It throws the well-adjusted spinal mechanism out of gear and poses the following problems:- a) A cosmetically unacceptable deformity. b) Deranges the load and force transmission mechanism through the spine. c) Jeopardizes the functions of vital organs like lungs, heart by overcrowding the ribs..^[3] According to the book Essentials Of Orthopaedic for applied physiotherapy by Jayant Joshi & Prakash Kotwal Scoliosis are divided into three major categories 1)Mild 2)Moderate 3) Severe. It has two main types:- **1. Structural scoliosis:-** In structural scoliosis the curves are fixed and nonflexible and fail to correct with side bending. Lateral bending of the spine is asymmetric or involved vertebrae are fixed in a rotated position or both. Structural scoliosis may occur from a variety of causes. Idiopathic scoliosis accounts for 90 percent of all scoliosis and appears to represent a hereditary disorder but the exact mechanism of its production is unknown. There are two types of scoliosis^[3]: **1. Idiopathic (unknown cause) :-**

IDIOPATHIC SCOLIOSIS

table 1.1:- Types of idiopathic scoliosis ^[4]

Infantile idiopathic scoliosis	Onset during the age of 3 years
Juvenile idiopathic scoliosis	The age of onset is between 3 and 10 years
Adolescent idiopathic scoliosis	The age of onset is between 10 and 20 years
Adult idiopathic scoliosis	The age of onset is over 20 years

Idiopathic scoliosis is the most common variety of structural scoliosis.^[3] Prognosis of scoliosis depends upon the age of onset, time of detection, site of the primary curve and institution of treatment. If the onset is at an early age, the curve tends to increase with age till the end of skeletal growth. The prognosis in such a case is poor, particularly in the thoracic curves. The thoracic curve also interferes with breathing efficiency. ^[4] **2. Known cause:-** The important among these are:- **a. Congenital scoliosis:-** This is due to defect in segmentation which is usually due to a lateral bar or due to a defect in the formation including hemi vertebrae or double hemi vertebrae. These curves usually progress very fast and require surgical fusion on both the convex and concave sides of the curve. **b. Paralytic scoliosis:-** This is due to muscle imbalance on either side of the trunk, the most common cause being anterior poliomyelitis. Cerebral palsy, muscular dystrophies, etc. are the other common causes.^[3]

2 Non-structural scoliosis :- In non-structural scoliosis the curves are flexible and readily correctible with side bending. It is frequently seen as a compensatory mechanism to a leg length discrepancy, fixed flexion deformity of the hip (compensatory scoliosis), local inflammation or irritation due to acute lumbar disk disease and prolapsed disk (sciatic scoliosis) or due to poor postural habits (postural scoliosis). Postural scoliosis is the most common variety of non-structural scoliosis ^[3] Postural scoliosis has no structural (bony) changes in the vertebrae. The causes may be wrong postural habits, shortening of one leg, a disc lesion (sciatic scoliosis) or psychological factors.^[4]

Case Study:

A 6 year old girl Visited a physiotherapy OPD at Sardar Smarak hospital with chief complaint of Severe Shoulder and back pain. There was no history of fall or any injury. Body built of the patient was ectomorph with BMI :- 15(underweight) (weight 15 kg and height 101 cm)

After a clinical assessment and examination Scoliosis Of thoraco-lumbar Spine was diagnosed for right side. After a diagnosis when antenatal history was asked to her mother She told that during Pregnancy mother's nutrition intake was improper & mental health is affected due to personal reasons. She also revealed her history of alcohol consumption from 7 to 9 months of pregnancy. and the baby was delivered by caesarean section due to lack of amniotic fluid . There is No history of delayed cry during delivery. After the birth of the baby girl she was placed in an incubator for five days, as the baby birth weight was only 1.5 kg and was also suffering from neonatal jaundice. Her mother complained about frequent history of illness. The physical examination ruled out further clinical significance . On Postural examination in the frontal plane she also displayed a markedly high right shoulder and right pelvic hike due to abnormal spine curvature. Right side thoracic prominence in the forward bending test.

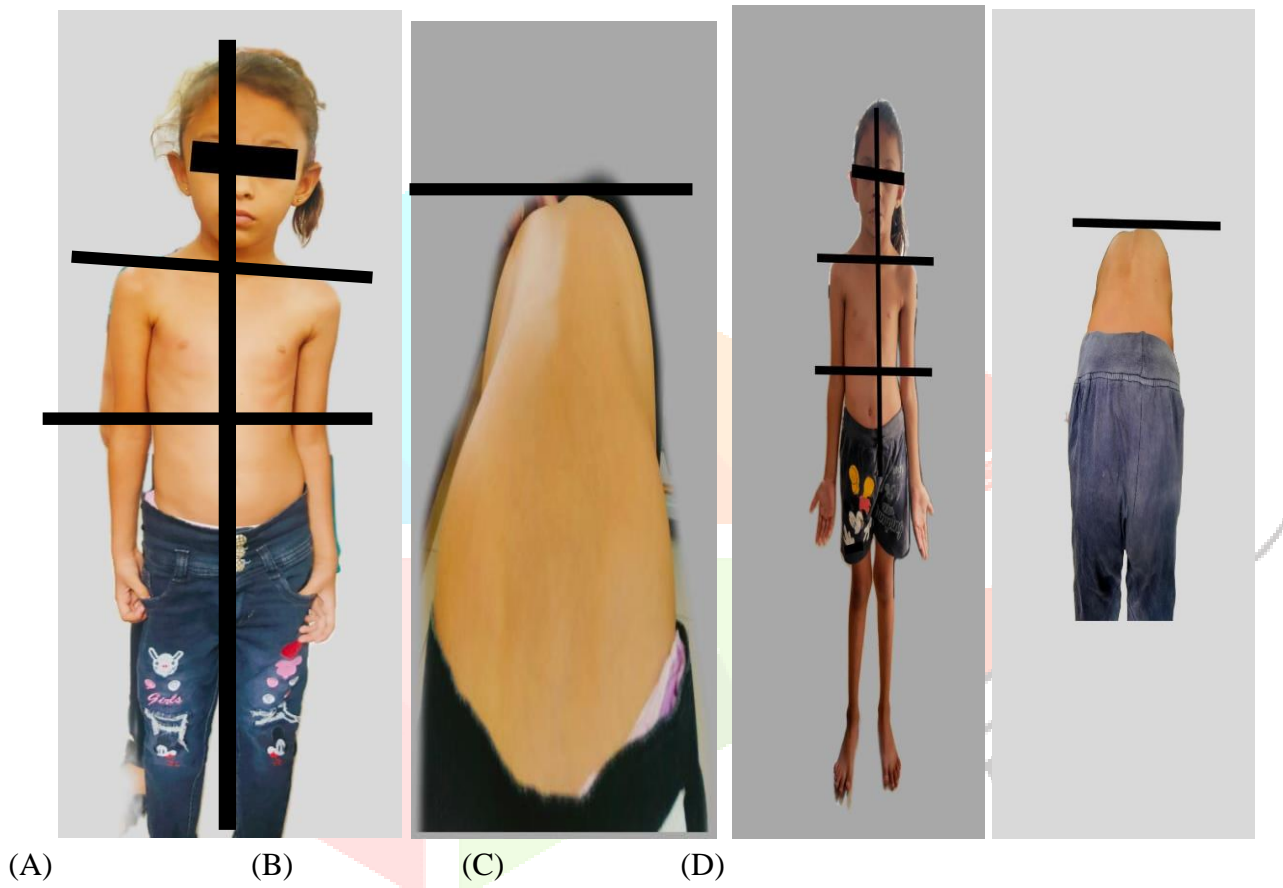
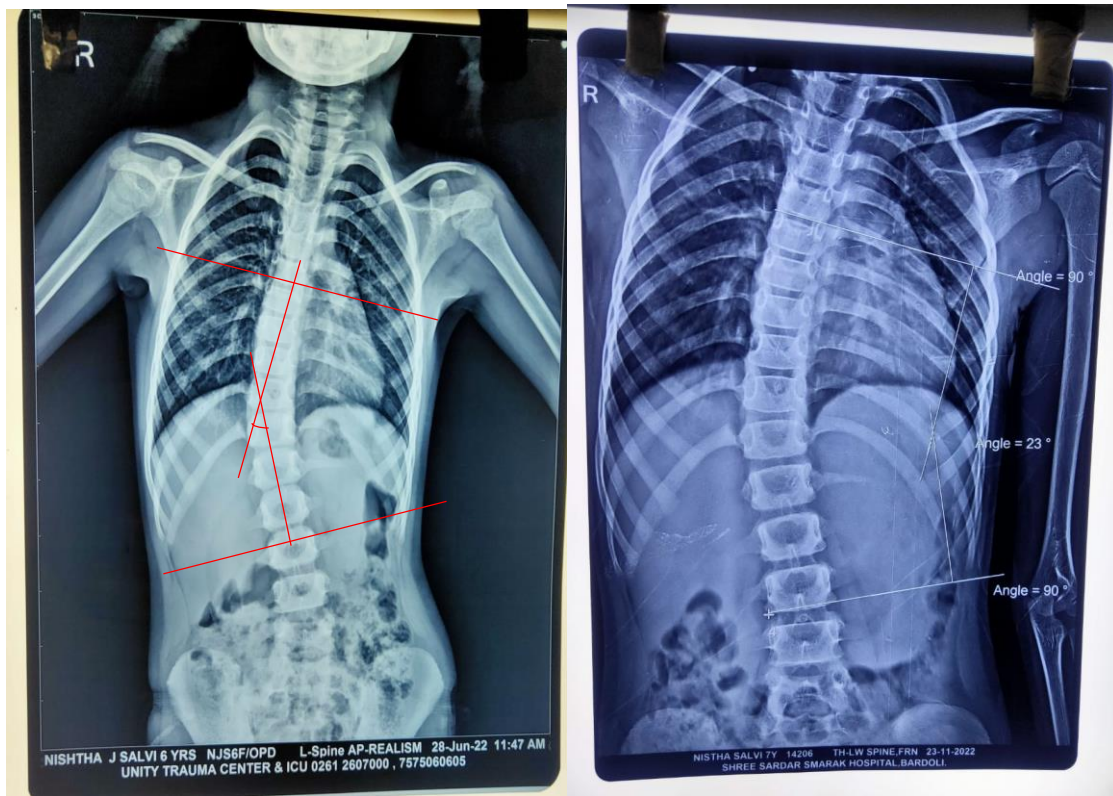


Figure 1(A)- pre frontal plane postural examination (B) pre forward bending test- posterior view (C) post frontal plane postural examination (D) post forward bending test- posterior view



(A)

(B)

Figure 2:- (A) pre cobbs angle (B) post cobbs angle

Cobb's angle measurement done to rule out quantitative Severity Of Scoliosis .The girl falls in the category of Mild scoliosis with 26° Cobb's angle for thoracolumbar scoliosis in an x-ray of 28 June 2022.

Pre and post treatment ROM, Muscle strength and Limb length discrepancy were checked by the Assessor therapist. Based on the pre-treatment examination we were set the protocol. Treatment was given to the patient by the two therapists. The Patient began a treatment course on a daily basis. The treatment protocol is divided into 2 days. Different exercises each day. The goal of treatment included 1) Improvement of Sagittal Spine alignment. 2) Maintenance of correction.

According to previous research and evidence, there is an affection for cardiorespiratory fitness in patients of scoliosis for assessment of cardiorespiratory fitness Step up and step down test was performed and her VO2 Max value was 49.93 and she falls under the average category according to her age. Chest expansion was measured before and after the treatment as shown in table 1.2

table1.2: - chest excursion

Chest Excursion		
	Pre measurement	Post measurement
Apical level	1.5 cm	2.5 cm
Nipple level	02 cm	2.5 cm
Below nipple level	2.2 cm	2.2 cm

table no :- 1.3 :- treatment protocol

DAY : 1	DAY : 2
<p>POSITIONING: Side lying stretch at the edge of the plinth [10 min] Child pose stretch [3 reps with 60 sec holds] Triangle pose [3 reps with 60 sec holds]</p> <p>STRETCHING Hamstring and Calf stretching [3 reps with 60 sec holds] Lion stretch [3 reps with 60 sec holds]</p> <p>STRENGTHENING: Lower limb strengthening with 500gm [10 reps with 10 sec holds] Bridging [10 reps with 10 sec holds] Abdominal tuck in [10 reps with 5 sec holds]</p> <p>SPINAL MOBILITY: Cat and Camel [10 reps with 10 sec holds]</p> <p>MUSCLE ENERGY TECHNIQUE MET for Quadratus Lumborum [3 rep with 30sec hold]</p>	<p>POSITIONING: -Prone lying stretch at edge of the plinth [10 min] -Bolster stretch [3 reps with 60 sec holds] -Cobra pose [3 reps with 60 sec holds]</p> <p>STRETCHING: -Pectoralis Major stretching [3 reps with 60 sec holds]</p> <p>STRENGTHENING: - upper limb strengthening with 100m wt. [10 reps with 10 sec hold] scapular strengthening with 500 gm wt. [10 reps with 10 sec hold] curls up [10 reps with 10 sec hold]</p> <p>SPINAL MOBILITY: crawling on mat [10 reps] trunk rotation [3 reps, 60 sec hold]</p> <p style="text-align: center;">5. MUSCLE ENERGY TECHNIQUE:</p> <p>MET for Quadratus Lumborum [3 rep with 30sec hold] MET for Trapezius [3 rep with 30sec hold]</p>

Results:

table 1.4: - Range of motion

Cervical joint				
	Pre		Post	
Flexion	3 cm		5cm	
Extension	3cm		4cm	
Rt side flexion	1 cm		4cm	
Lt side flexion	3cm		5cm	
Thoraco-Lumbar				
	Pre		Post	
Flexion	2cm		3.5cm	
Extension	2.5cm		3.7 cm	
Rt side bending	22cm		17 cm	
Lt side bending	19 cm		14cm	
Hip joint				
	Rt side		Lt side	
	pre	Post	Pre	Post
Flexion	110 degrees	120 degrees	100 degree	110 degrees
Extension	15degrees	15 degrees	10 degrees	15 degrees
Abduction	40 degrees	50 degrees	35 degrees	45 degrees
Adduction	10 degrees	20 degrees	10 degrees	22 degrees
Internal Rotation	30 degrees	40 degrees	35 degrees	40 degrees
External rotation	40 degrees	50 degrees	40 degrees	50 degrees

table 1.5 :- limb length discrepancy

LLD		Pre difference [Left] cm	Post difference [Left] cm
True LLD	Xiphisternum to umbilicus	0	0
	Umbilicus to ASIS	0.4	0
	ASIS to GT	2.5	1
	GT to Medial joint line	1.5	1
	Medial joint line to medial malleoli	0.5	0.5
Apparent LLD	Xiphisternum to medial malleoli	1	0

table 1.6: - Muscle Strength

Cervical joint				
	Pre		Post	
Flexors	3		4	
Extensor	3		4	
Rt side flexion	3		4	
Lt side flexion	3		4	
Thoraco-Lumbar				
	Pre		Post	
Flexion	3		4	
Extension	3		4	
Rt rotators	3		4	
Lt rotators	3		4	
Hip joint				
	Rt side		Lt side	
	pre	Post	Pre	Post
Flexor	3	4	3	4
Extensor	3	4	3	4
Abductors	3	4	3	4
Adductors	3	4	3	4
Internal Rotators	3	4	3	4
External rotators	3	4	3	4

table 1.7: - Thomas test

Thomas test		
	Pre angle	Post treatment angle
Right side	35 degrees	40 degrees
Left side	20 degrees	30 degrees

table 1.8: - 90-90 SLR Test

90-90 SLR technique		
	Pre angle	Post treatment angle
Right side	30 degrees	20 degrees
Left side	28 degrees	20 degrees

Discussion:

The objective of study was to assess effectiveness of various approaches in juvenile idiopathic scoliosis. The goal of study to reduce the curvature of the spine and improve a strength of surrounding structure was achieved in this case. The patient's scoliosis improvement was observed at post treatment X-ray observation. (Cobb's Angle – 23 degree).

In this study, the juvenile patient's scoliosis improved markedly while under physiotherapy care. ^[1] The result of the study shows mild improvement in curve and marked improvement in strength, limb length discrepancy and improve flexibility of hamstrings and rectus femoris muscles chest expansion increased from 1 cm to 2.5 cm.

Coordinated manual therapies for scoliosis treatment have been increasingly investigated in recent years. Spinal traction, bracing, and rehabilitative procedures seem to alter spinal structure when applied in combination.^[1]

Several methods for estimating spinal elasticity have been used, including traction in combination with the use of a traction force indicator (Miller and Green 1976). The application of pressure to the convex side of the scoliotic curve (Kleinman et al. 1982), and lateral bending (Lonstein and Carlson 1984). Manual traction, such as we performed, is simple and requires no elaborate devices ^[5]

Strengthening and positioning are effective for a surrounding muscle groups and various affected structures.

Conclusion

The combination of various approaches is effective for improving flexibility, strength, skeletal deviation and Cardiovascular fitness in juvenile idiopathic scoliosis. Future experimental studies should be done to examine the effectiveness of chiropractic care and mechanical traction, given the relative scarcity of research on this topic.

References

1. Chen K-C, Chiu EHH. Adolescent idiopathic scoliosis treated by spinal manipulation: a case study. *J Altern Complement Med* [Internet]. 2008;14(6):749–51. Available from: <http://dx.doi.org/10.1089/acm.2008.0054>
2. Magee DJ. *Orthopaedic physical assessment*. 6th ed. London, England: W B Saunders; 2021.
3. Ebnezar J. *Textbook of orthopedics*. New Delhi, India: Jaypee Brothers Medical; 2017.
4. Kotwal PP, Mittal K. *Joshi and kotwal's essentials of orthopedics and applied physiotherapy -E-book*. 4th ed. New Delhi, India: Elsevier; 2020.
5. Panayotis K Soucacos, Panayotis N Soucacos & Alexandros E Beris (1996) Scoliosis elasticity assessed by manual traction:49 juvenile and adolescent idiopathic cases, *Acta Orthopaedica Scandinavica*, 67:2, 169-172, DOI: 10.3109/17453679608994665