



# CORRELATION OF ALDH1 STEM CELL MARKER IN URINARY BLADDER CANCER WITH INVASIVENESS

Dr. Anum Aziz

(MPH Student, Dr. Giri Lal Gupta Institute Of Public Health And Public Affairs,  
University Of Lucknow, Lucknow)

## INTRODUCTION :

Bladder cancer is quite common in India. A very high incidence is seen in some of the European countries. The etiopathology remains unclear, ranging from smoking, chemical carcinogens, parasites to chronic low grade infection of the urinary bladder - cystitis. The prognosis depends upon many factors, most important of which is, whether the cause is invasive or non-invasive. Besides this, some gene polymer films and other tumor markers have been used in determining the prognosis.

Of the several stem cell markers, ALDH-1 is also a stem cell marker which has been found to be associated with the malignancy and prognosis. The other stem cell markers are CD44, CD133, CD24.

The present study had been planned to study the presence of ALDH-1 positive cancer stem cells in urinary bladder cancer.

## AIM :

To study the immunohistochemistry for ALDH-1 stem cell marker in urinary bladder tumors.

## OBJECTIVES :

- To study histopathological grade and stage of bladder cancer.
- To stain for ALDH-1 tumor marker by IHC in above cases
- To correlate the presence of positive ALDH-1 intensity and invasiveness of bladder cancer.

## DETAILED METHODOLOGY :

### Study Design :

- Case only study.
- Sample size - 10 cases

### Inclusion Criteria :

- All the cases of urinary bladder cancer which have not yet received treatment and in whom biopsy is available for histopathology and consent for participation in study.

### Exclusion Criteria :

- Any case associated with a secondary malignancy.
- Any case associated with immunodeficiency such as AIDs etc.

### METHODOLOGY :

- The tissue biopsy sections stained by haematoxylin and eosin were studied for diagnosis and histopathological grading of disease, including invasiveness and non-invasiveness of the tumor into the muscularis.

- Sections from the same block were taken and mounted on poly-l-lysine coated slides for doing immunochemistry.

- Immunohistochemistry was done by primarily ALDH-1 antibody and secondaries both obtained from DAKO-USA.

### IHC STAINING PROCEDURE :

#### PARAFFIN EMBEDDED SECTION-

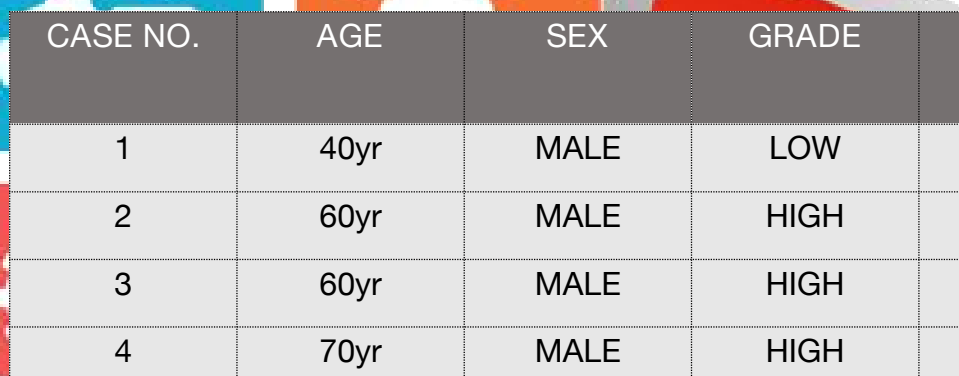
1. Deparaffinisation - 3 changes of xylene.
2. Hydration - Decreasing order of alcohol. Absolute alcohol 90%, alcohol 70% and alcohol 50%.
3. Tap water wash for 5 minutes.
4. Wash three changes of distilled water.
5. Put the slide in retrieval solution in coping jar and put jar in microwave at 90 degrees for three cycles.
6. Wash three changes of Tris buffer.
7. Peroxidase stain - Put the slide in 3% peroxidase solution for 10 minutes.
8. Wash three changes of Tris buffer.
9. Power block - Apply power block reagent on slide and allow to react for 20 minutes. Decant the power block solution and blot the slide surrounding the tissue and primary antibody for one hour.
10. Wash three changes of Tris buffer.
11. Apply secondary antibody for 30 minutes.
12. Wash three changes of Tris buffer.
13. Apply DAB chromogen substance for 10 minutes and control the slide under the microscope. When the desired colour is obtained stop the reaction by putting the slide in distilled water.



14. Wash three changes of distilled water.
15. Counter stain with haemotoxylin stain for 30 seconds.
16. Wash in tap water for 5 minutes.
17. Bluing in Scott Mixture.
18. Dry in air.
19. Mount with DPX mountant.
20. See under microscope whether marker is positive or negative.

### RESULTS AND OBSERVATIONS :

- Immunohistochemistry slides were examined under microscope under microscope for positive staining.
- Intensity of the staining was graded into 1, 2, 3 and 4 grades.
- The following observations were made :



CASE NO.	AGE	SEX	GRADE	ALDH-1 STATUS
1	40yr	MALE	LOW	-
2	60yr	MALE	HIGH	+++
3	60yr	MALE	HIGH	-
4	70yr	MALE	HIGH	+++
5	55yr	MALE	HIGH	+
6	50yr	MALE	LOW	-
7	50yr	MALE	HIGH	++
8	58yr	MALE	HIGH	++
9	35yr	MALE	LOW	-
10	70yr	MALE	LOW	-

Thus it was observed that ALDH-1 positivity was more in cases of high grade urothelial malignancies. On application of statistics, the ALDH-1 positivity in high grade urothelial malignancies is significant with p value = 0.048 (<0.05).

Out of the high grade tumors which were positive, 2 cases showed +++ positivity, 2 cases showed ++ positivity, while 1 case showed + positivity (although this was not statistically significant).

No cases were found with ++++ positivity.

### CONCLUSION :

Our study is in concordance with other previous studies that high grade urothelial malignancies are more positive for ALDH-1 immuno-marker.

Hence, ALDH-1 can be used as a marker during initial diagnosis of urothelial carcinomas to predict their subsequent aggressiveness.

References :

- S. Ricardo, A.F. Vieira, R. Gerhard et al., “Breast Cancer stem cell markers CD44, CD24 and ALDH1 : expression distribution within intrinsic molecular subtype”
- D. Y. Cho, S. Z. Lin, W. K. Yang et al., “ The role of cancer stem cells (CD133+) in malignant gliomas”
- T. Klonisch, E. Wiechec, S. Homabch-Klonisch et al., “ Cancer stem cell markers in common cancers - therapeutic implications”
- J. B. Overdeest, S. Thomas, G. Kristiansen, D. E. Hansel, S. C. Smith and D. Theodorescu, “ CD24 offers a therapeutic target for control of bladder cancer metastasis based on a requirement for lung colonization”

