



Management Of Iris Cyst Two Years After Phacoemulsification: A Case Report

Dr. Akannour Younes 1, Dr. Alakhdari Meryem 2, Pr.louai serghini 3 , Dr, Pr. Elhassan Abdellah 4 , Pr. Amina Berraho 5.

1,2, resident in ophthalmology, 4 and 5 professor in ophthalmology

Department of ophthalmology B; hospital of specialties, Rabat. Morocco

Abstract: Secondary iris cysts are a rare complication after cataract surgery. Reports of iris cysts after conventional phacoemulsification are rare. We report a case of an epithelial inclusion cyst of the iris after cataract surgery, causing elevated intraocular pressure, which was successfully treated with a neodymium-doped yttrium aluminum garnet (Nd YAG) laser. No recurrence was found by slit lamp examination two months after treatment.

Keywords: iris cyst, phacoemulsification, Nd YAG

Introduction

Iris cysts are rare tumors of the anterior segment and can be congenital or acquired. Post-surgical iris cysts are secondary cysts resulting from the inclusion of corneal or conjunctival epithelial cells in the anterior chamber. These benign tumors, representing 20% of all iris masses (1), pose the problem of their local extension and recurrence.

We report a rare patient with peripheral iris cysts and secondary high intraocular pressure.

CASE REPORT

26-year-old patient, 4-year history of cataract surgery in both eyes, by phacoemulsification, who consults ophthalmological urgencies for photophobia with watering and visual loss of the right eye. The ophthalmological examination of the right eye finds: a visual acuity to count the fingers of near. slit lamp examination of the right eye found a temporal iris cyst obtruding the pupillary area (figure 1), intraocular pressure at 28 mmHg, gonioscopy finds an open iridocorneal angle, and the rest of the exam was difficult to visualize.

Ocular ultrasound revealed an echogenic mass in the retrocornea.

The iris cyst was treated by the Yag laser with visual improvement (AV corrected to 4/10 given the amblyopia already installed) and intraocular tension (to 15mmHg). There was no recurrence as determined by slit lamp examination at two months after treatment (figure 2)

Discussion

Iris cysts are divided into pigment epithelial cysts and iris stromal cysts. Iris pigment epithelium cysts are subdivided into central, medial, peripheral and floating cysts [1, 2]. Pigment epithelial cysts tend to develop in the free space of the posterior chamber of the eye, which is rare and causes almost no complications and therefore does not require treatment.

Stromal cysts are usually characterized by a more aggressive course due to their tendency to grow and fill the volume of the anterior chamber, leading to angle closure and the development of glaucoma, the contact of the cyst wall with the posterior corneal surface will lead to endothelial dystrophy [3].

Secondary iris cysts may be secondary to trauma or anterior segment surgery, rarely related to an anterior segment melanocytic tumor. The pathogenesis of secondary cysts is that conjunctival or corneal epithelial cells invade into the anterior chamber following surgical trauma or a penetrating wound (4). Epithelial proliferation after surgical trauma may take the form of serous cyst, pearl cyst or may induce epithelialisation of the anterior chamber (epithelial downgrowth). Serous cysts are the most frequent and tend to develop large tumor diameters and lead to iris atrophy and can invade the posterior chamber through iris erosion. (5).

only 2 cases of iris cyst following CPE have been reported (6-7), other previously described cases were a result of other more invasive intraocular surgery, for example, extra capsular cataract extraction (ECCE), penetrating keratoplasty, radial keratotomy and glaucoma surgery may all predispose a patient to the formation of epithelial inclusion cysts. All these procedures involve conjunctival manipulation and a larger corneal incision compared to phacoemulsification, thus increasing the likelihood of epithelial downgrowth into the anterior chamber.

Treatments for iris cysts include simple observation, fine needle aspiration, laser (including argon or Nd:YAG laser) or surgical excision. Laser therapy has become the current trend because of the minimal invasion. Finally, surgical management is possible if less invasive approaches have failed and consists in the on excision of the cyst, frequently associated to sectorial iridectomy to avoid recurrences.(8)

Conclusion

Post-surgical iris cysts are rare. They are easier to diagnose, but they still pose a therapeutic and prognostic problem.

References

1. Shields CL, Kancherla S, Patel J, et al. Clinical survey of 3680 iris tumors based on patient age at presentation. *Ophthalmology* 2012; 119: 407–14.
2. Shields JA, Shields CL. Cysts of the iris pigment epithelium: What is new and interesting? The 2016 Jose Rizal International Medal Lecture. *Asia Pac J Ophthalmol (Phila)* 2017; 6: 64–9.
3. Shields CL, Arepalli S, Lally EB, et al. Iris stromal cyst management with absolute alcohol-induced sclerosis in 16 patients. *JAMA Ophthalmol* 2014; 132: 703–8
4. Georgalas I, Petrou P, Papaconstantinou D, Brouzas D, Koutsandrea C, Kanakis M. Iris cysts: A comprehensive review on diagnosis and treatment. *Surv Ophthalmol.* 2018;63(3):347–64. doi: 10.1016/j.survophthal.2017.08.009.
5. Behrouzi Z, Khodadoust A. Epithelial iris cyst treatment with intracystic ethanol irrigation. *Ophthalmology* 2003; 110: 1601–1605.
6. . Kuganasan S, Voon Loo A, Subrayan V. A rare occurrence of epithelial inclusion iris cyst after phacoemulsification. *Clin Exp Optom.* 2015;98(1):97–8.
7. Shah A, Rajesh PS, Dutta Majumder P. Iris cyst following cataract surgery. *Clin Exp Optom.* 2019.

- 8. S.S. Shanbhag, M. Ramappa, S. Chaurasia, S.I. Murthy Surgical management of acquired implantation iris cysts: indications, surgical challenges and outcomes.Br J Ophthalmol, 103 (8) (2019), pp. 1179-1183

Figures

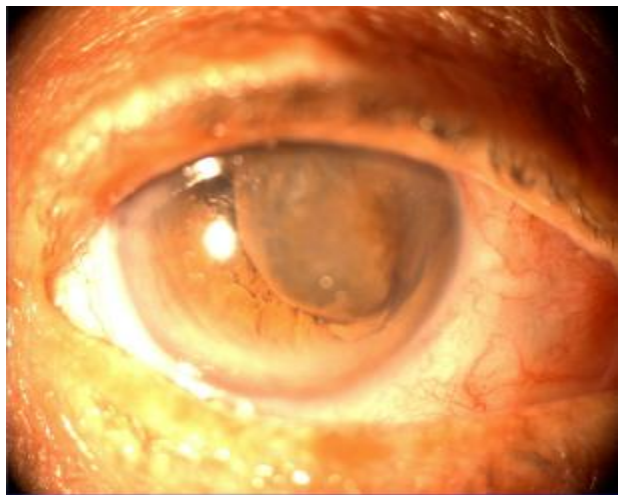


Figure 1 : temporal iris cyst

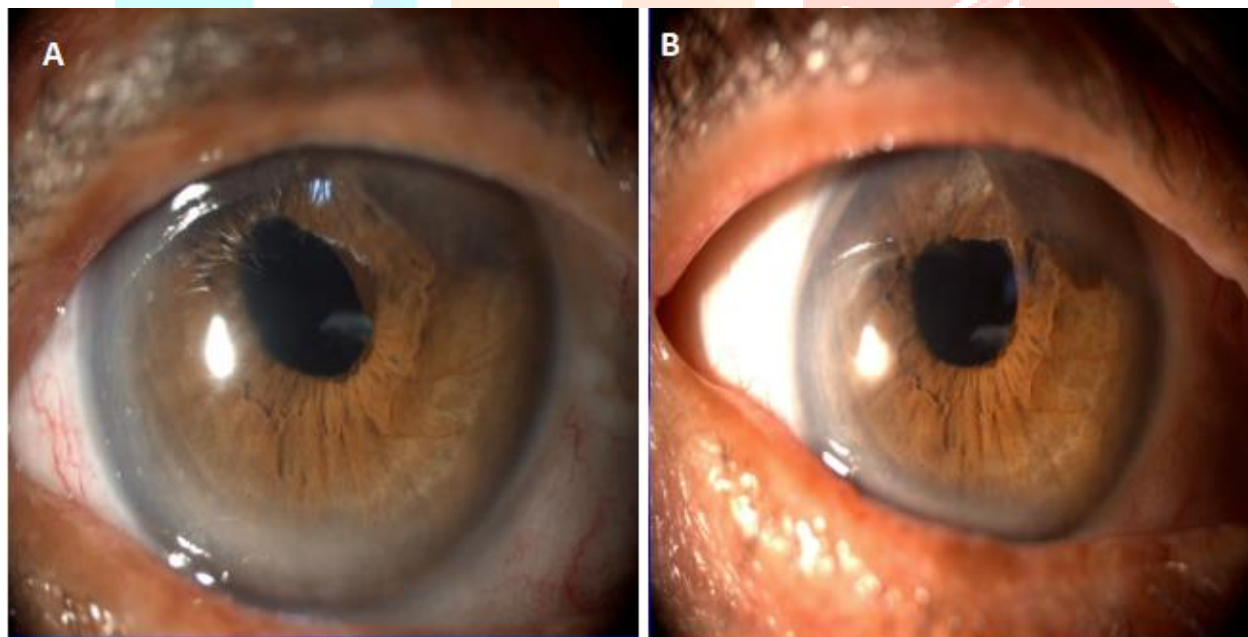


Figure 2 : A: one week after YAG treatment, B: two months after laser