



# METAL TRACHEOSTOMY TUBE AS AN ENDOBRONCHIAL FOREIGN BODY: A RARE CASE REPORT.

Dr. Harsha Deshpande<sup>1</sup>, Dr. Shivaji Sonone<sup>1</sup>, Dr. Abhinay Harankhedkar<sup>1</sup>, Dr. Vikrant Vaze<sup>2</sup>

(3rd yr resident)

(3rd yr resident)

(HOD and Professor)

(Assistant professor)

1 Department of Anaesthesia,

2. Department of Otorhinolaryngology.

Dr. Ulhas Patil Medical college and hospital, Jalgaon, Maharashtra

**ABSTRACT:** Foreign body inhalation and aspiration is less common in adolescent and adult population. However irrespective of the age group, this condition must be identified promptly with high degree of suspicion and treated immediately. Any delay in treatment may lead to serious complications and may cause a life threatening event. The symptoms may show choking but usually mimic those of bronchial asthma or exacerbation of chronic obstructive pulmonary disease. Appropriate assessment should be with chest radiograph, CT scan to estimate the size and location of foreign body. Definitive diagnosis remains to be bronchoscope which can also help on the treatment. Here we have a rare case of broken piece of metal tracheostomy tube acting a foreign body in right main bronchus.

**Keywords:** Foreign body (FB), tracheostomy tube, rigid bronchoscope, right bronchus.

## INTRODUCTION

Aspiration of foreign body is a less common incident seen in adolescent and adult population. The diagnosis in adults might prove to be practically difficult as the symptoms of foreign body aspiration if has happened unknowingly, mimic other respiratory conditions like exacerbation of bronchial asthma, chronic obstructive pulmonary disease or pneumonia. Patients present with symptoms like acute on chronic cough which is the most common presentation. Clinical presentation depends on the site of the foreign body impaction. When there is a large foreign body which is occluding the larynx, patient presents with symptoms like acute severe coughing, choking, continuous stimulation of gag reflex and hoarseness of voice. Sometimes patient may present to the emergency department with gasping and cyanosis. With adult foreign body aspiration being an uncommon incident, a standard approach algorithm is not well documented. Diagnosis is primarily done using chest radiograph which may confirm the presence of foreign body. Foreign body maybe removed with flexible or rigid endoscopy. We hereby present a case of a 16 year old with a part of metallic tracheostomy tube acting as a foreign body who presented with choking, gasping and respiratory distress.

## CASE REPORT

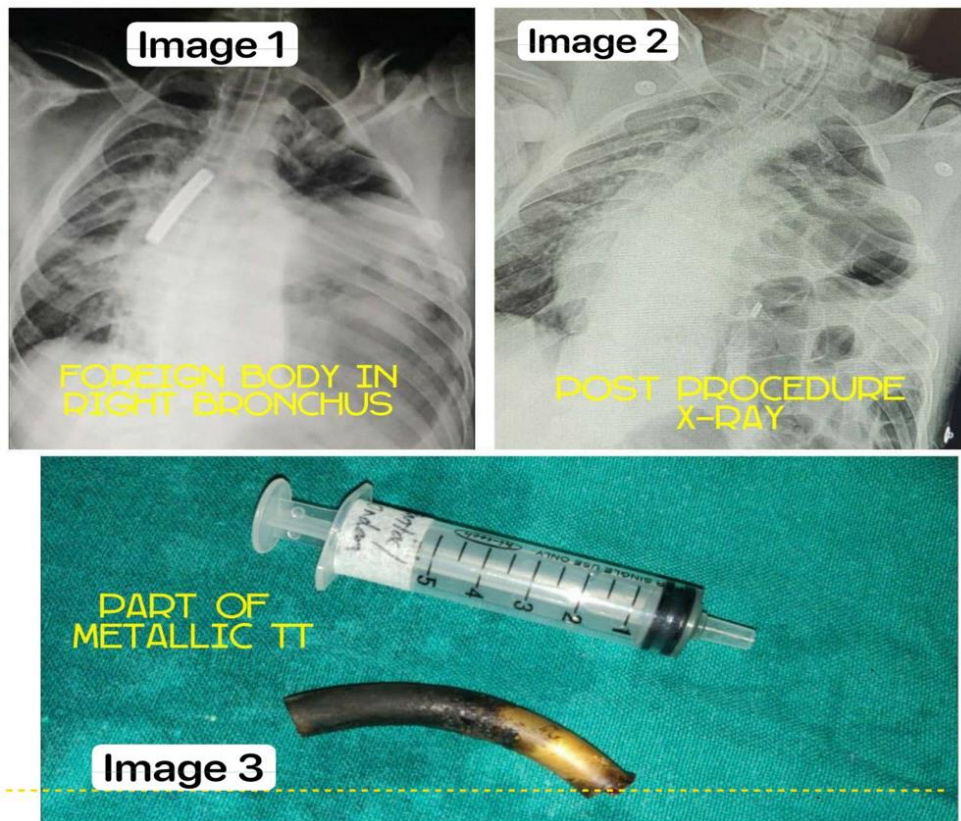
A 16 year male presented with gasping, continuous coughing and hemoptysis to emergency room with expulsion of secretions, blood stained sputum from the tracheostomy site where stoma was intact however tracheostomy tube was not in situ. Patient had a saturation of 89% on room air, heart rate 126 bpm, blood pressure of 140/100 mmhg and he was paraplegic with bilateral upper extremity weakness. On auscultation, decreased air entry was present in right base whereas air entry was normal on the left side.

After enquiry with relatives, patient was known case of Guillian Barre Syndrome since 3 years who had undergone tracheostomy 6 months after diagnosis and feeding gastrostomy later on in due course. Patient was discharged from a medical facility 2 and half years back with metallic tracheostomy tube in situ and was asked to go for routine follow ups.

In emergency room, oral suction and stoma suction was done using appropriate size foley's catheter. Oxygen was assisted via oxygen tubing at 6 litres / min over the stoma site. 16 G wide bore cannula was secured. Nebulization was given with deriphylline, budesonide respules and with mucolytic like inj. N-acetylcysteine. Inj. Dexamethasone 8mg stat was given intravenously and Inj.aminophylline in 100 ml normal saline slow infusion was started. After 15 - 20 minutes of adequate oxygenation patient was maintaining saturation of 95% on Oxygen and heart rate went down to 110 bpm however respiratory rate remained at 30 cycles per minute and signs of distress prevailed. Once the patient was stable hemodynamically, chest radiograph was taken which showed a large foreign body stuck in right main stem bronchus. (Image 1) Patient was immediately shifted for emergency removal of foreign body with rigid bronchoscope.

After shifting the patient to the operating room, patient was adequately oxygenated through stoma site. After all resuscitation equipment, difficult airway cart and tracheostomy tube no. 5.5 and 6 were kept ready, procedure was started. Inj. Propofol 2 mg/kg and Inj. Succinylcholine 2mg/ kg was given. Endotracheal tube number 5.5 was inserted through stoma site and ventilation was achieved. As the bronchoscope passed the laryngeal opening, entered trachea and reached the stoma site, endotracheal tube was withdrawn slowly and patient was thereafter ventilated with jet ventilation via bronchoscope. Intermittent succinylcholine was used to maintain relaxation and Inj. Propofol was used to maintain deeper plane of anaesthesia. As the large foreign body was visualized and extracted carefully, tracheostomy tube was inserted immediately, stylet removed and patient was ventilated via tracheostomy tube.

The large foreign body which was removed was rusted metallic part of the tracheostomy tube.(Image 2) The tube was presumed to be broken from the flanges due to rusting and the outer part of the metallic tube went missing. After ventilating the patient adequately, air entry improved slowly over the right side. Patient started breathing spontaneously as the effect of succinylcholine subsided and was shifted to post Anaesthesia care unit for further observation. Post procedure chest radiograph was done. (Image 3)



## DISCUSSION

Tracheobronchial foreign bodies in adult are rare but they may be life threatening. Majority foreign bodies rest in right main bronchus as it is more in line with the trachea. A large variety of foreign bodies are encountered in bronchus some of which are metallic, pointed and sharp and if not removed immediately, may lead to the death of the patient. The prognosis, morbidity or mortality depend on the time taken for presenting to a medical facility, type of foreign body and skill set of the specialist doing the procedure. Rapid assessment followed by immediate and calculated intervention by a skilled specialist who is experienced in bronchoscopy and a skilled anaesthesiologist usually results in a favourable outcome.

Metallic tracheostomy tubes were used very frequently previously for patients who required long term tracheostomy without ventilation and were sent home. They were easy to access and clean at home setups. However certain drawbacks of metallic tracheostomy tubes were encountered like rusting and accidental breaking as mentioned in our case. Thus frequent replacement of metal tracheostomy tube or usage of newer available use is preferable in order to avoid serious mishaps. This case was unique in every aspect as a large piece of tracheostomy tube was rusted and broken. It was a challenge in both aspects, surgically and anaesthesia wise.

## REFERENCES

1. Gupta IP, Sood VP. Foreign body in the air passages. *Indian J Otolaryngol.* 1967;19:173–174.
2. Brooks JW. Foreign bodies in the air and food passage. *Ann Surg.* 1972;175:720–732.
3. Al-Naaman YD, Al-Ani MS, Al-Ani HR. Non-vegetative foreign bodies in the bronchopulmonary tract in children. *J Laryngol Otol.* 1975;89:289–297.
4. Panda G. Iron nails in the tracheobronchial tree. *Indian J Otolaryngol.* 1976;28:192–193.
5. Narayanan RK, Sharma PS. Foreign bodies in the tracheobronchial tree. *Indian Paediatr.* 1977;14:133–134.
6. Donald C. Zavala, Mitchell L. Rhodes, Robert H. Richardson, George N. Bedell,

7. Fiberoptic and Rigid Bronchoscopy: The State of the Art, Chest, Volume 65, Issue 6, 1974, Pages 605-606,
8. Tyler Paradis, Michael Wollenberg, Brandon Tieu, "Extraction of a Large Central Airway Foreign Body Using Flexible Bronchoscopy Combined with an Endobronchial Blocker", Case Reports in Surgery, vol. 2016, Article ID 3179184, 4 pages, 2016. <https://doi.org/10.1155/2016/3179184>
9. R. Goyal, S. Nayar, P. Gogia, and M. Garg, "Extraction of tracheobronchial foreign bodies in children and adults with rigid and flexible bronchoscopy," Journal of Bronchology and Interventional Pulmonology, vol. 19, no. 1, pp. 35–43, 2012.
10. M. Boyd, A. Chatterjee, C. Chiles, and R. Chin Jr., "Tracheobronchial foreign body aspiration in adults," Southern Medical Journal, vol. 102, no. 2, pp. 171–174, 2009.

