



Valsalva retinopathy in the second trimester of pregnancy : a case report

Dr. Akannour Younes 1, Dr. Alakhdari Meryem 2, Dr. Mrad Khalil 3 , Dr, Pr. Elhassan Abdellah 4 , Pr. Amina Berraho 5.

1,2,3 resident in ophthalmology, 4 and 5 professor in ophthalmology

Department of ophthalmology B; hospital of specialties, Rabat. Morocco

Abstract: Pregnancy induces multiple hormonal, metabolic, hematological and immunological alterations in the mother that represent risk factors for Valsalva retinopathy. we report a case of a 26-year-old woman in her second month of pregnancy, who presented several degreased of her left eye vision immediately after violent vomiting, fundus examination revealed a pre-retinal hemorrhage located in the macula. Based on clinical findings, the diagnosis of Valsalva retinopathy was made.

Keywords: Valsalva maneuver, Valsalva retinopathy, Hyaloidotomy, Pregnancy .

Introduction

Valsalva retinopathy is due to preretinal hemorrhage, caused by a rapid increase in intraocular venous pressure. It often occurs in healthy young adults in various clinical contexts: intense aerobic exercise, defecation effort, vomiting and in many other circumstances, pregnancy is known as a risk factor for this condition [1][2]. Therapeutic abstention and monitoring are recommended initially because its evolution is often spontaneously favorable, We report a case of Valsalva retinopathy in a woman in her second month of pregnancy.

Clinical case

we report a case of a 26-year-old woman in her second month of pregnancy, presented to the Emergency Department of ophthalmology with a sudden decreased visual acuity in the left eye immediately after violent vomiting, she had no particular medical history, Ophthalmologic examination noted the best visual acuity was counting fingers in the left eye and 10/10 in the right eye. Intraocular pressure was 14 mmHg on the Goldmann applanation tonometer in the two eyes. The anterior segment in slit lamp examination was normal.

After dilatation, the fundus examination demonstrated a large subinternal limiting membrane haemorrhage located in the macula of the left eye, associated with areas of intraretinal haemorrhage, vessels (Figure 1). The right eye examination was unremarkable. The OCT clearly shows the hyaloid bulging in front of the retina, detached in the lower part by the very hyperreflective hemorrhage. The biological check-up was normal. (figure 2)

The diagnosis of Valsalva retinopathy is retained. No treatment was proposed to the patient.

At 3 months postpartum, the patient recovered a visual acuity of 10/10 with complete resolution of the retrohyaloid hemorrhage (figure 3)

Discussion :

Valsalva retinopathy was first described by Duane in Philadelphia in 1972 [1].

The pathophysiological mechanism of retrohyaloid hemorrhages secondary to the Valsalva maneuver is known: there are physiological adhesions of the vitreous to the retinal vessels. Thoracic hyperpressure due to blockage during inspiration has an impact on the cephalic and therefore retinal venous circulation. Under the effect of retinal venous hyperpressure, the adhesions pull the vessel which ruptures in the vitreous cavity or in the retrohyaloid space. It is therefore the vitreous traction on a vein, which leads to its rupture and blood flooding [2].

The origin of retrohyaloid hemorrhage, can occur in very different ways: during voluntary efforts of vomiting, during pushing efforts prior to delivery, or during intense sexual activity [3]. During pregnancy, there is already an increase in intra-abdominal pressure. With the efforts of vomiting and coughing, the cephalic hyperpressure becomes considerable to cause rupture of the superficial retinal capillaries [4]. Pregnancy is known to be a risk factor for this condition. The prognosis is generally good with spontaneous recovery in the vast majority of cases [4][5]. The timing of spontaneous recovery is highly variable. The use of the YAG laser can be proposed in some cases to disperse the preretinal hemorrhages in the vitreous and thus allow a faster recovery [6].

Conclusion

Pregnancy is a known risk factor for Valsalva retinopathy, however, the diagnosis should be made only after other causes of retinal hemorrhage have been excluded.

References

1. Duane, T.D. (1972) Valsalva Hemorrhagic Retinopathy. Transactions of the American Ophthalmological Society, 70, 298-313.
2. Guigon-Souquet, B., Salaun, L., Macarez, R., Bazin, S., De La Manierre, E. and Mazdou, M. (2004) Hemorragie rétrohyaloïdienne secondaire à une manoeuvre de Valsalva. Journal Français d'Ophtalmologie, 27, 1159-1162.
3. El-Khayat, A.R. (2017) Valsalva Haemorrhagic Retinopathy in Pregnancy after Yoga. BMJ Case Reports, 11.
4. Nghiem-Buffer, S. and Guiberteau, B. (2009) Rétinopathie de Valsalva et grossesse. Images en Ophtalmologie, 3, 86-87.
5. García-Fernández, M., Castro-Navarro, J. and Gonzalez-Castano, C. (2012) Long-Term Evolution of Valsalva Retinopathy: A Case Series. Journal of Medical Case Reports, 6, 346.
6. Matonti, F., Donadiou, V., Hoffart, L., Dornadin, A., Nadeau, S., Roux, S. and Denis, D. (2013) Traitement précoce par laser Nd:YAG de la rétinopathie de Valsalva: Résultats à propos de cinq cas et revue de la littérature. Journal Français d'Ophtalmologie, 36, 604-609.

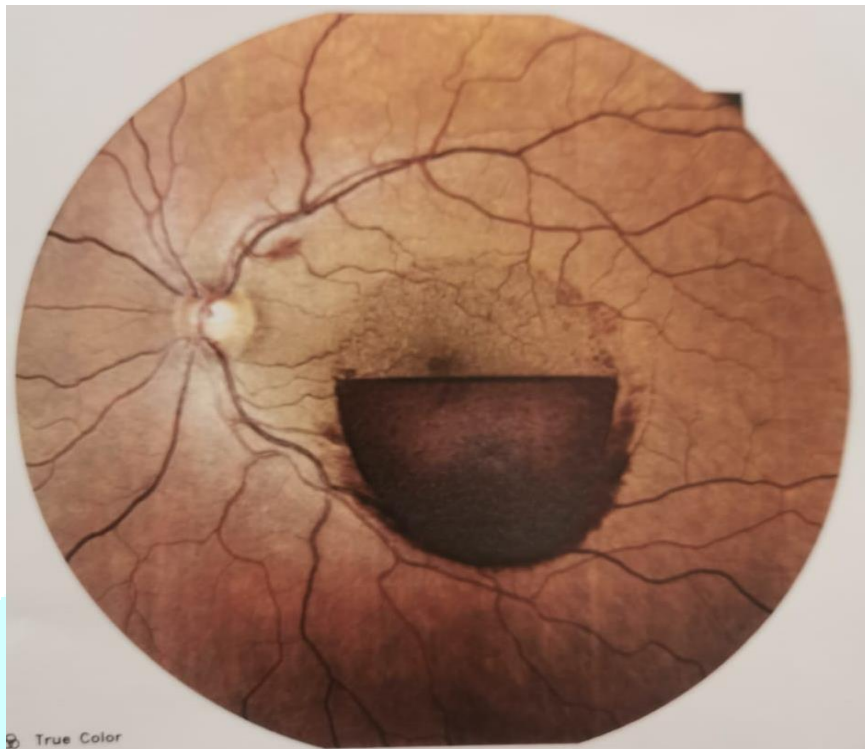
Figures :

Figure 1: Fundus image showing a retrohyaloid hemorrhage masking the macula

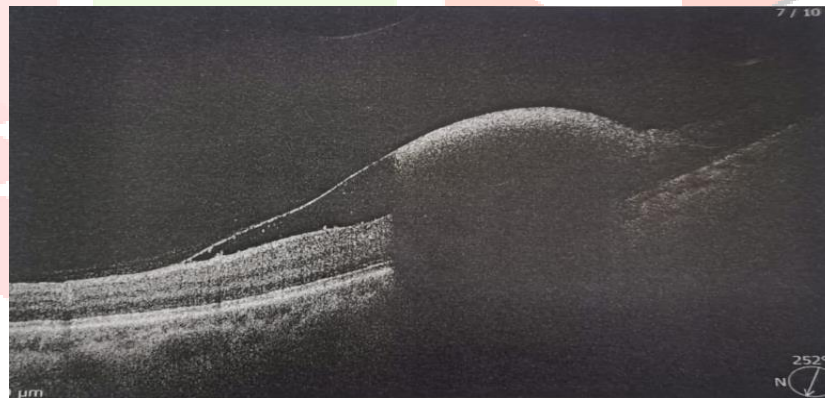


Figure 2 The OCT demonstrated the hyaloid bulging in front of the retina, detached in the lower part by the very hyperreflective hemorrhage

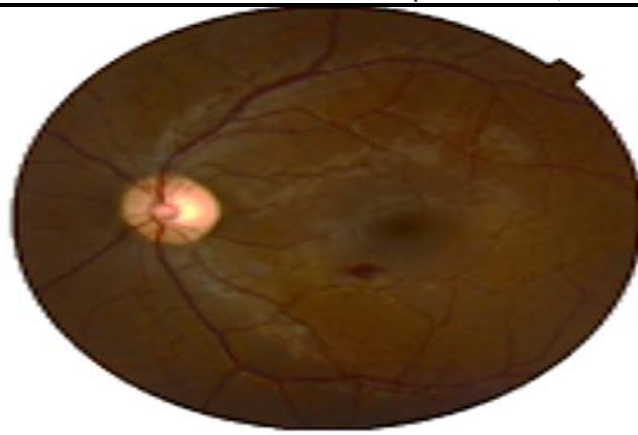


Figure 3: Resolution of the retrohyaloid hemorrhage, but persistence of a small macular hemorrhage.

