



## Lumpy skin disease: An Overview

Ms. Ashwini B. Bodkhe<sup>1</sup>, Ms. Bhagyashree A. Mokle<sup>2</sup>,

Dr. Gajanan Sanap<sup>3</sup>

Student, Department of Pharmacy<sup>1</sup>,

Assistant professor, Department of pharmaceutical chemistry<sup>2</sup>

Principal, Department of Pharmacy<sup>3</sup>

Late Bhagirathi Yashwantrao Pathrikar College of Pharmacy, Pathri, Aurangabad, Maharashtra, India-431111

### Abstract:-

Lumpy skin disease is an emerging bovine viral disease, that is endemic in most African countries and some Middle East ones, and the probability of the disease spreading into the rest of Asia and Europe should be considered. The virus causing Lumpy skin disease (LSD) is called as Lumpy skin disease virus (LSDV), belonging to the Capripoxvirus genus of Poxviridae family. The systemic illnesses caused by sheep pox and goat pox viruses frequently result in substantial morbidity and high mortality in sheep and goats. Brucellosis is a zoonotic bacterial disease resulting in recurring febrile illness in humans, as well as reproductive failure and diminished milk production in livestock. In Albania, human, cattle and ruminants infected by *Brucella abortus* and *B. melitensis*. This is largely caused by the economic impact of the Covid-19 epidemic and the imposition of crippling sanctions in endemic regions, as well as an increase in trade of live animals and animal products both are legally and illegally, as well as effect on global climate change. The goal of current review is designed to provide current information on the various aspects of the disease including its clinicopathology, transmission, epidemiology, diagnosis, prevention and control strategies, and the potential role of animal in the further spread of disease.

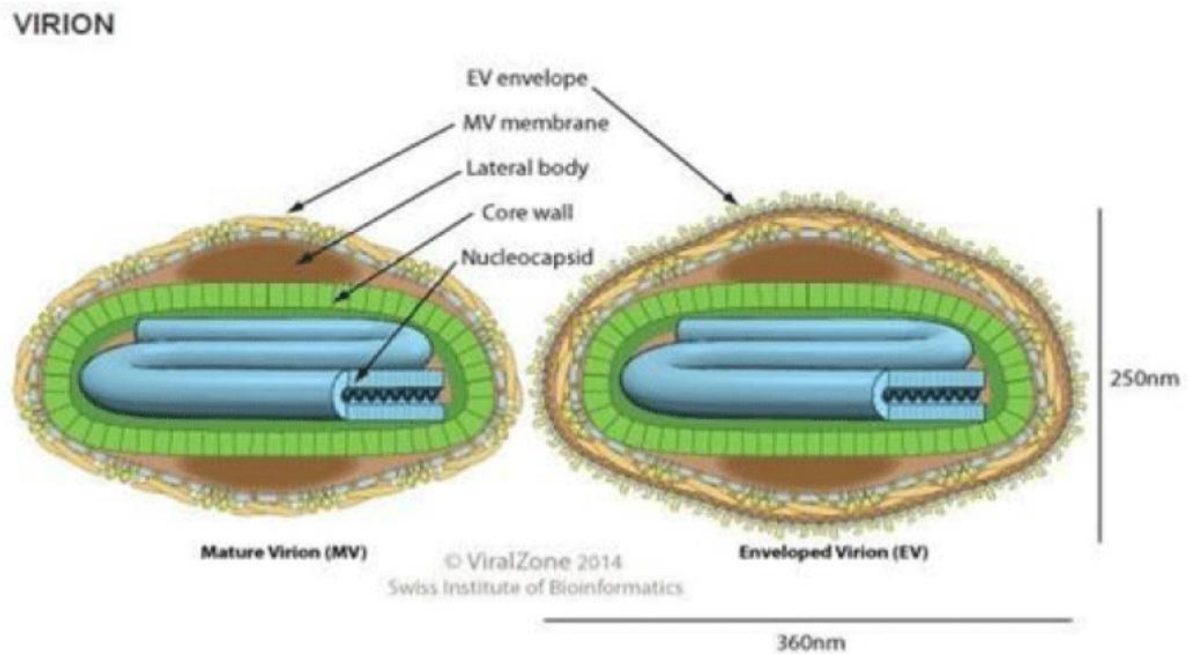
**Keywords:-** Lumpy skin disease, Capripoxvirus, LSD virus, Insect vector, Transmission, Epidemiology.

### Introduction:-

Lumpy skin disease is an infectious viral disease caused by Lumpy skin disease virus (LSDV) of Capripoxvirus genus, Subfamily Chordopoxvirinae, family Poxviridae. The disease is known by various names such as "LSD", "Pseudo-urticaria", "Neethling virus disease", "exanthema nodularis bovis", and "knopvelsiekte"<sup>1</sup>. A transboundary, systemic, viral illness of cattle is lumpy skin disease (LSD)<sup>2</sup>. A lump like nodules in the external skin and mucous membrane with fever and swollen lymph nodes are the preliminary noticeable clinical signs of this devastating disease<sup>3</sup>. Considering the disease burden, morbidity and mortality cattle are found as more sensitive to the illness compared to buffalos and other ruminants<sup>4</sup>. Lumpy skin disease virus (LSDV) is a double-stranded DNA containing around 150 kilobase pairs (kbp) with relatively large sizes (230–260 nm), enclosed in a lipid envelope and belongs to genus Capripoxvirus, which is genetically related to the sheep pox (SPPV) and goat pox (GTPV) viruses<sup>5</sup>. Lumpy skin disease (LSD) is an old viral illness that causes significant economic losses due to chronic debility in infected animals, decreased milk production, poor development, infertility, miscarriage, and occasionally death. Moreover, severe and permanent damage can occur to hides, decreasing their commercial

value<sup>6</sup>. The recent spread of the disease in disease-free countries indicates the importance of its transmission, as well as control and eradication<sup>7</sup>.

## Etiology:-



**Figure 1.** Structure of Lumpy skin disease virus (LSDV). Capripoxvirus.

Lumpy skin disease virus (LSDV) belongs to the family poxviridae, subfamily Chordopoxviridae, and genus Capripoxvirus. This group of virus included the goat pox virus (GTPV), sheep pox virus (SPPV), and lumpy skin disease virus (LSDV). GTPV infects goats, sheep are infected by SPPV, and LSDV infects cattle and buffalo<sup>8</sup>. CPV are cross-reactive within the genus; therefore SPV- or GPV-based vaccines have been used to provide cross protection against LSDV<sup>9-10</sup>.

LSDV is a  $320 \times 260$  nm brick-shaped enveloped virus that replicates in the host cell's cytoplasm and has double-stranded DNA with complicated symmetry<sup>11</sup>. LSDV shows susceptibility to 20% chloroform, 1% formalin, ether, 2% phenol, 2–3% sodium hypochlorite, 0.5% quaternary ammonium compounds, iodine compounds dilution and the detergents containing lipid solvent<sup>37</sup>.

## Risk factor:-

The risk factors for the severity of LSD are identified in 3 basic categories:-

1. Host associated factors
2. Agent related factors
3. Environment and management factors

### **1.Host associated factors:-**

LSD is a host-specific disease affecting severely the cattle and Asian water buffalos (*Bubalus bubalis*)<sup>12</sup>. Buffalo have a substantially lower morbidity rate than cattle<sup>13</sup>. Regardless their age, virus can infect the cattle of both sexes. The degree of disease severity is determined by the hosts' susceptibility and immunological condition<sup>14</sup>.

### **2.Agent related factors:-**

LSDV is remarkably stable under varying environmental conditions. It can persist in desiccated scabs, is resistant to drying and inactivation, and can even sustain freezing and thawing<sup>15</sup>. According to reports, the virus can also be found in saliva, blood, milk, and semen as well as the nasal, lachrymal, and pharyngeal secretions of sick animals. During about 8.8 days, the virus was isolated from the contagious cattle blood<sup>16</sup>.

### **3.Environment and management factors:-**

When given a favourable environment, LSDV can infect, survive, and grow within a susceptible host. Environmental risk factors include warm, humid weather that encourages a bigger population of ticks, flies, and mosquitoes<sup>13</sup>. By transmitting vectors, common grazing and watering areas may promote viral circulation<sup>14</sup>.

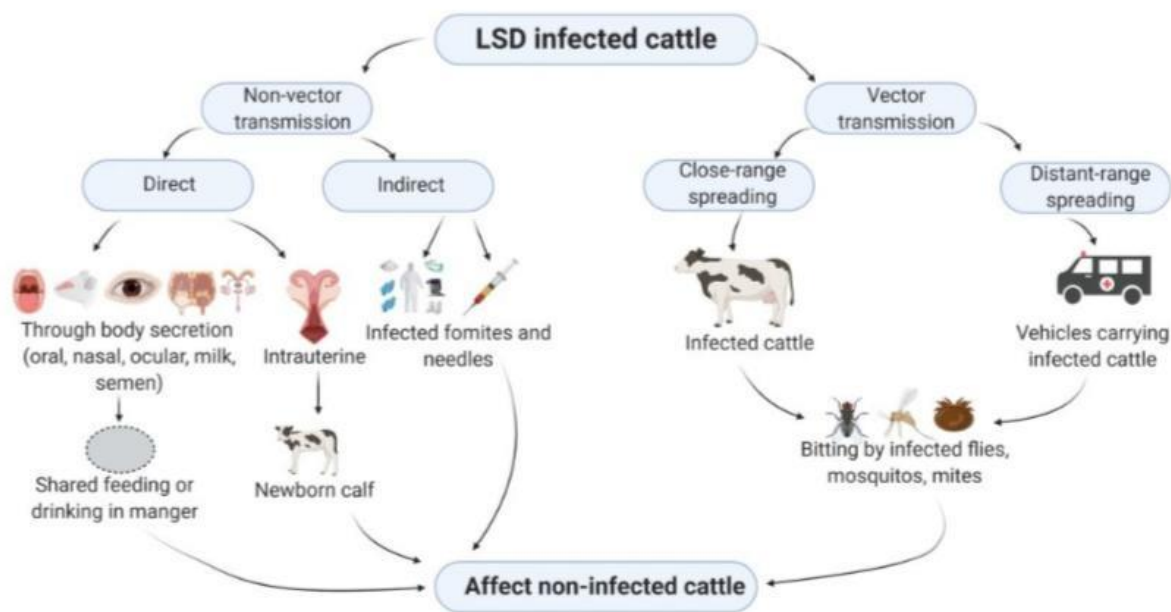
### **Epidemiology:-**

The disease's origin In India and the reason for the 2022 epidemic were also mysteries. In the three months from July to September 23, 2022, the lumpy skin disease epidemic in India caused the deaths of 97,000 cattle<sup>17</sup>. Most livestock deaths occur in five states: Rajasthan, Punjab, Gujarat, Himachal Pradesh, and Haryana<sup>18</sup>.

Midway through September 2022<sup>19</sup>, other states like Madhya Pradesh recorded their first death. In Maharashtra, 1436 people have died<sup>20</sup>. Over 65% of the 18,50,000 cases that were present on September 21 were from Rajasthan<sup>21</sup>. Rajasthan reported almost 50,000 fatalities<sup>22</sup>. UP has recorded at least 378 fatalities<sup>23</sup>. India had 192.5 million cattle as per the most recent livestock census<sup>24</sup>.

### **Transmission of LSDV:-**

The method of of LSDV transmission is useful in Evaluating the epidemiology of the virus, thus contribute towards progressive control strategy and Extinction of the disease<sup>25,26</sup>. Modes of transmission of LSDV is shown in Figure 2.



**Figure 2.** Epitome of possible modes of transmission of LSDV. LSD infected cattle may affect non-infected cattle through vector or non-vector transmission.

### 1. Non-vector transmission

Non-vectored LSD transmission occurs when clinically ill animals come into contact with contaminated items without the use of biological or mechanical vectors, however it is ineffectual. Saliva, nasal, and ocular secretions include infectious LSDV that can contaminate shared eating and drinking places and spread the illness<sup>12,27,28</sup>. Vaccination-related transmission through contaminated needles, coitus-related transmission through infected semen, milk consumption, and intrauterine transmission are all potential causes of infection<sup>27,29,30</sup>.

### 2. Vector transmission

The role of arthropod vectors in the transmission of this virus was experimentally confirmed<sup>31,32</sup>. Several blood-sucking hard ticks, for instance, *Rhipicephalus appendiculatus* (brown ear tick), *Rhipicephalus decoloratus* (blue tick), and *Amblyomma hebraeum*, mosquito *Aedes aegypti* and flies *Stomoxys calcitrans*, *Haematobia irritans* and *Musca domestica* have been implicated in the spreading of LSDV in sub-Saharan Africa<sup>26,30</sup>. In the tick host, LSDV is trans-stadially<sup>31,32</sup> and transovarially transmitted during cold temperatures<sup>33,34</sup>. The virus may spread in short distances of a few kilometers<sup>35</sup> and even cover longer-distance due to unrestricted animal movements across international borders<sup>14,36</sup>.

In experimental studies, the role of arthropod vectors in the spread of this virus was confirmed<sup>31,32</sup>. *Aedes aegypti*, *Amblyomma hebraeum*, and the blood-sucking hard ticks *Rhipicephalus appendiculatus* (brown ear tick), *Rhipicephalus decoloratus* (blue tick), *Stomoxys calcitrans*, *Haematobia irritans*, and *Musca domestica* have all been linked to the transmission of LSDV in sub-Saharan Africa<sup>26,30</sup>.

LSDV is transmitted trans-stadially<sup>31,32</sup> and transovarially during cold temperatures in the tick host<sup>33,34</sup>. Due to unfettered animal migration across international borders<sup>14,36</sup>, the virus may spread over small distances of a few kilometres<sup>35</sup> or even larger distances.

## Pathogenesis:-

During LSDV infection, nodules grow, the virus localises to the skin, viremia, fever, and virus replication all take place<sup>38</sup>. According to experimental results, the following things happened after intradermal inoculation of the virus:

- 4–7 days after infection (DPI) : nodules or plaques of 1-3 cm in diameter appear at the injection site
- Between 6 to 18 DPI: viremia and oral and nasal viral shedding
- 7 to 19 DPI: regional lymphadenopathy and development of generalised skin nodules.
- 42 days after fever: presence of virus in semen<sup>39</sup>

Vasculitis and lymphangitis are caused by intracellular virus replication in fibroblasts, macrophages, pericytes, and endothelial cells in the affected tissue<sup>39</sup>. Subcutaneous tissues and muscular fascia may include nodules<sup>36</sup>. The epidermis, dermis, and core musculature's surrounding tissue exhibits haemorrhages, congestion, and edoema with enlarged lymph nodes<sup>13</sup>. In diverse sections of the body, a unique structure known as "sit-fasts" (necrotic cores detached from the neighbouring skin)<sup>42</sup> is frequently observed, which may lead to ulceration<sup>43</sup>. Young calves, breastfeeding cows, and underweight animals appear to be more vulnerable to spontaneous infections, likely as a result of humoral immunity being compromised<sup>40</sup>.

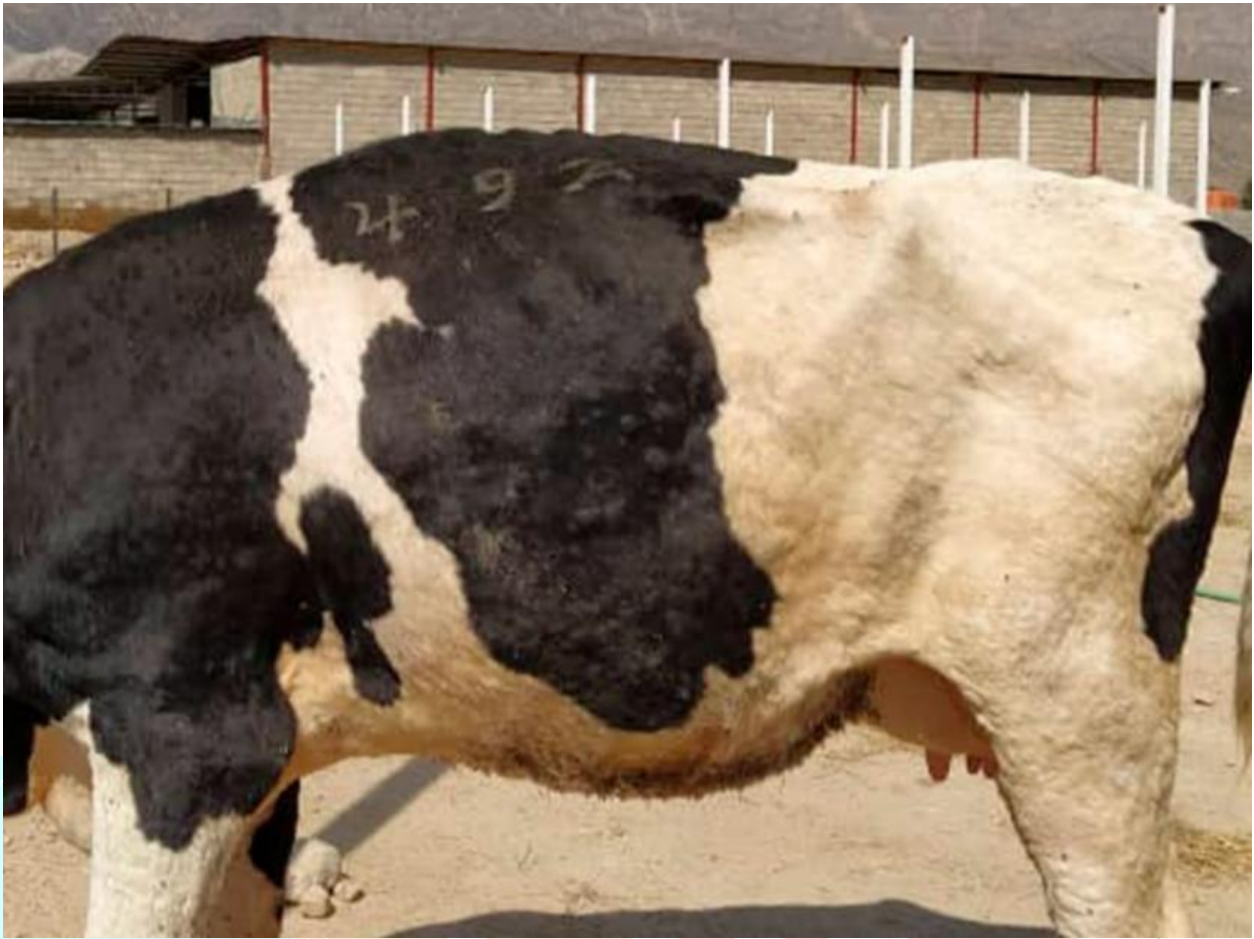Animals that have recovered from a viral infection have displayed lifetime immunity. Due to developed maternal antibodies, calves from infected dams are resistant to clinical illness for about 6 months<sup>41</sup>. The reduced rate of lymphocyte diffusion and phagocytic motion throughout the next fourteen days post infection is exposed by the host immunological condition<sup>44</sup>.

## Clinical signs and symptoms:-

Some of the clinical signs of the illness is fever, insufficiency, nasal discharge, salivation, lachrymation, swollen lymph nodes, a significant decrease in milk production, and loss of body weight<sup>45,46,47</sup>. In addition, the condition is distinguished by firm, slightly elevated, circumscribed skin nodules with a diameter of 2–7 cm that commonly develop on the neck, legs, tail, and back shortly after the onset of fever<sup>48,49</sup> (Figure 3).

In aborted foetuses with necropsy, nodules were not seen, although lung oedema and congestion, as well as nodules all over the lungs and digestive system, were frequently seen<sup>50</sup>. Keratitis, diarrhoea, lameness, pneumonia, mastitis, and myiasis were listed as the symptoms of a severe illness<sup>51, 52</sup>.





**Figure 3.** Lumpy skin disease. Raised, circumscribed nodular lesions

The differential diagnosis of LSD includes the following conditions: pseudolumpy skin disease, urticaria, streptotrichosis (*Dermatophilus congolensis* infection), ringworm, *Hypoderma bovis* infection, photosensitization, bovine papular stomatitis, foot and mouth disease, bovine viral diarrhoea, and malignant catarrhal fever<sup>53</sup>.

### **Economic Impact:-**

Lumpy skin disease is regarded as a disease of cattle with significant economic impact; outbreaks with high morbidity and the potential to cause chronic debility in affected animals can result in significant economic losses<sup>54</sup>. The disease causes economic losses because it decreases milk supply, affects appetite and weight loss, stunts growth, causes abortions and infertility, damages the skin, and causes pneumonia, especially in animals with mouth and respiratory tract lesions<sup>55</sup>.

The expense of vaccine, quarantine and treatment, labour and feed costs, eradication, upkeep of farm biosecurity, and other factors are included in the indirect economic impact of LSD. In addition to the prolonged period for fattening, farm owners must incur additional costs for feed supplements for sick animals throughout their recovery<sup>56</sup>.

### **Diagnosis of LSDs:-**

A presumptive LSD diagnosis can be made using the clinical history, clinical symptoms, and indicators of infected animals. A confirming laboratory diagnosis is performed during the nodular skin lesion manifestation stage. There is no diagnostic testing equipment available<sup>13</sup>. The majority of the confirmatory tests in the form of traditional or real-time Capri poxvirus-specific polymerase chain reactions (PCRs)<sup>57</sup>.

For viral isolation and molecular testing, fluids such as saliva, nasal swabs, or whole blood can be taken from clinically infected animals<sup>58</sup>. Serological tests such as the Virus Neutralization Test (VNT), Indirect Fluorescent Antibody Test (IFAT), Indirect Immunofluorescence Test, and Serum Neutralization Test (SNT) can also be used to diagnose the disease<sup>59,60</sup>.

### **Treatment:-**

Sick animals should be taken out of the herd and given supportive care, including antibiotics, anti-inflammatory medications, and vitamin injections. These treatments typically lessen the likelihood of additional bacterial infections, inflammation, and fever, which increases the animal's appetite<sup>61</sup>.

### **Prevention And Control:-**

The distribution of capripoxviruses seems to be expanding due to limited access to effective vaccines and poverty in farming communities in endemic regions, as well as the increased legal and illegal trading of live animals, besides global climate changes. Vaccination is the only effective method to control the disease in endemic areas along with movement restrictions and the removal of affected animals<sup>49</sup>. The culling of affected animals, movement restrictions and compulsory and consistent vaccination have been recommended as control strategies<sup>48,62</sup>.

Capripoxviruses appear to be spreading more widely because to a lack of readily available vaccines, poverty in farming communities in endemic areas, an increase in the legal and criminal trade in live animals, as well as global climatic changes. The disease can only be managed in endemic areas through vaccination, movement restrictions, and the killing of infected animals<sup>49</sup>. As control measures, the killing of infected animals, restrictions on their freedom to migrate, and mandatory vaccination have all been suggested<sup>48,62</sup>. Live vaccinations effectively prevent the transmission of disease and elicit a potent, enduring immune response<sup>63</sup>.

Live vaccinations, though, have the potential to result in localised inflammation, a minor illness, and skin lesions. Although inactivated vaccines are pricey and require multiple administrations, they are safe, and it is possible to mix them with other antigens to create polyvalent vaccinations that may be used in nations without illness. Furthermore, as part of a strategy that prioritises live vaccines first, inactivated vaccines might be used in the ultimate phase of disease eradication<sup>64</sup>.

### **Need of work:-**

Lumpy skin disease is an emerging condition, and the recent rapid development of the illness in formerly disease-free nations emphasises the significance of comprehending its restrictions and channels of dissemination. The goal of the current review is to convey current knowledge regarding the disease's many facets.

### **Conclusion:-**

One of the transnational, viral illnesses of domestic cattle with the greatest economic impact is lumpy skin disease. Animals who suffer from chronic debility, decreased milk output and weight, damaged skins, abortion, and mortality are economically significant<sup>13</sup>. The marginal farmers are in grave danger from the lumpy skin illness. Most African and Middle Eastern nations currently have LSD available. LSD is frequently identified using certain clinical indicators and differential diagnosis.

On the other hand, milder and subclinical variants necessitate prompt and precise laboratory tests to confirm the diagnosis. As measures to prevent future spread, vaccination with the homologous strain of the LSDV, vector management, limiting the movement of animals, and LSDV testing of bulls used for mating are all strongly advised

**References:-**

1. Gupta, T., Patial, V., Bali, D., Angaria, S., Sharma, M., & Chahota, R. (2020). A review: Lumpy skin disease and its emergence in India. *Veterinary research communications*, 44(3), 111-118.
2. Tran, H. T. T., Truong, A. D., Dang, A. K., Ly, D. V., Nguyen, C. T., Chu, N. T., ... & Dang, H. V. (2021). Lumpy skin disease outbreaks in vietnam, 2020. *Transboundary and Emerging Diseases*, 68(3), 977-980.
3. Das, M., Chowdhury, M. S. R., Akter, S., Mondal, A. K., Uddin, M. J., Rahman, M. M., & Rahman, M. M. (2021). An updated review on lumpy skin disease: Perspective of southeast asian countries. *J. Adv. Biotechnol. Exp. Ther*, 4(3), 322-333.
4. Kardjadj, M. (2016). Capripoxviruses: transboundary animal diseases of domestic ruminants. *Ann. Virol. Res*, 2(3), 1024.
5. Namazi, F., & Khodakaram Tafti, A. (2021). Lumpy skin disease, an emerging transboundary viral disease: A review. *Veterinary Medicine and Science*, 7(3), 888-896.
6. Abdulqa, H. Y., Rahman, H. S., Dyary, H. O., & Othman, H. H. (2016). Lumpy skin disease. *Reprod. Immunol. Open Access*, 1(25), 2476-1974.
7. Sprygin, A., Pestova, Y., Wallace, D. B., Tuppurainen, E., & Kononov, A. V. (2019). Transmission of lumpy skin disease virus: A short review. *Virus research*, 269, 197637.
8. Khalafalla, A. (2022). Lumpy Skin Disease: An Economically Significant Emerging Disease.
9. Abutarbush, S. M., & Tuppurainen, E. S. (2018). Serological and clinical evaluation of the Yugoslavian RM 65 sheep pox strain vaccine use in cattle against lumpy skin disease. *Transboundary and emerging diseases*, 65(6), 1657-1663.
10. Tuppurainen, E. S., Pearson, C. R., Bachanek-Bankowska, K., Knowles, N. J., Amareen, S., Frost, L., ... & Mertens, P. P. (2014). Characterization of sheep pox virus vaccine for cattle against lumpy skin disease virus. *Antiviral research*, 109, 1-6.
11. Quinn, P. J., Markey, B. K., Leonard, F. C., FitzPatrick, E. S., & Fanning, S. (2015). Concise review of veterinary microbiology.
12. OIE (2021). Lumpy skin Disease (LSD). Situation in Bhutan <https://rr-asia.oie.int/wp-content/uploads/2021/01/1-Presentation-on-lsd-outbreaks-in-bhutan-2020.pdf>.
13. Tuppurainen, E. S. M., & Oura, C. A. L. (2012). Lumpy skin disease: an emerging threat to Europe, the Middle East and Asia. *Transboundary and emerging diseases*, 59(1), 40-48.
14. OIE (2021). Technical meeting on lumpy skin disease (LSD). LSD situation in Viet Nam. [https://rr-asia.oie.int/wpcontent/uploads/2021/01/4-201221\\_lsd\\_vietnam\\_update\\_oie\\_meeting.pdf](https://rr-asia.oie.int/wpcontent/uploads/2021/01/4-201221_lsd_vietnam_update_oie_meeting.pdf)
15. Abera, Z., Degefu, H., Gari, G. and Ayana, Z. (2015) Review on Epidemiology and Economic Importance of Lumpy Skin Disease. *International Journal of Basic and Applied Virology*, 4, 8-21.
16. OIE (2021). Current LSD outbreak situation and control measures implemented in Myanmar. [https://rrasia.oie.int/wp-content/uploads/2021/01/2-lsd ppt\\_20122020\\_mtmmyanmar.pdf](https://rrasia.oie.int/wp-content/uploads/2021/01/2-lsd ppt_20122020_mtmmyanmar.pdf).
17. [https://en.m.wikipedia.org/wiki/Lumpy\\_skin\\_disease\\_outbreak\\_in\\_india](https://en.m.wikipedia.org/wiki/Lumpy_skin_disease_outbreak_in_india)
18. <https://indianexpress.com/article/India/lumpy-skin-disease-punjab-haryana-hp-together-see-over-25000-deaths-8172890/lite/>
19. [https://m.timesofindia.com/city/indore/indore-reports-first-death-due-to-lumpy-skin-disease/amp\\_articles/94237764.cms](https://m.timesofindia.com/city/indore/indore-reports-first-death-due-to-lumpy-skin-disease/amp_articles/94237764.cms)
20. <https://www.thehindubusinessline.com/economy/agri-business/lumpy-skin-disease-1436-cattle-die-in-maharashtra/article65965688.ece/amp/>
21. Rao, Lingamgunta Nirmitha (21 September 2022). Goswami, Sohini (ed.). "Lumpy skin disease: Lakhs of cattle suffer, Rajasthan worst-hit". *Hindustan Times*. Retrieved 24 September 2022.
22. Munjal, Diksha (20 September 2022). "Explained | What is lumpy skin disease in cattle? Does it affect milk we consume?". *The Hindu*. ISSN 0971-751X. Retrieved 24 September 2022.
23. Lalchandani, Neha (29 September 2022). "Lumpy skin disease spreads to other parts of UP". *The Times of India*. Retrieved 3 October 2022.



24. "Over 67,000 Cattle Died So Far By Lumpy Virus In India: Government". NDTV. Press Trust of India. 12 September 2022. Retrieved 25 September 2022
25. European Food Safety Authority (EFSA), Calistri, P., De Clercq, K., Gubbins, S., Klement, E., Stegeman, A., ... & Broglia, A. (2020). Lumpy skin disease epidemiological report IV: Data collection and analysis. *Efsa Journal*, 18(2), e06010.
26. Zeynalova, S., Asadov, K., Guliyev, F., Vatani, M., & Aliyev, V. (2016). Epizootology and molecular diagnosis of lumpy skin disease among livestock in Azerbaijan. *Frontiers in Microbiology*, 1022.
27. Gumbe, A. A. F. (2018). Review on lumpy skin disease and its economic impacts in Ethiopia. *J. Dairy Vet. Anim. Res*, 7(2), 39-46.
28. Gubbins, S. (2019). Using the basic reproduction number to assess the risk of transmission of lumpy skin disease virus by biting insects. *Transboundary and emerging diseases*, 66(5), 1873-1883.
29. Tuppurainen, E., Alexandrov, T., & Beltrán-Alcrudo, D. J. F. A. P. (2017). Lumpy skin disease-a manual for veterinarians. *FAO Animal Production and Health Manual*, (20).
30. Annandale, C. H., Holm, D. E., Ebersohn, K., & Venter, E. H. (2014). Seminal transmission of lumpy skin disease virus in heifers. *Transboundary and emerging diseases*, 61(5), 443-448.
31. Kasem, S., Saleh, M., Qasim, I., Hashim, O., Alkarar, A., Abu-Obeida, A., ... & Abdelatif, M. (2018). Outbreak investigation and molecular diagnosis of Lumpy skin disease among livestock in Saudi Arabia 2016. *Transboundary and emerging diseases*, 65(2), e494-e500.
32. Sprygin, A., Pestova, Y., Wallace, D. B., Tuppurainen, E., & Kononov, A. V. (2019). Transmission of lumpy skin disease virus: A short review. *Virus research*, 269, 197637.
33. Ali, H., Ali, A. A., Atta, M. S., & Cepica, A. (2012). Common, emerging, vector-borne and infrequent abortogenic virus infections of cattle. *Transboundary and emerging diseases*, 59(1), 11-25.
34. Rouby, S., & Aboulsoud, E. (2016). Evidence of intrauterine transmission of lumpy skin disease virus. *The Veterinary Journal*, 209, 193-195.
35. Lubinga, J. C., Tuppurainen, E. S. M., Stoltz, W. H., Ebersohn, K., Coetzer, J. A. W., & Venter, E. H. (2013). Detection of lumpy skin disease virus in saliva of ticks fed on lumpy skin disease virus-infected cattle. *Experimental and applied acarology*, 61(1), 129-138.
36. Hailu, B., Tolosa, T., Gari, G., Teklue, T., & Beyene, B. (2014). Estimated prevalence and risk factors associated with clinical Lumpy skin disease in north-eastern Ethiopia. *Preventive Veterinary Medicine*, 115(1-2), 64-68.
37. Mulatu, E., & Feyisa, A. (2018). Lumpy Skin Disease. *Journal of Veterinary Science & Technology*.
38. Constable, P. D., Hinchcliff, K. W., Done, S. H., & Grünberg, W. (2016). *Veterinary medicine: a textbook of the diseases of cattle, horses, sheep, pigs and goats*. Elsevier Health Sciences.
39. Coetzer, J. A. W., & Tuppurainen, E. (2004). Lumpy skin disease. *Infectious diseases of livestock*, 2, 1268-1276.
40. Bowden, T. R., Babiuk, S. L., Parkyn, G. R., Copps, J. S., & Boyle, D. B. (2008). Capripoxvirus tissue tropism and shedding: A quantitative study in experimentally infected sheep and goats. *Virology*, 371(2), 380-393.
41. Tuppurainen, E. S., Venter, E. H., & Coetzer, J. A. W. (2005). The detection of lumpy skin disease virus in samples of experimentally infected cattle using different diagnostic techniques. *Onderstepoort Journal of Veterinary Research*, 72(2), 153-164.
42. Gumbe, A. A. F. (2018). Review on lumpy skin disease and its economic impacts in Ethiopia. *J. Dairy Vet. Anim. Res*, 7(2), 39-46.
43. Lubinga, J. C., Tuppurainen, E. S., Coetzer, J. A., Stoltz, W. H., & Venter, E. H. (2014). Transovarial passage and transmission of LSDV by *Amblyomma hebraeum*, *Rhipicephalus appendiculatus* and *Rhipicephalus decoloratus*. *Experimental and applied acarology*, 62(1), 67-75.
44. Hendrickx, G., Gilbert, M., Staubach, C., Elbers, A., Mintiens, K., Gerbier, G., & Ducheyne, E. (2008). A wind density model to quantify the airborne spread of *Culicoides* species during north-western Europe bluetongue epidemic, 2006. *Preventive veterinary medicine*, 87(1-2), 162-181.

45. Abutarbush, S. M., Ababneh, M. M., Al Zoubi, I. G., Al Sheyab, O. M., Al Zoubi, M. G., Alekish, M. O., & Al Gharabat, R. J. (2015). Lumpy Skin Disease in Jordan: Disease Emergence, Clinical Signs, Complications and Preliminary-associated Economic Losses. *Transboundary and emerging diseases*, 62(5), 549-554.
46. Annandale, C. H., Holm, D. E., Ebersohn, K., & Venter, E. H. (2014). Seminal transmission of lumpy skin disease virus in heifers. *Transboundary and emerging diseases*, 61(5), 443-448.
47. Babiuk, S., Bowden, T. R., Boyle, D. B., Wallace, D. B., & Kitching, R. P. (2008). Capripoxviruses: an emerging worldwide threat to sheep, goats and cattle. *Transboundary and emerging diseases*, 55(7), 263-272.
48. Beard, P. M. (2016). Lumpy skin disease: a direct threat to Europe. *The Veterinary Record*, 178(22), 557.
49. Şevik, M., & Doğan, M. (2017). Epidemiological and molecular studies on lumpy skin disease outbreaks in Turkey during 2014–2015. *Transboundary and emerging diseases*, 64(4), 1268-1279.
50. Zeynalova, S., Asadov, K., Guliyev, F., Vatani, M., & Aliyev, V. (2016). Epizootology and molecular diagnosis of lumpy skin disease among livestock in Azerbaijan. *Frontiers in Microbiology*, 1022.
51. Al-Salihi, K. A., & Hassan, I. Q. (2015). Lumpy skin disease in Iraq: study of the disease emergence. *Transboundary and emerging diseases*, 62(5), 457-462.
52. Tuppurainen, E. S. M., Venter, E. H., Shisler, J. L., Gari, G., Mekonnen, G. A., Juleff, N., ... & Babiuk, L. A. (2017). Capripoxvirus diseases: current status and opportunities for control. *Transboundary and emerging diseases*, 64(3), 729-745.
53. Abutarbush, S. M. (2017). Lumpy skin disease (knopvelsiekte, pseudo-urticaria, neethling virus disease, exanthema nodularis bovis). In *Emerging and re-emerging infectious diseases of livestock* (pp. 309-326). Springer, Cham.
54. Siraw, B. (1987). Bovine Dermatophilus infection in mend you province: prevalence and relative efficacy of different drugs against the disease. *Onderstepoort j vet res*, 83(1).
55. OIE (2010) Terrestrial Manual of Lumpy Skin Disease, Chapter 2.4.14. Version adopted by the World Assembly of Delegates of the OIE in May 2010, OIE, Paris
56. Green, H. F. (1959). Lumpy skin disease: its effect on hides and leather and a comparison on this respect with some other skin diseases. *Bull. Epizoot. Dis. Afr*, 7, 63-74.
57. Alemayehu, G., Zewde, G., & Admassu, B. (2013). Risk assessments of lumpy skin diseases in Borena bull market chain and its implication for livelihoods and international trade. *Tropical Animal Health and Production*, 45, 1153-1159.
58. Peck, D., & Bruce, M. (2017). The economic efficiency and equity of government policies on brucellosis: comparative insights from Albania and the United States of America. *Revue scientifique et technique (International Office of Epizootics)*, 36(1), 291-302.
59. Molla, W., de Jong, M. C., Gari, G., & Frankena, K. (2017). Economic impact of lumpy skin disease and cost effectiveness of vaccination for the control of outbreaks in Ethiopia. *Preventive veterinary medicine*, 147, 100-107.
60. Brenner, J. (2006). Lumpy skin disease in a large dairy herd in Israel ([http://www. Isrvma. Org/ImageToArticle/Files/Vol\\_6\\_1-3-4](http://www.Isrvma.Org/ImageToArticle/Files/Vol_6_1-3-4)). *Israeli Journal of Veterinary Medicine*, 61, 3-4.
61. Saiyad, S., Patel, H., & Bhandari, B. (2022). Lumpy skin disease (LSD): An overview.
62. Singh, R. Lumpy Skin Disease (LSD): An Emerging Transboundary Viral Disease.
63. Tuppurainen, E. S. M., Antoniou, S. E., Tsiamadis, E., Topkaridou, M., Labus, T., Debeljak, Z., ... & Broglia, A. (2020). Field observations and experiences gained from the implementation of control measures against lumpy skin disease in South-East Europe between 2015 and 2017. *Preventive Veterinary Medicine*, 181, 104600.
64. Hamdi, J., Boumart, Z., Daouam, S., El Arkam, A., Bamouh, Z., Jazouli, M., ... & El Harrak, M. (2020). Development and evaluation of an inactivated lumpy skin disease vaccine for cattle. *Veterinary microbiology*, 245, 108689.