



ROLE OF LESSER KNOWN HOMOEOPATHIC MEDICINES IN THE MANAGEMENT OF HERPES ZOSTER

¹Dr. Nidhi Kala

¹M.D. (PGR),

¹Department of Materia Medica,

¹ Bakson Homoeopathic Medical College and Hospital, Greater Noida-201310, Uttar Pradesh, India

ABSTRACT: Herpes zoster is a viral syndrome that affects aged and less immunized patients after primarily infection by Varicella zoster virus which remains dormant in the nervous system for decades. It is a localized, blistering and painful rash that occurs in adults or elderly. This article outlines the basic of herpes, its type, etiology, pathophysiology, clinical presentation, complication and use of lesser known homoeopathic medicines in case of Herpes Zoster.

KEYWORDS - Herpes zoster, Herpes Simplex, Varicella, Shingles, Post Herpetic Neuralgia, Lesser known homoeopathic medicines

I. INTRODUCTION

Herpes zoster is usually called shingles, derived from the latin word cingulum means “belt” or “girdle”. In shingles rash commonly appears in a band or belt-like sample that is why it is named so.¹ It is an acute viral infection involving the first sensory neurone of various nerves with appearance of skin vesicular eruptions with painful neuralgia in the dermatome distribution and caused by reactivation of varicella-zoster virus, which is the same virus that is responsible for Chickenpox.² After an episode of chickenpox when the patients were cured of this primary infection, the varicella-zoster virus remains dormant in the root of ganglia and cranial nerve then reactivation of the virus cause Herpes zoster infection.³ When immune system become weak either due to chronic illness, stress or any medications then fails to control the latent replication of the virus which leads to reactivation of zoster virus. The Herpes viruses are large double-stranded DNA viruses which have the ability to settle with lifelong latency into the host and reactivate periodically.⁴

The increased incidence of herpes zoster is strongly associated with advancing of age and decreased immunity of an individual by any cause cancer, immune deficiency diseases, and any treatment that causes immunosuppression.⁵ The incidence of herpes zoster is 3.9 to 11.8 per 1000 persons per year among patients older than 65 years which is more in comparison to younger healthy individuals i.e. 1.2 to 3.4 per 1000 persons per year.³ ICD 10 code for Herpes zoster is B02⁶

There are 8 different types of Herpes Virus which affects human are:⁷

Herpes Virus	Other name	Disease
Herpes Simplex Virus (HSV) I	Oral Herpes	Oral lesions/ Cold Sores
HSV 2	Genital Herpes	Genital lesions
Human Herpes Virus(HHV) 3	Varicella Zoster Virus (VZV) – Shingle	Shingle
HHV4	Epstein-Barr Virus (EBV)	Infectious Mononucleosis
HHV 5	Cytomegalovirus (CMV)	Mononucleosis
HHV 6 & 7	-	Roseola
HHV 8	-	Kaposi's Sarcoma

II. ETIOLOGY^{2,3}

The causative organism is a herpes zoster virus which affects the posterior root ganglia.

Risk factors for herpes zoster include

• Increasing age	• Emotional stress
• Female	• Injury
• Subarachnoid haemorrhage	• Immunosuppression by disease, HIV
• Spinal Metastasis from Carcinoma	• Use of medicines
• Hodgkin's Disease	• Transplant and related drugs

III. PATHOPHYSIOLOGY^{8,3}

VZV is a double stranded DNA virus protected by a protein coat called capsid which is enclosed in a lipid membrane. When virus comes in contact with respiratory mucosa or the skin of an uninfected person, it starts replicating in the epithelial cells. It soon gets picked up by the nearby immune cells and get transported to nearby lymph node. Now virus will cause primary infection called Chickenpox and it has 2 stages- Primary viremia and secondary viremia. In primary viremia, the virus infects a part of immune system in the liver and spleen called reticulo-endothelial system. About 2 weeks after entering body, the virus starts infecting immune cells themselves specifically t-cells and that is considered as Secondary viremia.

Infected T cells start expressing protein that bind to receptors on the skin cells. Its like the virus travels with t-cells to the skin. Once t-cells reach skin, they release virus which start infecting keratinocytes. The infection spread through skin goes directly from cell to cell. Uninfected cells start secreting interferon alpha and beta which inhibits viral protein synthesis and protect those cells getting infected. Virus also affects sensory neurons in skin and through those neurons it travels in retrograde direction to the Dorsal root ganglion or if it is on face then trigeminal ganglion.

Over the time, when immune-system reaction expel out most of the viruses but the ones in the ganglion are spared and remain dormant for many years. Later on if the immune system weakens due to aging, stress or immunosuppressant therapy the virus can be reactivated. Then it can travel back up through the sensory neuron to the skin and cause an infection in the innervated dermatome i.e. Shingles.

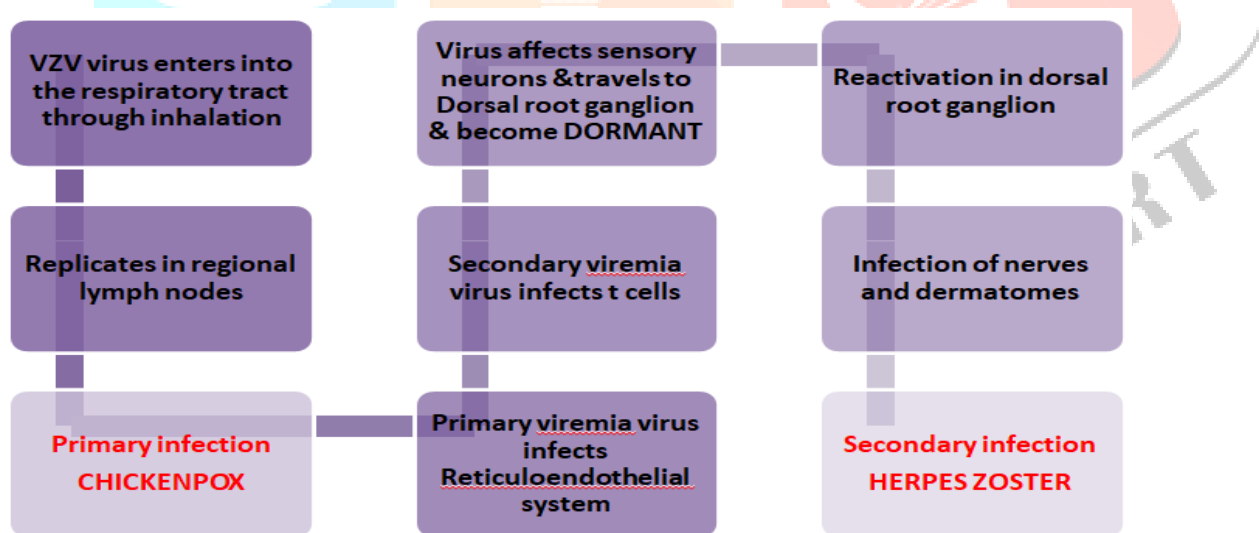


Fig 1. Pathophysiology of Herpes zoster

IV. TRANSMISSION⁹

- In localized zoster, transmission happens through contact with the fluid within the blisters of the rash. A person isn't infectious earlier than the blisters seem or after the rash has crusted over.
- Disseminated zoster, transmission takes place through airborne and droplet transmission, in addition to contact with fluid in the blisters of the rash. Disseminated zoster is as infectious as varicella

V. CLINICAL FEATURES^{2,3,10}

Zoster characteristically presents with a prodrome of fever, malaise, and severe burning pain followed by the outbreak of vesicles. Clinically, lesions start as closely grouped erythematous papules, vesicles or bullous lesions containing clear fluid inside and lastly pustules are formed on an erythematous and edematous base and may occur in continuous or interrupted bands in one, two, or more contiguous dermatomes unilaterally. A single unilateral dermatome is involved commonly thoracic (53%), cervical (20%), and trigeminal (15%) including ophthalmic and lumbosacral (11%) are involved.

The three phases of the infection include:

Pre-eruptive phase:	Acute eruptive phase	Chronic phase
<p>-Pre herpetic neuralgia- numbness, stabbing, burning</p> <p>-Burning pain, tingling, paresthesia in one or more dermatomes</p> <p>-appears at approx. 48 hours prior to any obvious lesions.</p> <p>-headaches, general malaise, myalgia and photophobia.</p>	<p>-initially start as macules and quickly transform into painful vesicles.</p> <p>-vesicles often rupture, ulcerate and eventually crust over.</p> <p>-Vesicles are unilateral, does not <i>cross midline</i></p> <p>-Infectious stage until the lesion dry out.</p> <p>-Thoracic and lumbar dermatomes most commonly involved</p> <p>-Regional lymphadenopathy last 2-4weeks but the pain may continue.</p>	<p>-Post herpetic neuralgia with shock like sensation</p> <p>-Persistent pain in the area of prior acute eruption</p> <p>-Scarring can occur</p> <p>-High rates 60-70% in elderly above 60years</p> <p>-lasts more than 4 weeks.(can be months or years)</p>

Other form of herpes zoster virus according to the affected areas-^{2,3,10}

1. Geniculate zoster /Herpes zoster oticus / Ramsay Hunt syndrome

It is an acute infection of geniculate ganglion of the facial nerve, which ultimately affect ear and mouth. It is a triad of *ipsilateral facial paralysis, otalgia, and vesicles near the ear and auditory canal*.

2. Herpes zoster of maxillary or mandibular branch

Maxillary or mandibular division of trigeminal nerve is involved and affect mouth. It is characterized by vesicles or erosions occurring over the mucous membrane of the upper jaw or the lower jaw along with the skin lesions over the cutaneous distribution of the same trigeminal branch.

3. Gasserian Herpes / Ophthalmic Zoster

It involves ophthalmic division of the trigeminal nerve which causes ophthalmic zoster. The skin of the forehead, upper eyelid, and orbit of the eye may be involved. It is seen in approximately 10% to 25% of cases presenting with features of, keratitis, uveitis, and optic nerve palsies which may lead to blindness.

4. Zoster Encephalitis

It is a viral infection of the CNS so it may extend into brain and spinal cord causing cranial nerve palsies, muscular weakness, diaphragmatic paralysis etc In severe cases, patients may develop encephalitis or myelitis with involvement of pyramidal tract.

VI. DIAGNOSIS¹⁰

Diagnosis is based on the *history* of the patient and *physical findings*.

- Blood test- increased WBC
- PCR for detection of viral DNA of vesicular fluid ,corneal lesion or blood
- Direct fluorescent antibody of vesicular fluid or corneal lesion
- Tzanck smear of vesicular fluid

VII. COMPLICATIONS^{2,3}

- Post-herpetic neuralgia is the commonest side effect seen in elderly patients
- Anesthesia
- Scarring
- Paralysis
- Encephalitis
- Blindness after Ophthalmic Herpes
- Disseminated Herpes

VIII. HOMOEOPATHIC THERAPEUTICS IN HERPES ZOSTER

Many Homoeopathic medicines such as Arsenicum album, Apis, Belladonna, Chamomilla, Cantheris, Dulcamara, Lachesis, Mezerium, Rhus tox, Ranunculus bulbosus, Sepia etc have a great effect if given on the basis of symptom similarity in the management of Herpes zoster. However, when the polychrest remedies are not indicated, fail to relieve the symptoms or there is paucity of symptoms then these lesser known homoeopathic medicine can be thought of. Lesser known medicine means that homoeopathic medicines which have few symptoms and act only on one or two system of body and prescribed on the basis of therapeutic use.¹¹

Characteristic Symptoms of lesser known homoeopathic medicines for Herpes Zoster are:¹²

Asterias rubens- A remedy for the sycotic diathesis; flabby, lymphatic constitution with red face. Nervous disturbances, neuralgia, chorea, and hysteria come within the range of this remedy. *Herpes zoster worse left arm and chest*

Carboneum oxygenisatum- Herpes zoster, pemphigus, and trismus are produced by this drug. Anæsthesia; vesication along the course of nerves; *herpes zoster* with large and small vesicles. Hand icy cold.

Croton tiglium- Herpes zoster; stinging, smarting pains of the eruption. < during summer; *touch*, night and morning, washing. *Intense itching; but scratching is painful*. Pustular eruption, especially on face and *genitals*, with fearful itching, followed by painful burning. Vesicles; confluent oozing. Vesicular erysipelas, itching exceedingly.

Dolichos puriens- Exalted nervous sensibility. Herpes zoster *worse*, at night, scratching, right side. *Constipation, with intense itching; bloated abdomen*.

Grindelia robusta- Rash, like roseola, with severe burning and itching. Vesicular and papular eruptions. Herpes zoster. Itching and burning. *Stops breathing when falling asleep; wakes with a start*, and gasps for breath.

Iris versicolor- This remedy is often helpful for herpes zoster infection that is accompanied by stomach problems with burning sensations and nausea. Eruptions may appear especially on the right side of the abdomen.

Mentha piperita- Stimulates the cold-perceiving nerves, so just after taking it, a current of air at the ordinary temperature seems cold. Marked action on respiratory organs and skin. Every scratch becomes a sore. Itching of arm and hand when writing. Herpes zoster

Prunus spinosa- Very valuable in certain neuralgias, anasarca. Herpes zoster. *Hurriedly impelled to urinate; the urine seems to pass as far as glans, and then returns and causes pain in urethra*.

Salicylicum acid- Itching vesicles and pustules; better by scratching. Sweat without sleep. Hot and burning skin. Herpes zoster.

Sempervivum tectorum -Is recommended for herpes, zoster and *cancerous tumors*. Flushed surface and stinging pains. In obstinate cases; may be used internally and locally.

Variolinum- Used for “internal vaccination”. Hot dry eruption of pustules. Shingles. Morbid fear of small pox.

Zincum phosphoricum- When other remedies fail; Herpes zoster following brain-fag in literary persons.

IX. REFERENCE:

1. Rai NP, C hattopadhyay J et al . Herpes Zoster Infection NP, C Maxillary and Mandibular Branch: A Case Report and Current Trends in Management. Ijcmr. 2016;3(5)
www.ijcmr.com/uploads/7/7/4/6/77464738/_herpes_zoster_infection_of_maxillary_and_mandibular_branchpo.pdf
2. Das. PC. Herpes zoster. Text Book of Medicine. 6th Ed: Current books International; 2016
3. Nair PA, Patel BC. Herpes Zoster. [Updated 2022 Sep 5]. In: StatPearls [Internet]. Treasure Island (FL): StatPearls Publishing; 2022 Jan-. Available from: <https://www.ncbi.nlm.nih.gov/books/NBK441824/>
4. Zarrouk K, Piret J, Boivin G. Herpesvirus DNA polymerases: Structures, functions and inhibitors. Virus Res. 2017 Apr 15;234:177-192. doi: 10.1016/j.virusres.2017.01.019. Epub 2017 Jan 30. PMID: 28153606
5. Arvin A. Aging, immunity, and the varicella-zoster virus. N. Engl J Med; 352: 2266-7, 2005.
6. ICD 10 version 2019. [Internet]
Available from: <https://icd.who.int/browse10/2019/en#/B01.2>
7. What are the different type of Herpes. Nurx.com [Internet]. Available from: <https://www.nurx.com/faq/what-are-the-different-types-of-herpes/>
8. Chickenpox pathophysiology [Internet] 2023 [cited 2023 Jan 23] Available from: https://www.wikidoc.org/index.php/Chickenpox_pathophysiology
9. Managing Herpes Zoster (Shingles) Exposures in Health Care Settings
Available from: <https://www.health.state.mn.us/diseases/shingles/hcexposurezos.pdf>

10. Janniger, Camila K. "Herpes Zoster: Practice Essentials, Background, Pathophysiology." Medscape.com, Dirk M Elston, 21 July 2021, emedicine.medscape.com/article/1132465-overview. Accessed 24 Jan. 2021. Available from: <https://emedicine.medscape.com/article/1132465-overview>
11. Singh P K et al, Utility of lesser Known Homoeopathic medicines in case of Type II Diabetes Mellitus E-ISSN: 2581-8899
12. Boericke W. Pocket Manual of Homoeopathic Materia Medica and Repertory. 9th Edition. New Delhi: B. Jain Publishers (P) Ltd; 2009.

