



# MRI EVALUATION OF CERVICAL OSSIFICATION OF THE POSTERIOR LONGITUDINAL LIGAMENT- A RETROSPECTIVE STUDY IN RURAL TERTIARY HEALTH CARE SETUP.

<sup>1</sup>Dr Yathish B M, <sup>2</sup>Dr Puneet Shirbur, <sup>3</sup>Dr Dayananda Kumar R, <sup>4</sup>Dr Ananya K, <sup>5</sup>Dr Preethi B V

<sup>1</sup> Radiology Resident, <sup>2</sup>Associate Professor, <sup>3</sup>Professor and HOD, <sup>4</sup> Radiology Resident, <sup>5</sup> Radiology Resident, <sup>1</sup>Radiodiagnosis,

<sup>1</sup>MVJ medical college and research hospital, Bangalore Rural, India

## **Abstract:**

Background: Ossification of the posterior longitudinal ligament (OPLL) is a common disease among the elderly population of East Asian countries, although it is seen in all ethnic groups. OPLL is a multifactorial condition caused by ectopic hyperostosis and calcification of the posterior longitudinal ligament. Cervical OPLL is often misdiagnosed on magnetic resonance imaging (MRI). Accurate diagnosis of OPLL is of important since it can cause severe central canal stenosis and myelopathy. Familial inheritance and genetic factors have been implicated in the aetiology of OPLL. The cervical spine is most commonly affected followed by the thoracic spine. The clinical manifestations range from asymptomatic to myelopathy or myeloradiculopathy.

## **Materials and Methods:**

A retrospective study was conducted and cases from September 2020 to September 2022 in MVJ Medical College were included. All the patients who were suspected to have cervical OPLL on lateral x-ray of cervical spine who underwent MRI cervical spine were considered in this study. T1 and T2 weighted MRI sagittal images were obtained which delineated a thick low-signal posterior longitudinal ligament were considered as diagnosis of OPLL.

## **Results:**

- A total of 50 patients suspected to have cervical OPLL on lateral x-ray who underwent MRI cervical spine were identified from September 2020 to September 2022.
- Out of 50 patients a total of 10 (20%) patients were diagnosed of OPLL on MRI.
- Out of 10 patients with OPLL on MRI the majority of the cases were in the elderly age group with peak age group of 50 to 60 years 8 cases (80 %), no patients had OPLL below 40 years age group. 2 cases (20%) were seen at 40 to 50 age group.
- A total of 40 cases (80%) did not have OPLL on MRI.
- Majority of cases were seen in male 9 cases (90%).

Conclusion: Diagnosing cervical OPLL using lateral radiograph alone or MRI alone is prone to overestimation. Multimodality use of lateral x-ray and cervical MRI presents a powerful tool in the diagnosis of cervical OPLL.

Key words: Ossification of the posterior longitudinal ligament, Multimodality.

## I. INTRODUCTION

**Ossification of the posterior longitudinal ligament (OPLL)** is typically an entity seen in patients of Asian descent, although it is seen in all ethnic groups. It is characterized by, as the name suggests, ossification of the posterior longitudinal ligament.

There is a recognized greater prevalence in males and in the elderly<sup>1</sup>. The incidence is more common in the Japanese/Asian population (2.4%)<sup>2</sup>. Patients may be asymptomatic, or have evidence of radiculopathy and/or myelopathy<sup>3</sup>. If present, symptoms usually manifest in the 4<sup>th</sup>-6<sup>th</sup> decades of life<sup>4,5</sup>. The exact pathogenesis of OPLL is rather unclear<sup>6</sup>.

OPLL is often associated with several other entities like diffuse idiopathic skeletal hyperostosis (DISH), ossification of the ligamentum flavum, ankylosing spondylitis<sup>7</sup>, schizophrenia: possible (in one study)<sup>8</sup>. This typically seen in the mid cervical spine and results in central canal stenosis, predisposing the patient to cord injury from minor trauma.

T2-weighted sequences are considered the most effective in the evaluation of spinal cord compression due to both the ossification and abnormal signal intensity of the spinal cord<sup>9</sup>.

## II. AIMS AND OBJECTIVES:

Multimodality use of lateral x-ray of cervical spine and cervical MRI in the diagnosis of cervical OPLL.

## III. MATERIALS AND METHODS:

It is a hospital based retrospective study which includes cases from September 2020 to September 2022 in MVJ Medical College with cases obtained through a computer based search of database. All the patients who were suspected to have cervical OPLL on lateral x-ray of cervical spine who underwent MRI cervical spine were considered in this study. T1 and T2 weighted MRI sagittal images were obtained which delineated a thick low-signal posterior longitudinal ligament were considered as diagnosis of OPLL.

Firstly, a lateral radiograph was checked identifying a high-density structure along the posterior aspect of vertebral bodies as OPLL. Secondly, T1 and T2 weighted MRI sagittal images were obtained which delineated a thick low-signal posterior longitudinal ligament as OPLL.

Instrumentation/imaging modalities included 1.5 Tesla Siemens magneto essenza, T1 and T2 weighted sagittal of MR sequences were evaluated for OPLL.

Microsoft word & Excel were used to generate graphs, tables etc. For descriptive statistics & correlation study, statistical package for social sciences (SPSS) version 17.0 was used.

Inclusion criteria:

All the patients who were suspected to have cervical OPLL on lateral x-ray of cervical spine who underwent MRI cervical spine were considered in this study.

Exclusion Criteria:

- Patients who refused MRI.
- Patients with contraindications for MRI study (eg., Non MRI compatible metallic implants)
- Study which could not be properly assessed due to motion artefacts.

## IV. RESULTS AND DISCUSSION

• A total of 50 patients suspected to have cervical OPLL on lateral x-ray who underwent MRI were identified from September 2020 to September 2022.

• Out of 50 patients a total of 10 (20%) patients were diagnosed of OPLL on MRI.

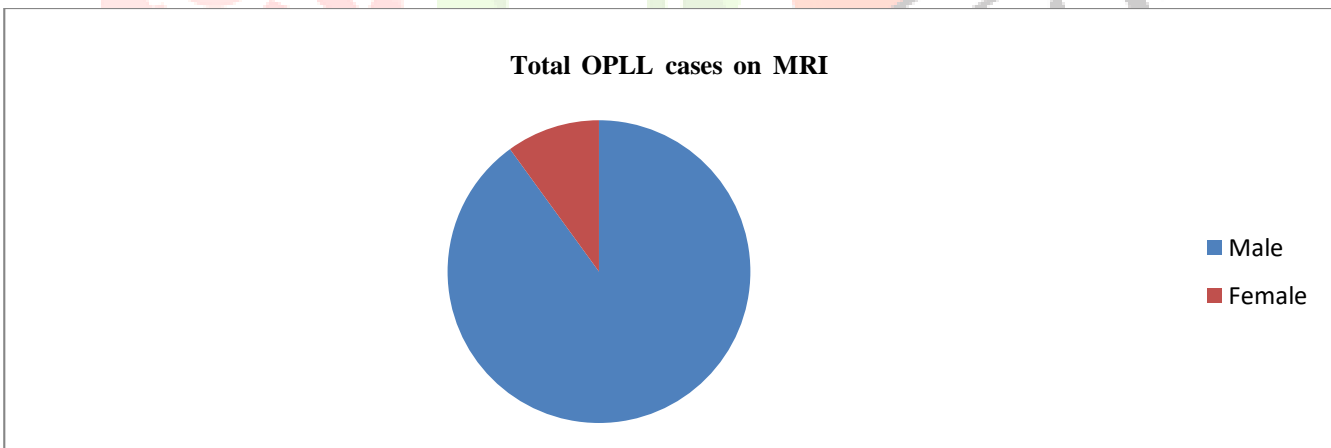
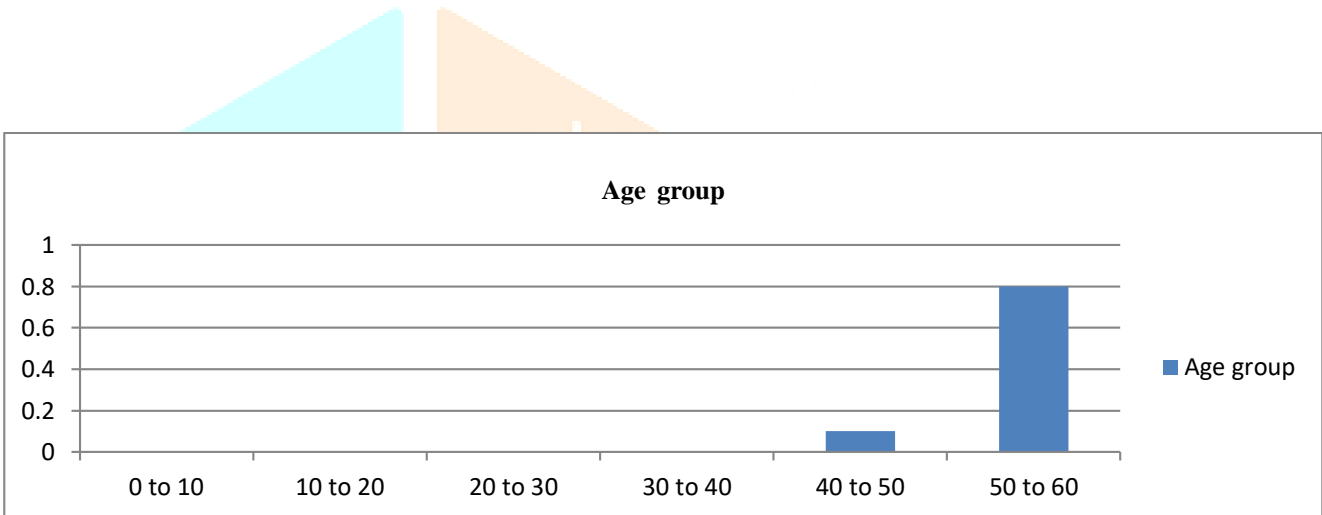
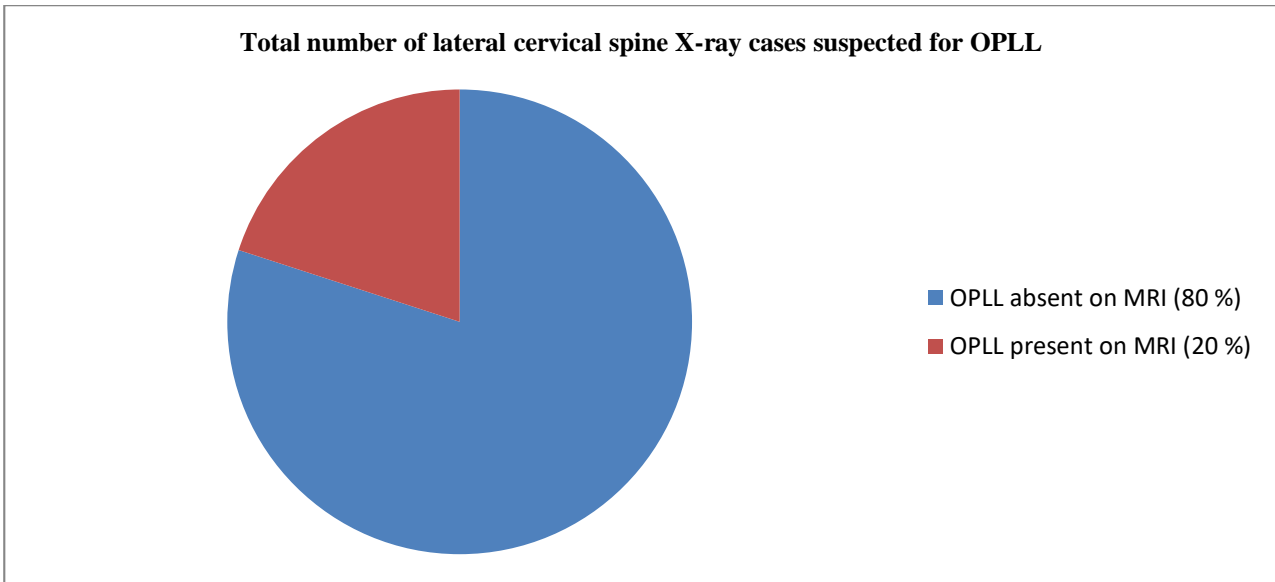
• Out of 10 patients with OPLL on MRI the majority of the cases were in the elderly age group with peak age group of 50 to 60 years 8 cases (80%), no patients had OPLL below 40 years age group. 2 cases (20%) were seen at 40 to 50 age group.

• Majority of cases were seen in male 9 cases (90%).

• A total of 40 cases (80%) did not have OPLL on MRI.

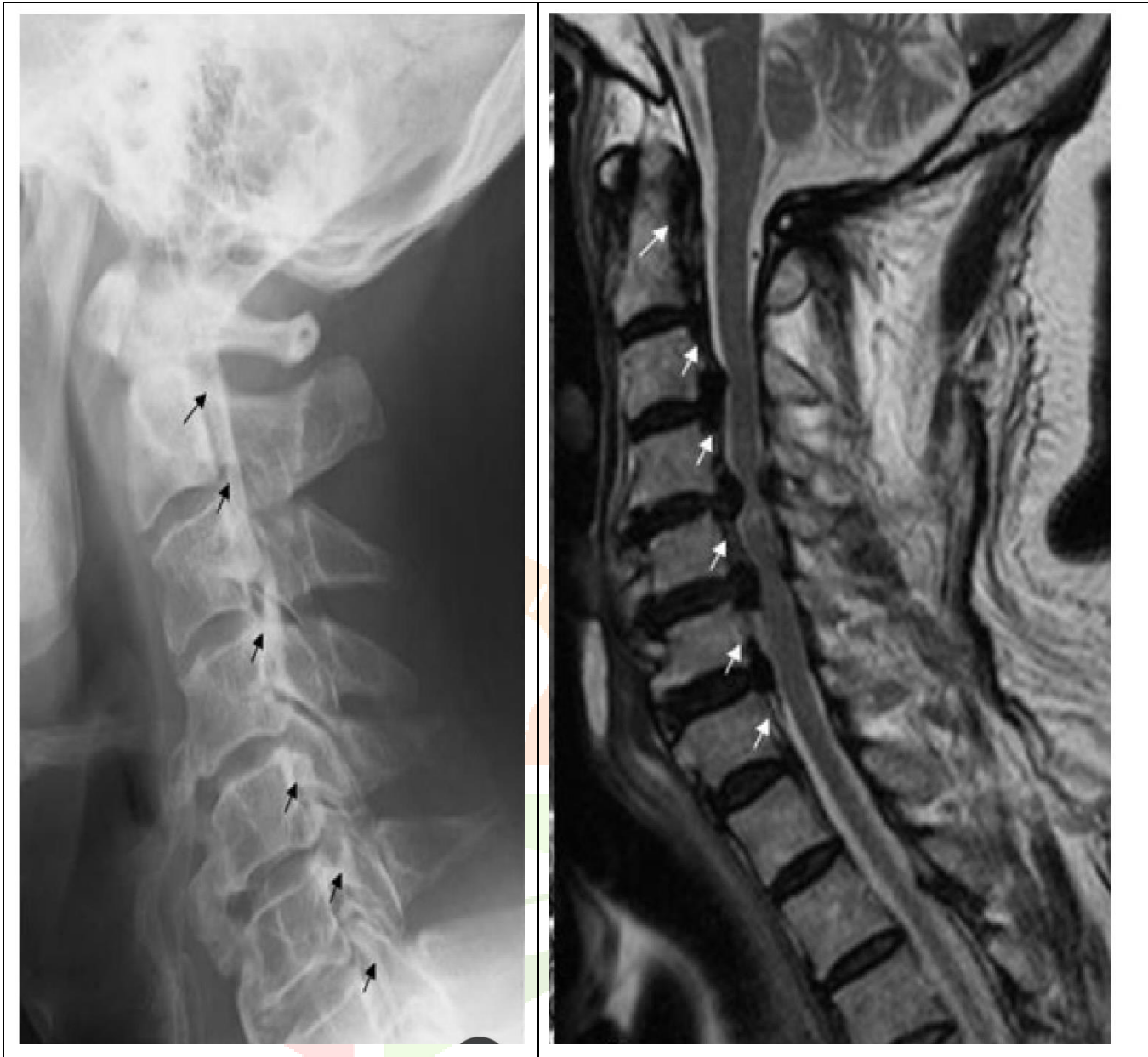• A total of 8 cases (80%) had both cervical OPLL, disc bulges and disc protrusions.

• Most common cervical vertebral level involved was C3, C4 and C5 levels.



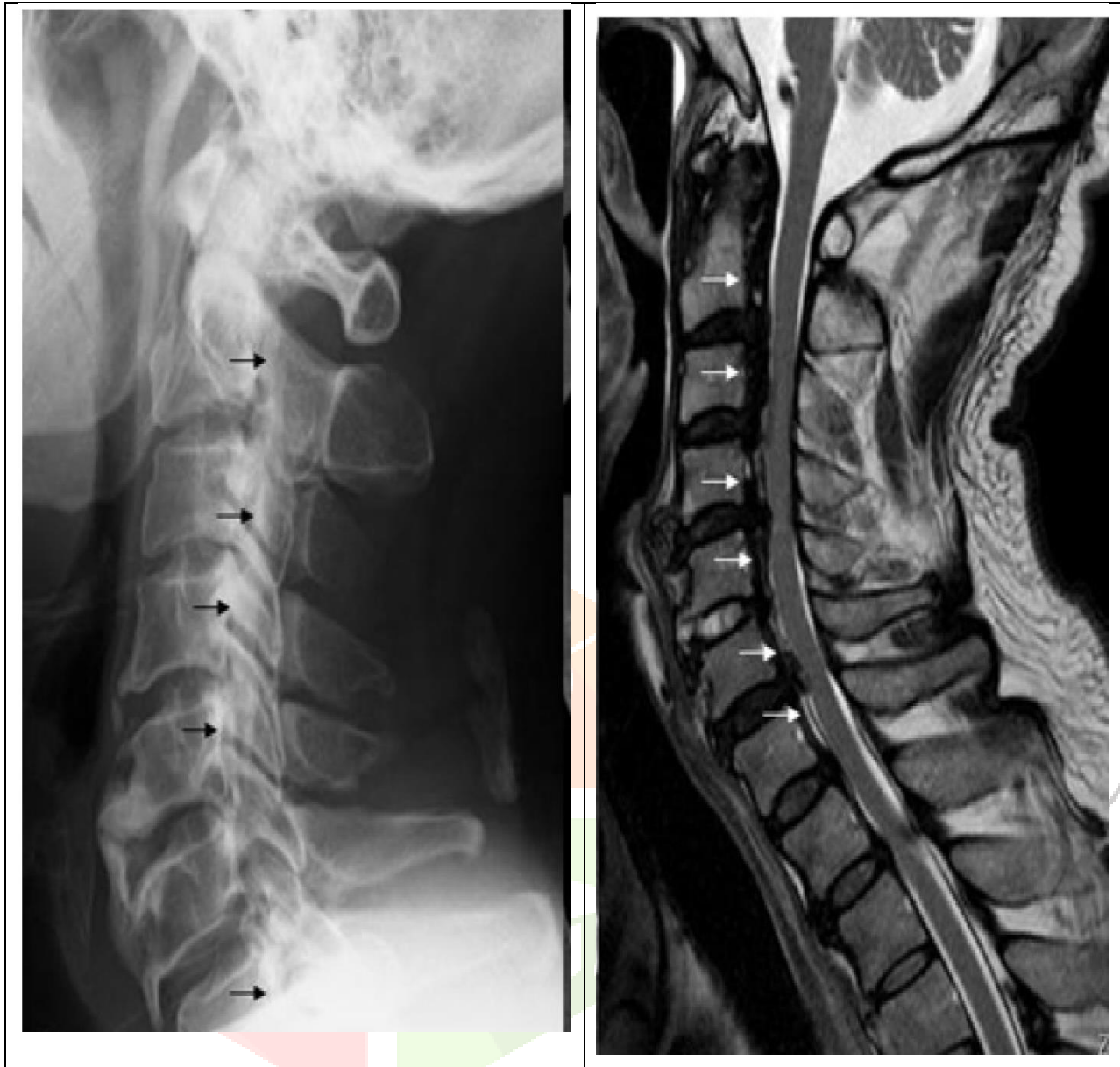**REPRESENTATIVE IMAGES:**

**Case 1: Cervical OPLL Diagnosis using X-rays and MRI in 69-Year-Old Male.**



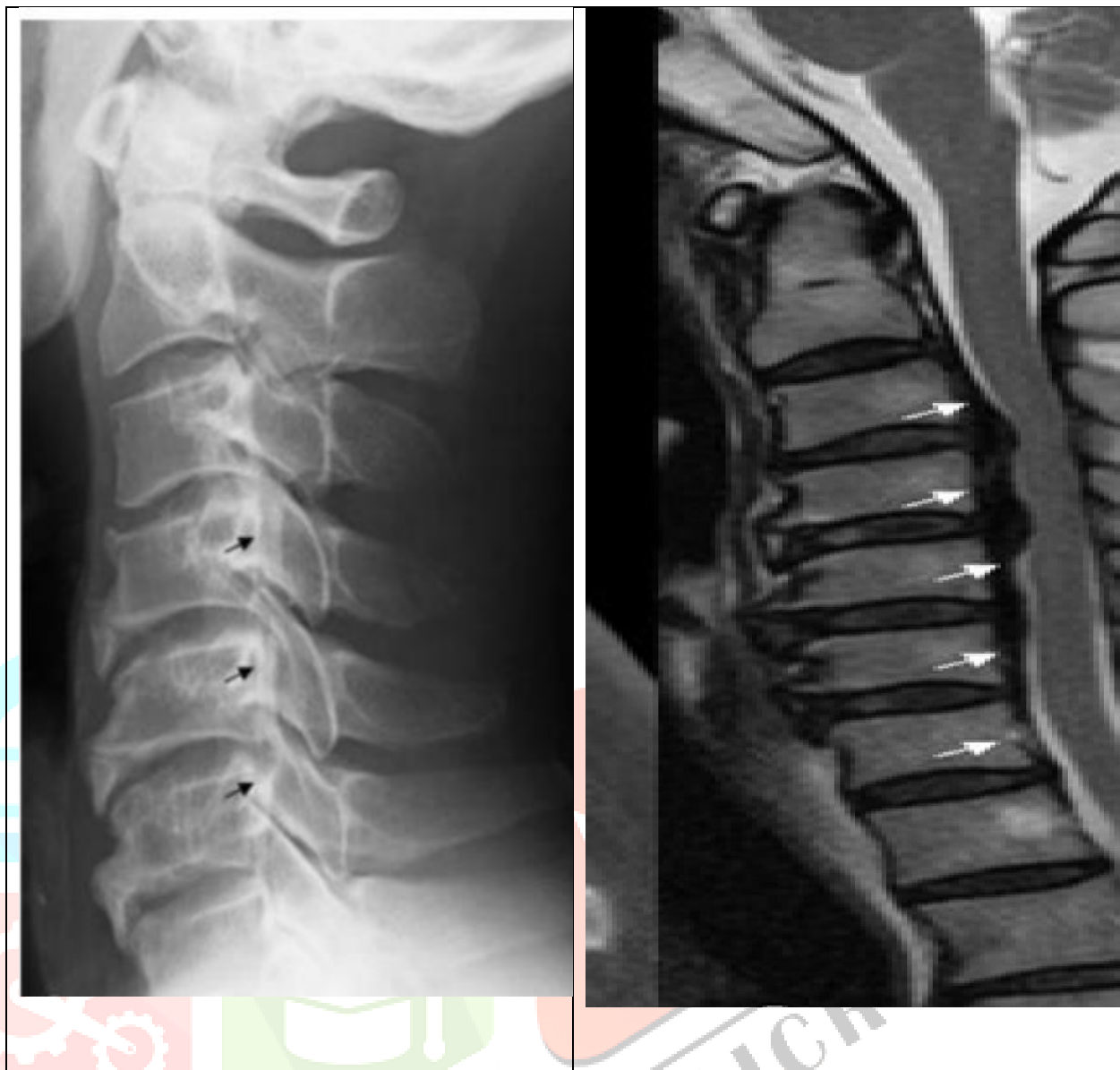
Lateral radiograph: Multiple ossifications are visualized along the vertebral bodies at the level of C2, C3, C4, C5, C6 and C7 (arrows). Bridging spur formations are visualized at the level of C4/5 and C5/6. Ossification of anterior longitudinal ligament is seen between C6 and C7.

T2 weighted sagittal MR image: The longitudinal ligament thickening is demonstrated from C2 to C7 (arrow). Spotty high signal intensity area suggestive of myelomalacia is present at the level of C4/5.

**Case 2: Cervical OPLL Diagnosis using X-rays and MRI in 70-Year-Old Male.**

Lateral radiograph: Dense lesion known as ossification is present at the level of C2, C3, C4, C5 and C7 (arrows). Ossification at C6 level is indistinct. Some spur formations and ossification of anterior longitudinal ligament are visualized at level of C5/6 and C6/7.

T2 weighted sagittal MR image: Diffuse longitudinal ligament thickening with irregular margin is present from C2 to C7 (arrows). Suspected cervical cord compression from C3 to C6.



Lateral radiograph: Band like ossification is present along the vertebral body at level of C4, C5 and C6 (arrows). Some spur formations and ossification of the anterior longitudinal ligament are also seen at the level of C4-5, C5/6 and C6/7.

T2 weighted sagittal MR image: The longitudinal ligament shows partial thickening at the level of C3, C4, C5, C6, and C7. This range is longer than the X-ray. Suspected cervical cord compression at C3/4 and C4/5 levels.

## V. DISCUSSION:

Cervical OPLL was first reported in Japanese population in 1960 by Tsukimoto<sup>10</sup>. In 1964, Terayama<sup>11</sup> defined the cervical OPLL as a clinical entity on the basis of histological findings. Recording cervical X-rays is the first step in the diagnosis of cervical OPLL. In the lateral radiograph, ossification appears as a continuous or segmental bony density projecting into the central spinal canal. However, severe spondylosis and hypertrophy associated with facet joints and pedicles hinder the detection of OPLL in the lateral radiograph. In addition, the appearance of OPLL-like dots within 3 mm thickness is difficult to detect on the lateral radiograph. Conversely, there are difficulties in distinguishing ossifications from ligament hypertrophy via MRI<sup>12</sup>. In MRI, OPLL presents two different types of patterns: The first displays a thick posterior longitudinal ligament with diffuse low signal intensity in both T1 weighted and T2 weighted images. The second pattern illustrates a thick posterior longitudinal ligament with mixed high and low signal intensity in both T1 weighted and T2 weighted images suggestive of bone marrow component. If the bone marrow component is included with the thick posterior longitudinal ligament, that area is absolutely consistent with OPLL. However, if a thick posterior longitudinal ligament with low signal intensity is only present in the MRI report, it would be difficult to diagnose the condition correctly.

Detection of OPLL on each vertebral body varied between X-rays and MRI. Both X-rays and MRI presented respectable accuracy of cervical OPLL at the level of C2, C3 and C4. As for C5, X-rays yielded good accuracy (95.5%), but MRI was prone to overestimation (110.6%). Okada et al<sup>13</sup> reported that the presence of cervical disc degenerative changes was higher in patients with disc extrusion/hernia. Cervical disc hernia at C4/5, C5/6 and C6/7 is particularly more common than the ones at any other level. Accordingly, the overestimation of MRI at C5 could be caused by cervical disc herniation.

In addition, at C6 and C7, low accuracy was observed with MRI and X-rays. Lower levels of cervical spine such as C5, C6 and C7 present a lot of motion and would be associated with more severe osteoarthritis than the upper level of cervical spine<sup>14</sup>. It interferes with the accuracy of X-rays. Regarding cervical OPLL treatment, cervical laminoplasty has become the standard technique for patients with myelopathy. Hori et al<sup>15</sup> reported that young patients with continuous or mixed-type OPLL and C3 ossification had a risk of progression in OPLL thickness following surgery. From our study, detection of OPLL at level of C3 was noteworthy.

## VI. CONCLUSION:

Diagnosing cervical OPLL using lateral radiograph alone or MRI alone is prone to overestimation. Regarding the diagnosis through MRI, it would be difficult to distinguish ossifications from ligament hypertrophy. Multimodality use of lateral x-ray and cervical MRI presents a powerful tool in the diagnosis of cervical OPLL.

## VII. REFERENCES

- Saetia K, Cho D, Lee S et-al. Ossification of the posterior longitudinal ligament: a review. *Neurosurg Focus*. 2011;30 (3): E1. doi:10.3171/2010.11.FOCUS10276 - Pubmed citation.
- Wang MY, Thambuswamy M. Ossification of the posterior longitudinal ligament in non-Asians: Demographic, clinical, and radiographic findings in 43 patients. *Neurosurg Focus*. 2011; 30(3): E4. doi: 10.3171/2010.12.FOCUS10277.
- Abiola R, Rubery P, Mesfin A. Ossification of the Posterior Longitudinal Ligament: Etiology, Diagnosis, and Outcomes of Nonoperative and Operative Management: (2015) *Global Spine Journal*. 6 (2): 195-204. doi:10.1055/s-0035-1556580 - Pubmed.
- Choi BW, Song KJ, Chang H. Ossification of the posterior longitudinal ligament: a review of literature. *Asian Spine J*. 2011;5 (4): 267-76. doi:10.4184/asj.2011.5.4.267 - Free text at pubmed - Pubmed citation.
- Smith ZA, Buchanan CC, Raphael D et-al. Ossification of the posterior longitudinal ligament: pathogenesis, management, and current surgical approaches. A review. *Neurosurg Focus*. 2011;30 (3): E10. doi:10.3171/2011.1.FOCUS10256 - Pubmed citation
- Kalb S, Martirosyan NL, Perez-Orribo L et-al. Analysis of demographics, risk factors, clinical presentation, and surgical treatment modalities for the ossified posterior longitudinal ligament. *Neurosurg Focus*. 2011;30 (3): E11. doi:10.3171/2010.12.FOCUS10265 - Pubmed citation
- Epstein N. Diagnosis and surgical management of cervical ossification of the posterior longitudinal ligament. *Spine J*. 2003;2 (6): 436-49. Pubmed citation
- Sato R, Uchida K, Kobayashi S, Yayama T, Kokubo Y, Nakajima H, Takamura T, Bangirana A, Itoh H, Baba H. Ossification of the posterior longitudinal ligament of the cervical spine: histopathological findings around the calcification and ossification front *Journal of Neurosurgery: Spine*, August 2007 / Vol. 7 / No. 2 : Pages 174-183
- Hirai T, Korogi Y, Yamashita Y et-al. Ossification of posterior longitudinal ligaments: evaluation with MRI. *J Magn Reson Imaging*. 1998;8 (2): 398-405. Pubmed citation
- Tuskimoto H. An autopsy case with spinal cord compression syndrome owing to ossification within spinal canal of cervical spine (in Japanese). *J Jap Orthop Assoc*. 196; 34: 107.
- Terashima K, Maruyama S, Miyashita R. Ossification of the posterior longitudinal ligament of the cervical spine [In Japanese]. *Orthop Surg*. 1964; 15: 1081-1095
- Ross JS. *Diagnostic Imaging Spine*. Salt Lake City, UT, USA: Amirsys; 2004: II276-II288.
- Okada E, Matsumoto M, Fujiwara H, Toyama Y. Disc degeneration of cervical spine on MRI in patients with lumbar disc herniation: Comparison study with asymptomatic volunteers. *Eur Spine J*. 2011; 20(4): 585-591.
- Yang HS, Chen DY, Lu XH, et al. Choice of surgical approach for ossification of the posterior longitudinal ligament in combination with cervical disc hernia. *Eur Spine J*. 2010; 19(3): 494- 501.
- Hori T, Kawaguchi Y, Kimura T. How does the ossification area of the posterior longitudinal ligament thicken following cervical laminoplasty? *Spine (Phila Pa 1976)*. 2007; 32(19): E551-E556. doi: 10.1097/BRS.0b013e31814614f3