



SIGNIFICANCE OF INDIVIDUALISED HOMOEOPATHIC MEDICINE IN A CASE OF NON-HEALING SCALP WOUND ALONG WITH STANDARD MANAGEMENT IN MODERATE HAEMOPHILIA B PATIENT: A CASE REPORT.

Kumat Omkar¹, Kalda Prapti², Kundu Tapas*³, Binaykiya Swarda², Kundu Rita⁴.

¹Communication Consultant, Homoeopathy in Haemophilia.

²Volunteer, Homoeopathy In Haemophilia.

³PI-Homoeopathy in Haemophilia, Prof. & HOD of Medicine, Motiwala (National) Homoeopathic, Medical College, Nashik, Maharashtra, India.

⁴Prof. & HOD of Physiology, Motiwala (National) Homoeopathic Medical College, Nashik, Maharashtra, India.

Abstract: This article is an evidence-based case report to explore the role of individualized homoeopathic medicine as an adjuvant therapy along with standard management used in a case of non-healing scalp wound in a moderate haemophilia B patient. Add on homoeopathic medicines when prescribed on an individual basis lessens the suffering and hastens the recovery.

Index Terms - Haemophilia B, Individualised Homoeopathic medicine, Non-healing wound, Standard management, Case Report.

I. INTRODUCTION

Introduction:

Wound healing comprises several physiological mechanisms including coagulation, inflammation, formation of granulation tissue, and tissue remodeling. Coagulation with robust thrombin generation leading to fibrin formation is necessary for wound healing¹. The mechanism of wound healing is delayed due to many factors which affect these series of interactions. One such factor is the deficiency of the clotting factors. Haemophilia is a disease with a deficiency of clotting factor VIII (Haemophilia A) or factor IX (Haemophilia B). Histologically, the inundation of neutrophils and monocytosis is delayed and reduced in Haemophilia B^{2, 3}. Patients with haemophilia have remarkably reduced ability to produce thrombin to form a stable hemostatic plug⁴. We here report one such case of non-healing scalp injury in haemophilia B patient treated using homoeopathic medicines along with standard management.

Case Report:

An 8-year-old boy (K/C/O: Haemophilia B, 5 %) came with a complaint of a single, non-healing wound, irregular in shape, over the occipital region of the scalp following an injury after a fall on a cooking gas burner dated 18/05/2021.

History of presenting complaints:

After injury patient applied Hamamelis Virginica Q on the wound with his previous experience but the bleeding did not stop. Arnica Montana 30CH, Calendula officinalis 30CH, and Mercurius solubilis 30CH were the telephonic prescription based on acute totality. Also patient tried many home remedies which had worsened the wound rather than curing it. When the bleeding did not stop the patient was admitted to the civil hospital and factor infusion therapy was given. After discharge from the hospital, wound healing was still not accomplished. Almost 45 days after the injury, the patient visited HIH center Nashik on 01/07/2021.

Examination of wound (01/07/2021):

A partially healed wound with oozing bloody discharge along with unhealthy scab formation was seen on wound examination.

Family Genetic History of Haemophilia:

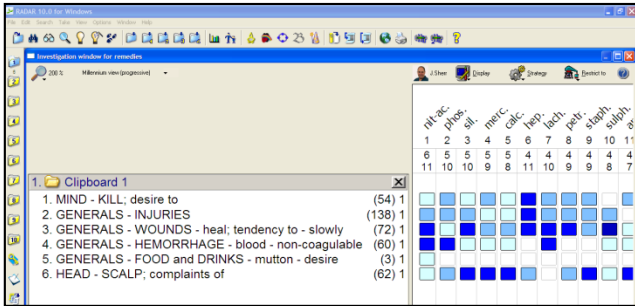
Maternal uncle is a Patient with Haemophilia (PWH), and Mother is a haemophilia carrier

Advice:

Factor infusion as per the requirement. The patient was advised to keep a close observation on changes occurring in the wound during treatment and to inform the physician accordingly. In case of any emergency, the patient was advised to get admitted to the hospital.

Repertorial totality: Fig.no. 1

- MIND - KILL; desire to
- GENERALS - INJURIES
- GENERALS - WOUNDS - heal; tendency to - slowly
- GENERALS - HEMORRHAGE - blood - non-coagulable
- GENERALS - FOOD and DRINKS - mutton - desire
- HEAD - SCALP; complaints of



Follow-ups and outcomes: Table no. 1

Follow up Date	18/05/2021	23/05/2021	28/05/2021	03/06/2021
Presenting complaints	A single, severely painful, non-healing scalp wound was present.	Admitted to the civil hospital due to persistent oozing of blood from the wound.	CT scan was done on 26/05/2021 – Normal. But bleeding from the wound was persistent	The patient got discharged from the civil hospital.
Discharges/odor	Oozing of frank blood from the site of injury.	Oozing of purulent discharge along with blood from the wound was present because of the usage of home remedies.	Oozing of blood was persistent from the wound.	Discharges stopped, and scab formation started.
Homoeopathic treatment	1) Arnica montana 30 CH/1 dram in globule no 30/ 4pills 5 times/ every 15 minutes – on day of injury followed by TDS for next 5 days 2) Hamamelis Virginica Q for Local application.	Arnica montana 30 CH/1 dram in globule no 30/ 4pills TDS for 10 days.	The patient continued same the prescription.	Calendula 30 CH / 1 dram/ 4 pills TDS x 15 days.
Standard treatment	Factor – not taken because of non-availability of transport services.	Patient infused factor 1200 I/U.	Patient infused factor 1800 I/U	Factor infusion was not required.

Follow-ups and outcomes: Table no. 1 (Continued)

Follow up Date	19/06/2021	01/07/2021	14/07/2021	07/08/2021
Presenting complaints	The patient scratched the wound and bleeding resumed.	The patient visited the HIH center in Nashik. Oozing of blood along with unhealthy scab formation was seen.	Oozing of blood from the wound stopped within 24 hours of prescription. But a huge scab was still present.	The scab fell with minimal and linear scar formation.
Discharges/odor	Oozing of blood started after scratching	Oozing of bloody discharge.	No discharges.	No discharges.
Homoeopathic treatment	Mercurius Solubilis 30CH/4pills x 1 hourly 3 times a day/ Then SOS.	1) Nitricum Acidum 30 CH / 3 doses / 24 hourly. 2) Sac lac 30/ 2 dram/ 4-4 daily.	1) Nitricum Acidum 200/ 1Dose-stat. 2) Thiosinaminum 30 CH/ 1 dram / 4-4 x 15days to start from 15/07/2021	Nihilinum 200 CH / 1 dram / 4-4 x 7 days
Standard treatment	Factor infusion 250 I/U	-	-	-

Collection of photographs Telephonically and in OPD: Table no. 2

18/05/2021 (Telephonic)	19/06/2021 (Telephonic)	26/06/2021 (Telephonic)
		
01/07/2021 (OPD)	14/07/2021 (Telephonic)	07/08/2021 (OPD)
		

Discussion:

Haemophilia B is an inherited bleeding disorder where hemostasis is affected and the blood coagulation cascade is altered. Hemostasis is a physiological mechanism that leads to the cessation of bleeding from the blood vessel⁵. A healthy wound healing involves hemostasis as a fundamental phase and is subsequently followed by the inflammatory, proliferative, and tissue remodeling or resolution phase⁶.

After the injury, the damaged blood vessels contract rapidly and form a blood clot preventing exsanguination from vascular damage. Platelets are the principal contributors to hemostasis and coagulation and are activated when they encounter the vascular subendothelial matrix. Platelet receptors like glycoprotein VI interact with extracellular matrix (ECM) proteins (eg. fibronectin, collagen, and von Willebrand factor), promoting adherence to the blood vessel wall. Thrombin subsequently triggers platelet activation, inducing a conformation change and release of alpha and dense granules containing bioactive molecules which reinforce coagulation. An insoluble clot (eschar) of fibrin, fibronectin, vitronectin, and thrombospondin forms, primarily serving to plug the wound and prevent bleeding^{7,8,9& 10}.

Here is a case of a moderate haemophilia B with a non-healing scalp wound leading to an unhealthy scab formation caused due to fall on a cooking gas burner. According to the level I protocol and from previous experience patient applied Hamamelis Virginica Q (mother tincture) locally at the site of injury from the emergency kit of homoeopathic thrombostatic medicines and Arnica Montana 30CH orally was prescribed telephonically to manage the emergency¹¹ bleeding. Factor infusion was advised on the day of injury but was not possible due to the non-availability of transport services. Meanwhile, the patient

tried various home remedies to stop the bleeding but this, in turn, worsened the wound rather than curing it. Bleeding from the wound did not stop so the patient got admitted to a civil hospital for 11 days and infused factor. After Arnica Montana 30CH, Calendula officinalis 30CH and Mercurius Solubilis 30CH were also prescribed telephonically on the acute totality but these did not yield a significant result which indicates that level II protocol also failed in this case. After 45 days of injury, the patient visited HH center Nashik. After the examination of the wound and conspicuously observing the patient's personality Nitricum Acidum 30CH was prescribed as an individualised¹² homeopathic medicine, level III protocol (Fig.no.1). Within 24 hours of prescription, the oozing of blood stopped but the scab was still present. Thiosinaminum 30CH was prescribed to complement the action of Nitricum Acidum, for the elimination of scab, and for resolving the scar tissue. Thiosinaminum showed striking improvement in healing of a complicated wound by eliminating the scab and minimizing the scar tissue formation, restoring the cosmetic value as desired by the patient. Homeopathic software RADAR- 10.5¹³ was used for Repertorization.

From this case, it was concluded that homeopathic medicines prescribed according to the level protocol I and II does not always help in treating the patient, but on the contrary when prescribed on the principles of homeopathy that is level III protocol (individualization) always gives the desired results within the period. However, contradicting the process of delayed wound healing which is commonly characterized by the formation of hypertrophic scar^{14,15}, this particular patient developed a minimal and linear scar which was truly possible after prescribing individualized homeopathic medicine alone. As shown in tables no.1 & 2 there was a marked improvement seen in the wound healing in terms of shape, size, edges, discharge, odor, and pain. The patient was assessed using Modified Naranjo Criteria in Homeopathy¹⁵ (MONARCH) based on 10 domains with a score of 10 out of 13.

Conclusion:

Homeopathic medicines prescribed on the basis of level protocol I and II did not show much result in this particular case, but when prescribed on the principles of homeopathy (individualization) that is level III protocol showed desired results. Injury to the haemophilia patients are a common incidence and therefore a larger multicentric trial for injury management with a fair number of cases following level III protocol is warranted.

Patient's perspective:

The patient was relieved from his sufferings and was very satisfied as well as the scar formed was minimal and linear got concealed within the hair restoring the cosmetic value with homeopathic treatment.

Conflict of Interest:

None to declare.

Informed consent:

Written informed consent was obtained for the publication of photographs and data for scientific purposes.

References:

1. Monroe, D., Mackman, N. and Hoffman, M., 2022. *Wound healing in hemophilia B mice and low tissue factor mice*.
2. Hoffman, M., 2009. The Influence of Hemophilia on Wound Healing. *Blood*, 114(22), pp.SCI-21-SCI-21.
3. Hoffman, M., Harger, A., Lenkowski, A., Hedner, U., Roberts, H. and Monroe, D., 2022. *Cutaneous wound healing is impaired in hemophilia B*.
4. Hoffman M, Monroe Dr. A cell-based model of hemostasis. *ThrombHaemost* 2001; 85: 958-65.
5. LaPelusa A, Dave H. Physiology, Hemostasis [Internet]. Statpearls.com. 2022 [cited 19 June 2022]. Available from: <https://www.statpearls.com/ArticleLibrary/viewarticle/32760>
6. Gonzalez, Ana Cristina de Oliveira et al. Wound healing - A literature review* * Work conducted at the Gonçalo Moniz Research Center – Fundação Oswaldo Cruz (CPqGM/Fiocruz), Salvador, BA, Brazil. . *Anais Brasileiros de Dermatologia* [online]. 2016, v. 91, n. 5 [Accessed 19 June 2022] , pp. 614-620. Available from: <<https://doi.org/10.1590/abd1806-4841.20164741>>. ISSN 1806-4841. <https://doi.org/10.1590/abd1806-4841.20164741>.
7. Wilkinson H, Hardman M. Wound healing: cellular mechanisms and pathological outcomes. *Open Biology*. 2020;10(9):200223.
8. Golebiewska EM, Poole AW. 2015Platelet secretion: from haemostasis to wound healing and beyond. *Blood Rev*. 29, 153-162. (doi:10.1016/j.blre.2014.10.003) Crossref, PubMed, ISI, Google Scholar
9. Zaidi A, Green L. 2019Physiology of haemostasis. *Anaesth. Intensive Care Med*. 20, 152-158. (doi:10.1016/j.mpaic.2019.01.005) Crossref, ISI, Google Scholar
10. Wilkinson H, Hardman M. Wound healing: cellular mechanisms and pathological outcomes. *Open Biology*. 2020;10(9):200223.
11. Kundu T, Shaik T, Singh P, Sheikh A, Kumat O, et al. (2015) Management of Acute Bleeding in Severe Haemophilia Using Homeopathic Medicines: a Multicentric Case Series. *J HomeopAyurv Med* 4: 180. doi:10.4172/2167-1206.1000180.
12. Hahnemann S. Organon of medicine. 6thedn. New Delhi: B. Jain Publications, LPE 2002, 38th Impression, Pg. No. 195 and 196. Aphorism 118 and 119.
13. RADAR (2021) 10.5-open the homeopathic software. Jain publishers, India.
14. Bailey, Hamilton, Robert John McNeill Love, R.C.G. Russell, N.S. Williams, and C.J.K. Bulstrode. *Bailey & Love's Short Practice of Surgery*. - 23rd Ed. International Student ed. Pg. no. 36-38, Arnold, 2000.
15. Dey N, Dey T. *A Text Book of Pathology*: N.C. Dey, T.K. Dey, Debasish Sinha. 15th ed. New Central Book Agency, 2003; 1995.
16. Lamba C, Gupta V, Haselen R, Rutten L, et al. Evaluation of the Modified Naranjo Criteria for assessing causal attribution of clinical outcome to Homeopathic intervention as presented in case reports. 2019.