



# ***STREPTOCOCCUS SUIIS* MENINGITIS IN INFANT**

<sup>1</sup>Kajal Chavan, <sup>2</sup>Anil Gaikwad, <sup>3</sup>Jyoti Iravane, <sup>4</sup>Dhaval Khatri

<sup>1</sup>Resident Doctor, <sup>2</sup>Associate Professor, <sup>3</sup>Professor and Head of Department, <sup>4</sup>Research Scientist

<sup>1</sup>Department of Microbiology,

<sup>1</sup>Government Medical College, Aurangabad, Maharashtra State, India

**Abstract:** *Streptococcus suis* is a zoonoses and it mainly resides in the upper respiratory tract of pigs. People in close proximity with pigs are at increased risk of infection with this organism. *S. suis* mainly causes septicemia and meningitis. This case report deals with the case of a 2-month-old female newborn, who developed signs of meningitis. *S. suis* was isolated from CSF. Patient showed improvement after starting empirical antibiotic therapy.

**Index Terms - Meningitis, *Streptococcus suis*, Zoonotic disease.**

## **I. INTRODUCTION**

*Streptococcus suis* is a gram-positive coccus with a capsule. The organism is facultative anaerobe [1,2,3] and is responsible for zoonotic disease in men. Individuals in close proximity with pigs such as farmers, abattoir workers, slaughter house workers or who consume undercooked pork are at the risk of developing infection [4,5]. This infection commonly causes meningitis, septicemia and endocarditis [1,3,6]. Permanent deafness and dysfunction of the vestibule are prevailing complication following *S. suis* infection, especially meningitis [1,4,6,7]. Other clinical manifestations are arthritis, endophthalmitis, uveitis, pneumonia, spondylodiscitis, septic shock [1,4,5,7,8].

The first case of *S. suis* infection in humans was reported in Denmark in the year 1968 [1,4]. There were two epidemics of human *S. suis*. One was of serotype 2 in China in the year 1998 and second one was in the year 2005 [2]. Southeast Asia region has highest prevalence of infection where there is high pork consumption [1,6]. First occurrence of *S.suis* infection in India was in the year 2015 in chronic osteomyelitis case [5].

## **II. CASE HISTORY**

2 months old female child, previously healthy, was brought by relative with chief complaints of fever and loose stools for 4 days, 3-4 episodes of vomiting for 2 days and failure to thrive. Baby had no significant medical history or past NICU admission. After 2 days of admission in ward, patient became drowsy, irritable, did not accept feed and showed signs of respiratory distress with respiratory rate 80rpm.

Routine laboratory test showed 15,500 leucocytes/ $\mu$ l of blood with 50% neutrophils; 165,000 platelets/ $\mu$ l; haemoglobin 13.3g/dl; and increased CRP. Blood was drawn for blood culture. Cerebrospinal fluid (CSF) was collected by lumbar puncture. CSF analysis showed an increased protein content of 90mg/dl and glucose content was decreased to 29mg/dl. CSF gram staining was showing very few gram-positive cocci in pairs. Acid-fast staining showed absence of acid-fast bacilli, KOH mount and India ink preparation were negative for fungal elements. Provisional report of gram staining was informed to resident and patient was put on empirical antibiotic therapy with ampicillin and gentamycin. Computed tomography scan of brain showed no abnormal findings. Blood culture was negative after 48 hours of incubation but CSF culture after 24 hours of incubation showed small colonies on blood agar which were  $\alpha$ -hemolytic (Fig. 1). Gram staining was showing gram positive cocci in pairs and short chains (Fig. 2) and they were catalase test negative (Fig. 3), Voges-Proskauer test negative and fermented glucose. Antimicrobial susceptibility testing showed that the isolate was resistant to optochin but sensitive to penicillin, clindamycin, ceftriaxone, linezolid, levofloxacin, ciprofloxacin (Fig. 4). This isolate was identified as *S. suis* by VITEK-2 Gram positive card system (bioMerieux). Patient showed improvement after completion of 14 days course of antibiotic therapy with ampicillin and gentamycin.

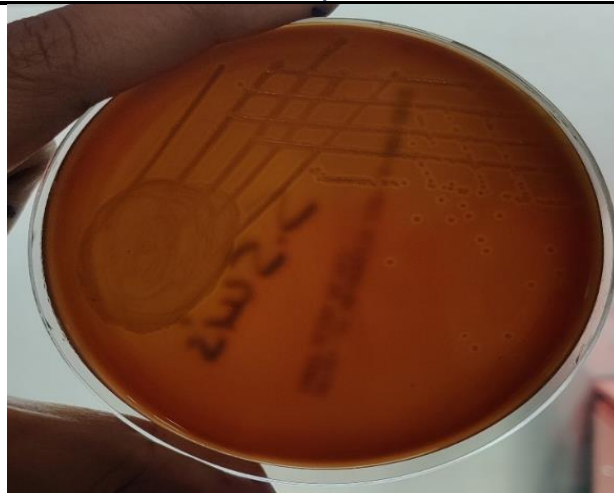

Figure 1: Colonies of *S. suis* on 5% sheep blood agar showing  $\alpha$ - hemolytic colonies

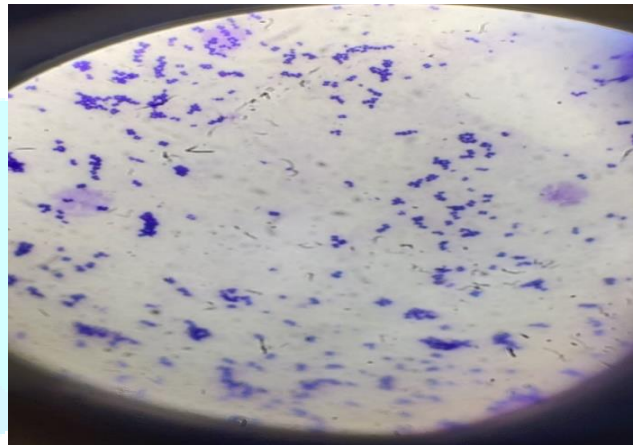


Figure 2: Gram staining showing gram positive cocci in pairs and short chains



Figure 3: Negative catalase test

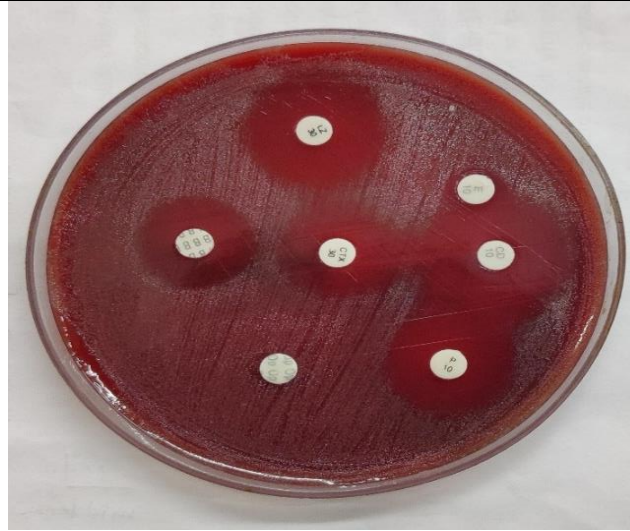

Figure 4: Antimicrobial susceptibility testing showing that the isolate was resistant to optochin.

### III. DISCUSSION

*S. suis* is a gram-positive coccus which is facultatively anaerobic. Although human is contracts infection through contact with contaminated pigs or pork [1] but exposure to pigs is not universal in *S. suis* infection [6]. Diarrhoea was found in some patient probably due to oral route of transmission. *S. suis* affects adult males more with a mean age range of 37 to 63 years [4,6]. But infection is not limited to adults only, it affects children also [3]. Higher cases are found during summer or rainy season [6,9].

In our case, patient is new-born child with 2months of age. Patient had indirect contact with pigs. Father of patient was working in slaughter house and mother used to visit that workplace almost daily with patient. Other clinical and microbiological results were similar to those reported elsewhere.

*S. suis* infection is often under diagnosed or misdiagnosed due to unawareness and therefore there are a smaller number of cases. Patients with risk factors, showing lab results in favour of *S. suis*, should receive treatment with penicillin or other antimicrobials to which organism is susceptible as early as possible to minimise the complications like deafness.

No vaccine against *S. suis* is currently available. All are still under trial. Therefore, in such a scenario, the best way to control is to prevent disease transmission. Infection can be prevented by increasing public awareness about infection, wearing gloves and mask while handling pork, treating abrasions promptly, following hand washing techniques, sufficiently cooking pork products, educating both clinicians and exposed groups.

### IV. ACKNOWLEDGMENT: NONE

### V. REFERENCES

- [1] Choi SM, Cho BH, Choi KH, Nam TS, Kim JT, Park MS, Kim BC, Kim MK, Cho KH, et al. Meningitis caused by *Streptococcus suis*: case report and review of the literature. *J Clin Neurol*. 2012 Mar;8(1):79-82. doi: 10.3988/jcn.2012.8.1.79. Epub 2012 Mar 31. PMID: 22523518; PMCID: PMC3325437.
- [2] Feng Y, Zhang H, Wu Z, Wang S, Cao M, Hu D, Wang C, et al. *Streptococcus suis* infection: an emerging/reemerging challenge of bacterial infectious diseases? *Virulence*. 2014 May 15;5(4):477-97. doi: 10.4161/viru.28595. Epub 2014 Mar 25. PMID: 24667807; PMCID: PMC4063810.
- [3] Prince-David M, Salou M, Marois-Créhan C, Assogba K, Plainvert C, Balogou KA, Poyart C, Tazi A, et al. Human meningitis due to *Streptococcus suis* in Lomé, Togo: a case report. *BMC Infect Dis*. 2016 Nov 8;16(1):651. doi: 10.1186/s12879-016-2006-0. PMID: 27821092; PMCID: PMC5100305.
- [4] Lee GT, Chiu CY, Haller BL, Denn PM, Hall CS, Gerberding JL. *Streptococcus suis* meningitis, United States. *Emerg Infect Dis*. 2008 Jan;14(1):183-5. doi: 10.3201/eid1401.070930. PMID: 18258107; PMCID: PMC2600143.
- [5] Zhu Y, Zhu F, Bo L, Fang Y, Shan X. A rare case of meningitis and septicemia caused by *Streptococcus suis* in a woman without a history of live pig contact or eating raw pork. *Braz J Microbiol*. 2021 Dec;52(4):2007-2012. doi: 10.1007/s42770-021-00619-8. Epub 2021 Sep 24. PMID: 34559387; PMCID: PMC8460845.
- [6] Rayanakorn A, Goh BH, Lee LH, Khan TM, Saokaew S. Risk factors for *Streptococcus suis* infection: A systematic review and meta-analysis. *Sci Rep*. 2018 Sep 6;8(1):13358. doi: 10.1038/s41598-018-31598-w. PMID: 30190575; PMCID: PMC6127304.
- [7] Sena Esteves S, Carvalho de Almeida J, Abrunhosa J, Almeida E Sousa C, Arshad Q. *Pig's ear: Streptococcus suis* Meningitis and its associated inner ear implications. *IDCases*. 2017 Aug 30;10:55-57. doi: 10.1016/j.idcr.2017.08.015. PMID: 28932685; PMCID: PMC5596260.
- [8] Mohapatra D, Sarangi G, Patro P, Paty BP, Chayani N, Mohanty DP. Chronic Osteomyelitis Due to *Streptococcus suis*: First Case Report from India. *J Glob Infect Dis*. 2015 Apr-Jun;7(2):92-3. doi: 10.4103/0974-777X.154449. PMID: 26069434; PMCID: PMC4448336.
- [9] Wertheim HF, Nguyen HN, Taylor W, Lien TT, Ngo HT, Nguyen TQ, Nguyen BN, Nguyen HH, Nguyen HM, Nguyen CT, Dao TT, Nguyen TV, Fox A, Farrar J, Schultsz C, Nguyen HD, Nguyen KV, Horby P, et al. *Streptococcus suis*, an important cause of adult bacterial meningitis in northern Vietnam. *PLoS One*. 2009 Jun 22;4(6):e5973. doi: 10.1371/journal.pone.0005973. PMID: 19543404; PMCID: PMC2696092.
- [10] Hay PE, Cunniffe JG, Kramer G, France AJ, Gray JA, Watt B. Two cases of *Streptococcus suis* meningitis. *Br J Ind Med*. 1989 May;46(5):352-3. doi: 10.1136/oem.46.5.352. PMID: 2751936; PMCID: PMC1009781.
- [11] Susilawathi NM, Tarini NMA, Fatmawati NND, Mayura PIB, Suryapraba AAA, Subrata M, Sudewi AAR, Mahardika GN, et al. *Streptococcus suis*-Associated Meningitis, Bali, Indonesia, 2014-2017. *Emerg Infect Dis*. 2019 Dec;25(12):2235-2242. doi: 10.3201/eid2512.181709. PMID: 31742523; PMCID: PMC6874276.