



# Mitral Valve Aneurysm: An Uncommon Complication of Infective Endocarditis: A Case Report

B. Mesmoudi<sup>1</sup>, R. Jennane<sup>1</sup>, F. J. Nguadi<sup>2</sup>, N. Doghmi<sup>1</sup>, M. Cherti<sup>1</sup>

1. Department of Cardiology, Maternity Souissi, Ibn Sina Teaching Hospital University Mohammed V of Rabat

2. Department of Cardiology, Military Hospital Mohammed V of Rabat, University Mohammed V of Rabat

## **Abstract :**

Mitral valve aneurysm (MVA), is an alarming complication of infective endocarditis (IE), with worse outcomes seen among patients with preexisting valvular disease or intravenous drug use.<sup>1</sup>

Other causes of this disorder are rheumatic heart disease, Marfan's syndrome, aortic regurgitation and hypertrophic cardiomyopathy. The complications of MVA include expansion, perforation and severe valvular regurgitation. An early diagnosis followed by surgical treatment is of critical importance to reduce the rate of these complications.<sup>2</sup>

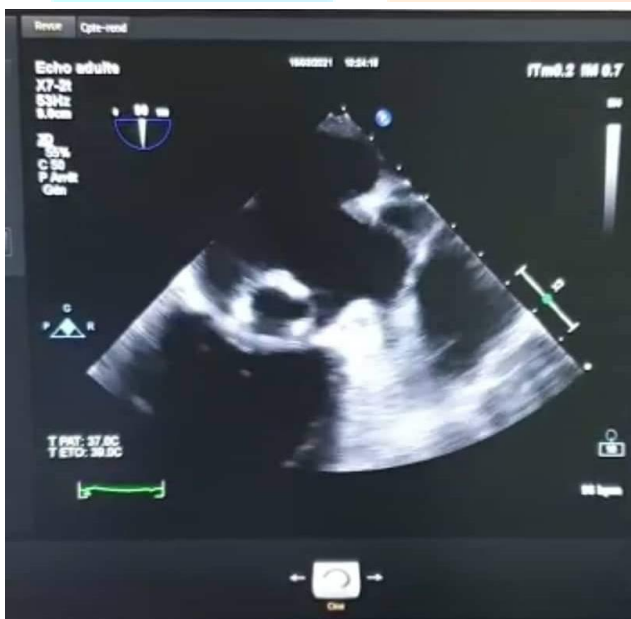
We present an aneurysm of the posterior mitral leaflet in a woman who presented with a severe mitral regurgitation (MR) in the context of infective endocarditis.

## **Introduction :**

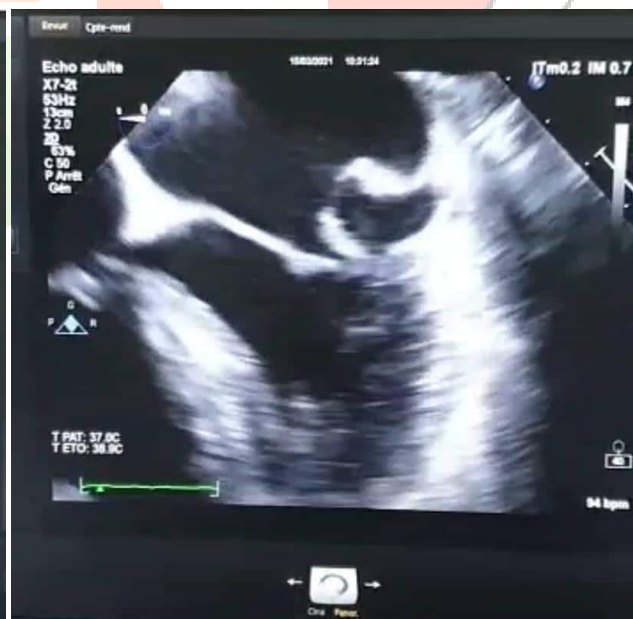Mitral valve aneurysm (MVA) is uncommon and reported cases are rare and often the consequence of infective endocarditis<sup>3</sup>. Their prevalence is 0.2–0.29% of the transthoracic echocardiography studies,<sup>4,5</sup> and they are most frequently seen in association with IE of the aortic valve<sup>6</sup>. An MVA is defined as a localized bulge of the mitral leaflet toward the left atrium with systolic expansion and diastolic collapse<sup>7</sup>. The mechanism of the aneurysm evolution is not clearly established. The diagnosis of MVA relies on a recognition of changes in clinical status and repeat echocardiography. Mitral valve repair or replacement is indicated when aneurysm is ruptured or when the unruptured aneurysm is large or accompanied by significant regurgitation.<sup>3</sup> We present the case of a 60-year-old woman with diabetes mellitus, who was admitted for a heart failure attack, in whom we found a severe mitral insufficiency with infective endocarditis, complicated by an aneurysm of the posterior mitral leaflet.

### **Case report :**

We report the case of a 60 year old patient, diabetic on insulin, with no history of rheumatic fever, dental care or recent transfusions or toxic habits, presenting to the cardiological consultation with a NYHA stage IV dyspnea. She reported a notion of heaviness of the left hemisphere and fever 3 months ago, treated with protected amoxicillin by a general physician. The evolution was marked by the occurrence of a dyspnea stage III-IV of the NYHA, with increase of the volume of the lower limbs. The clinical examination found a polypneic patient, with global cardiac failure, with a mitral insufficiency murmur on cardiac auscultation, Osler's nodules on the fingers and toes, as well as a dry necrosis of the fifth finger of the left hand. The EKG showed sinus tachycardia, with left anterior hemiblock and the chest X-ray a V3 cardiomegaly. The transthoracic echocardiography was equivocal for valvular vegetation on the mitral valve with a mobile element measuring 8 mm at the level of the atrial side of the the posterior leaflet with severe mitral insufficiency by prolapse of P1-P2, and the presence of an aneurysmal sac at the level of the posterior mitral leaflet. We completed by a transesophageal echocardiography which confirmed the aneurysm of the posterior mitral leaflet (Figure 1A), and revealed the presence of a filiform element at the non-coronal cusp of the aortic valve and two filiform elements on the atrial side of the mitral valve, with a P2 prolapse (Figure 1B).



***Figure 1A: Transesophageal echocardiography image showing the aneurysm of the posterior mitral leaflet***



***Figure 1B: Transesophageal echocardiography image showing the P2 prolapse of the mitral valve***

The definite diagnosis of infective endocarditis was retained on the basis of 1 major and 3 minor criteria: predisposing cardiac damage, i.e. mitral insufficiency, vascular phenomena, i.e. a major arterial embolism, and immunological phenomena such as Osler nodules. The patient was put on antibiotic therapy for infective endocarditis and was referred to surgeons for mitral surgery. The patient underwent a mitral plasty.

### **Discussion :**

MVA is a rare entity usually associated with aortic valve (AV) endocarditis. Among other complications, they bear a high risk of perforation with subsequent acute severe MR. The first case of MVA was reported by Morand in 1729<sup>8</sup>. MVAs are rarely encountered in patients without endocarditis. Sporadic cases are reported in association with particular conditions, such as connective tissue diseases (e.g., Marfan syndrome, Ehlers-Danlos syndrome, pseudoxanthoma elasticum, and osteogenesis imperfecta), extreme forms of MV prolapse (e.g., MVP), congenital cardiac structural defects, or Libman-Sacks endocarditis<sup>9,10</sup>. Untreated MVA can lead to severe mitral regurgitation and acute pulmonary edema through multiple mechanisms, including perforation of the aneurysm and rupture of the chordae tendineae<sup>11,12</sup>. Moreover, MVA may cause a mass effect, leading to coaptation defect of the leaflets. Another serious complication of MVA is thrombus formation within the saccular bulge, with high risk of embolism and spreading of infection<sup>13</sup>.

Diagnosis can be made by transthoracic echocardiography but transesophageal echocardiography is more sensitive and accurate. Echocardiography shows MVA as a localized saccular bulge of the leaflet toward the left atrium and communication between the aneurysm and the left ventricle during the cardiac cycle<sup>3,14,15</sup>. Anterior MVAs are more common than posterior MVAs. The differential diagnosis of MVA includes mitral valve pseudo aneurysms (MVP), myxomatous degeneration of the MV, flail mitral leaflet, chordal rupture, papillary fibroelastoma, atrial myxoma involving the MV, blood cyst of the papillary muscle, and anterior MV diverticulum<sup>16,17</sup>. MVP, can be distinguished from MVA by the diffuse leaflet thickening, the protrusion of the leaflet tip into the left atrium during systole, and the absence of a discrete neck<sup>18</sup>.

No definite indications for treatment of MVAs exist. Surgery should definitely be considered in case of perforation or rupture, with severe MR and signs of heart failure. It might also be considered if concomitant evidence of uncontrolled infection is present<sup>19,20</sup>. Conservation may be possible for small ones, but close follow-up is needed<sup>3</sup>. The decision of whether to perform surgery or to conservatively follow up a patient should rely on the dimension of the MVA and clinical status of the patient.

MV repair, primarily or using synthetic or pericardial patch, in the setting of IE has been shown to have better clinical in-hospital and long-term results as compared to MV replacement<sup>21,22</sup>. Prosthetic valve replacement may be considered in patients unsuitable for repair or with persistent MR following repair. The best time for surgery is unclear. Early surgery for IE has been advocated in general. A period of antibiotic therapy before surgery can prevent possible extra-valvular involvement. Simplifying operations is an important benefit of presurgical antibiotic therapy<sup>13</sup>.

### **Conclusion:**

MVA is considered as a rare complication of IE that can lead to severe morbidity and mortality when not diagnosed early and managed quickly. Early intervention may prevent perforation of a MVA aneurysm and acute heart failure. Treatment is generally surgical; however, small and uncomplicated aneurysms can be managed with a conservative strategy with a close follow-up.

### **References :**

1. Samuel J. Apple, Benjamin Ramalanjaona, Pramod Theetha Kariyanna, and Isabel M. McFarlane. Mitral Valve Aneurysm in Mitral Valve Endocarditis: A Case Report. *Am J Med Case Rep.* 2020; 8(3): 83–87. Published online 2020 Jan 19.
2. Takao Konishi, Naohiro Funayama, Tadashi Yamamoto, and al : Severe mitral regurgitation due to mitral leaflet aneurysm diagnosed by three-dimensional transesophageal echocardiography: a case report. *BMC Cardiovasc Disord.* 2016; 16: 234. Published online 2016 Nov 22. doi: 10.1186/s12872-016-0413-1.
3. Changqing Gao, MD, Cansong Xiao, MD, and Bojun Li. Mitral Valve Aneurysm With Infective Endocarditis: The Annals of Thoracic Surgery. CASE REPORT, VOLUME 78, ISSUE 6, P2171-2173, DECEMBER 01, 2004.
4. Vilacosta I, San Roman JA, Sarria C et al. Clinical, anatomic, and echocardiographic characteristics of aneurysms of the mitral valve. *Am J Cardiol* 1999;84:110–13, A9 10.1016/S0002-9149(99)00206-4 [[PubMed](#)] [[CrossRef](#)] [[Google Scholar](#)]
5. Guler A, Karabay CY, Gursoy OM et al. Clinical and echocardiographic evaluation of mitral valve aneurysms: a retrospective, single center study. *Int J Cardiovasc Imaging* 2014;30:535–41. 10.1007/s10554-014-0365-4 [[PubMed](#)] [[CrossRef](#)] [[Google Scholar](#)]
6. Shoko Uematsu, Kyomi Ashihara, Hideyuki Tomioka, and Atsushi Takagi: Large mitral valve aneurysm with infective endocarditis. *BMJ Case Rep.* 2015; 2015: bcr2014209092. Published online 2015 Apr 15. doi: 10.1136/bcr-2014-209092.
7. Ruckel A, Erbel R, Henkel B, Kramer G, Meyer J. Mitral valve aneurysm revealed by cross-sectional echocardiography in a patient with mitral valve prolapse. *Int J Cardiol* 1984;6:633–7.
8. Jarcho S. Aneurysm of heart valves. *Am J Cardiol.* 1968;v22:273–76. [[PubMed](#)] [[Google Scholar](#)]
9. Guler A, Karabay C, Gursoy O, et al. Clinical and echocardiographic evaluation of mitral valve aneurysms: A retrospective, single center study. *Int J Cardiovasc Imaging.* 2014;30:535–41. [[PubMed](#)] [[Google Scholar](#)]
10. Lebwohl MG, Distefano D, Prioleau PG, et al. Pseudo-xanthoma elasticum and mitral-valve prolapse. *N Engl J Med.* 1982;307:228–31. [[PubMed](#)] [[Google Scholar](#)]
11. Rachko M, Sa AM, Yeshou D et al.: Anterior mitral valve aneurysm: A subaortic complication of aortic valve endocarditis: A case report and review of literature. *Heart Disease.* 2001; 3: 145–47. [[PubMed](#)] [[Google Scholar](#)]

12. Gurbuz AS, Ozturk S, Efe SC, Kilicgedik A, Acar E, Karabay CY, Guler A, Kirma C. Perforation of anterior mitral leaflet aneurysm: A rare cause of severe mitral regurgitation. *The Egyptian Heart Journal*. 2016. June 1; 68(2): 131–3. [[Google Scholar](#)]
13. Martina Moretti, Angelo Buscaglia, Jacopo Senes and al : Anterior Mitral Valve Aneurysm Is an Uncommon Complication of Aortic Valve Infective Endocarditis: A Case Report..Am J Case Rep. 2018; 19: 1146–1151. Published online 2018 Sep 28. doi: 10.12659/AJCR.909922.
14. Vilacosta I, San Roman JA, Sarria C, et al. Clinical, anatomic, and echocardiographic characteristics of aneurysms of the mitral valve. *Am J Cardiol* 1999;84:110 –3
15. Shakudo M, Eng AK, Applegate PM, et al. Visualization of mitral valve aneurysm by transesophageal echocardiography. *Echocardiography* 1990;7:551–4.
16. Guler A, Karabay CY, Gursoy OM, et al. Clinical and echocardiographic evaluation of mitral valve aneurysms: A retrospective, single center study. *Int J Cardiovasc Imaging*. 2014;30:535–41. [[PubMed](#)] [[Google Scholar](#)]
17. Stechert MM, Pletcher JR, Tseng EE, et al. Echo rounds: Aneurysm of the anterior mitral valve. *Anesth Analg*. 2012;114(1):86–88. [[PubMed](#)] [[Google Scholar](#)]
18. Goldberg L, Mekel J, Grigorov V. Echocardiographic features of extreme mitral valve prolapse vs. mitral valve aneurysm. *Cardiovasc J S Afr*. 2002;13(2):73–77. [[PubMed](#)] [[Google Scholar](#)]
19. Gin KG, Boone JA, Thompson CR, et al. Conservative management of mitral valve aneurysm. *J Am Soc Echocardiogr*. 1993;6:613–18. [[PubMed](#)] [[Google Scholar](#)]
20. Habib G, Lancellotti P, Antunes MJ, et al. 2015 ESC Guidelines for the management of infective endocarditis: The Task Force for the Management of Infective Endocarditis of the European Society of Cardiology (ESC). Endorsed by: European Association for Cardio-Thoracic Surgery (EACTS), the European Association of Nuclear Medicine (EANM) *Eur Heart J*. 2015;36(44):3075–28. [[PubMed](#)] [[Google Scholar](#)]
21. Feringa HH, Shaw LJ, Poldermans D, et al. Mitral valve repair and replacement in endocarditis: A systematic review of literature. *Ann Thorac Surg*. 2007;83:564–70. [[PubMed](#)] [[Google Scholar](#)]
22. Schwalm SA, Sugeng L, Raman J, et al. Assessment of mitral valve leaflet perforation as a result of infective endocarditis by 3-dimensional real-time echocardiography. *J Am Soc Echocardiogr*. 2004;17:919–22. [[PubMed](#)] [[Google Scholar](#)]