



INTERNATIONAL JOURNAL OF CREATIVE RESEARCH THOUGHTS (IJCRT)

An International Open Access, Peer-reviewed, Refereed Journal

GLOBAL THREAT OF LUMPY VIRUS AND TREATMENT

¹Pruthviraj K Chaudhary, ¹Dr Hitesh D Karen, ²Viral A Prajapati and ³Dr Dhrubo Jyoti Sen

¹Shri Sarvajani Pharmacy College, Gujarat Technological University, Arvind Baug, Mehsana-384001, Gujarat, India.

²K.B. Institute of Pharmaceutical Education and Research (KBIPER), Sector-23, Near GH-6, Gandhinagar-382023 Gujarat, India.

³School of Pharmacy, Techno India University, Sector-V, Salt Lake City, EM-4/1, Kolkata-700091, West Bengal, India.

Abstract: Lumpy skin disease (LSD, Pseudo-urticaria, Neethling virus disease, exanthema nodularis bovis, and knopvelsiekte) is an infectious disease. It is caused by a virus (LSDV) in the family Poxviridae, genus Capripoxvirus. It is closely related antigenically to sheep and goat pox virus. However, these viruses cannot be differentiated using routine serological test (Alexander et al 1957). LSD is a disease of cattle and water buffalo. It is a vector-borne disease transmitted by different biting and biting blood feeding arthropods. LSDV replicates inside the host cells such as macrophages, fibroblasts, pericytes and endothelial cell in the lymphatics and blood vessels walls lead to developing vasculitis and lymphangitis, while thrombosis and infarction may developed in severe cases. Viraemia occurred after the initial febrile reaction and persisted for two weeks. In natural infection, very young calves, lactating cows, and malnourished animals seem to develop more severe disease that may be due to an impaired humoral immunity. The transmission of LSD is not completely understood. The main two routes of transmission are mechanical transmission by arthropod vectors such as mosquitoes, ticks and biting flies and the movement of infected animals. The disease can also be spread by fomites through such things as contaminated equipment and in some cases directly from animal to animal. The disease has shown its ability to establish and spread in a wide range of environmental and productions systems around the world.

Keywords: History of Lumpy, Skin disease (LSD), Immunity, Pathogenesis, Structure of LSD, Treatment of LSD, Clinical signs and symptoms of LSD, Precaution (control) of LSD.

Introduction: Lumpy skin disease (LSD, Pseudo-urticaria, Neethling virus disease, exanthema nodularis bovis, and knopvelsiekte) is an infectious disease. It is caused by a virus (LSDV) in the family Poxviridae, genus Capripoxvirus. It is closely related antigenically to sheep and goat pox virus. However, these viruses cannot be differentiated using routine serological test (Alexander et al 1957). LSD is a disease of cattle and water buffalo. It is a vector-borne disease transmitted by different biting and biting blood feeding arthropods. LSD Causes considerable economic losses due to emaciation, damage to hides, infertility, mastitis, loss of milk production, and mortality of up to 20%. The severity of clinical signs of LSD depends on the strain of capripoxvirus and the host cattle breed (Anonymous 1988). Until 1989, Lumpy skin disease is limited to African continent. However, the disease is moved outside Africa to Madagascar and the Middle East and causes serious economic loss to the livestock industry. The incubation period in the field is believed to be two to five weeks, and lesions first appear at the inoculation site in 4 to 20 days.^[1]

The Causative Organism: The genus Capripoxvirus of the family Poxviridae is the causative agent of Lumpy skin disease. Lumpy skin disease virus (LSDV) is closely related antigenically to sheep and goat poxviruses (Woods 1988). Although these three viruses are distinct, they cannot be differentiated with routine serological tests (Figure 1). The infected tissue culture fluid can be stored at 4°C for 6 months. The virus is susceptible to highly alkaline or acid pH. However, there is no significant reduction in titre when held at pH 6.6–8.6 for 5 days at 37°C. LSDV is susceptible to ether (20%), chloroform, formalin (1%), and some detergents, e.g. sodium dodecyl sulphate.

In addition, it is also susceptible to phenol (2% /15 minutes), sodium hypochlorite (2–3%), iodine compounds (1:33 dilution), Virkon® (2%) and quarternary ammonium compounds (0.5%). LSDV has remarkably stable, surviving for

long periods at ambient temperature, especially in dried scabs. The colinearity is disrupted and poxvirus homologues are either absent or share a lower percentage of amino acid identity (average of 43%) in the terminal regions. Although LSDV resembles leporipoxviruses in gene content and organization, it also contains homologues of interleukin-10 (IL-10), IL-1 binding proteins, G protein-coupled CC chemokine receptor, and epidermal growth factor-like protein which are found in other poxvirus genera. LSDV is closely related to other members of the Chordopoxvirinae, it contains a unique complement of genes responsible for viral host range and virulence.^[2]

History of lumpy skin disease: The first description of the clinical signs of LSD was in 1929 in Zambia (formerly Northern Rhodesia) (Morris 1931). In the beginning, LSD signs were considered to be the consequence either of poisoning or a hypersensitivity to insect bites. Same clinical signs were occurred in Botswana, Zimbabwe and the Republic of South Africa between 1943 and 1945, where the infectious nature of the disease was recognized in these outbreaks. In South Africa, LSD occurred as a panzootic, which affected eight million cattle. The disease continuous until 1949, and generate massive economic losses (Thomas and Mare 1945; Von Backstrom, 1945; Diesel, 1949). In 1957, LSD was identified in East Africa in Kenya. In 1972, the disease was reported in Sudan (Ali and Obeid 1977).^[3]

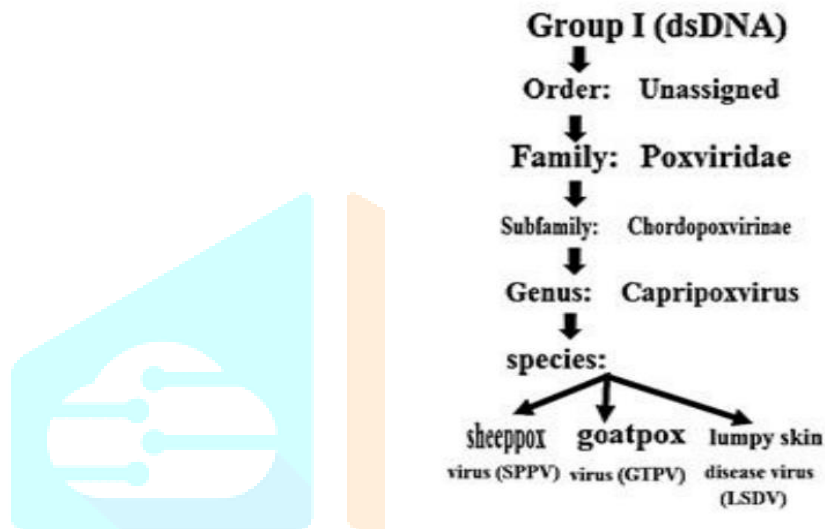


Figure-1: Classification of Lumpy skin disease virus

In Egypt, Suez Governorate, the LSD was reported in May 1988 (Ali et al 1990). The disease was arrived in Egypt with cattle imported from-Africa and kept at the local quarantine station. It spread locally in the summer of 1988 and apparently overwintered with little or no manifestation of clinical disease. Twenty-two out of twenty-six Egyptian governorates were affected with diseases, then the disease reappeared in the summer of 1989 and continuous for five to six months. This epizootic showed low morbidity rate (2%) due to the vaccination procedure that included nearly two million cattle with a sheep pox vaccine. However, approximately 1449 animals died. In the summer of 2006, in one farm with a total of 30 cases in dairy cows. LSD outbreak was re-emerged once again in several Egyptian governorates, where all age groups and both sex of Egyptian cattle were infected with severe and serious complications. In Iran, the LSD considered as emerging disease that has been identified for the first time in 2014. Figure (2)

Bangladesh: LSD was first reported to the Bangladesh Department of Livestock Services in July 2019. Eventually 500,000 head are estimated to have been infected in this outbreak. The United Nations Food and Agriculture Organization has recommended mass vaccination. As a result of the introduction of fall armyworm and this cattle plague within a few months of each other, the FAO, the World Food Programme, Bangladesh Government officials, and others agreed to begin improving Bangladesh's livestock disease surveillance and emergency response capabilities.^[4]

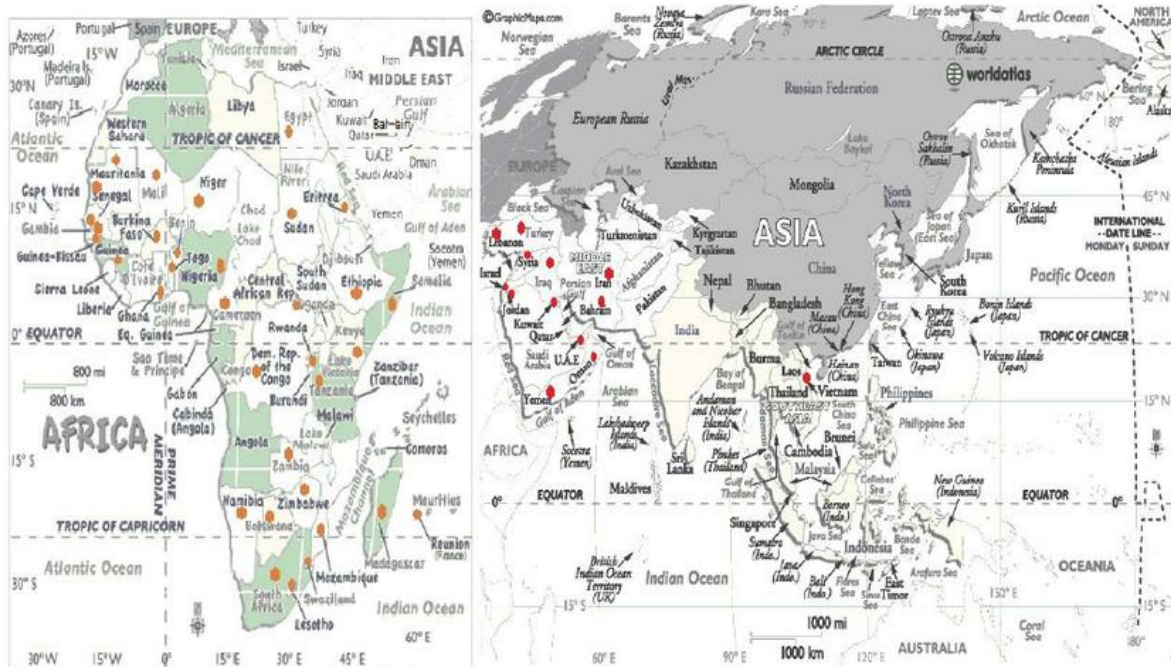


Figure-2: Map of Lumpy skin disease distribution (The red dots show the emergence foci of the disease)

India: In July 2022, the outbreak spread in 14 out of 33 districts of Gujarat state of India. By 25 July, more than 37000 cases and 1000 deaths in cattle were reported.^[5]

Pathogenesis: Intravenous, intradermal and subcutaneous routes are used in experimental infection. The intravenous route develops severe generalized infection, while the intraepidermal inoculation develops only 40% to 50% of animals may developed localized lesions or no apparent disease at all. A localized swelling at the site of inoculation after four to seven days and enlargement of the regional lymph nodes, develop after subcutaneous or intradermal inoculation of cattle with LSDV (Vorster and Mapham 2008). However, generalized eruption of skin nodules usually occurs seven to 19 days after inoculation. LSDV replicates inside the host cells such as macrophages, fibroblasts, pericytes and endothelial cell in the lymphatics and blood vessels walls lead to developing vasculitis and lymphangitis, while thrombosis and infarction may developed in severe cases. Viraemia occurred after the initial febrile reaction and persisted for two weeks. In natural infection, very young calves, lactating cows, and malnourished animals seem to develop more severe disease that may be due to an impaired humoral immunity.^[6]

Clinical signs and symptoms:

1. The clinical signs of LSD have two febrile phases (biphasic fever), which is appeared after variant incubation period 4-12 days (usually 7 days). The temperature of the infected animals raises to 40-41.5°C, which may persist for 6-72 h or more and may rarely be up to 10 days.
2. The infected animals also show lacrimation, increased nasal and pharyngeal secretions, anorexia, dysgalactia, general depression and a disinclination to move.
3. Multiple firm circumscribed nodules are developed in the skin of the animals. These nodules are suddenly erupted within 1-2 days. Respiratory, mouth, pharyngeal, and ocular lesions prolong the period of anorexia and recovery. Deterioration in the general condition occurs in the severely affected animals and under range conditions the mortality can be high.
4. The erupted nodules may be widespread or restricted to just a few lesions.
5. The head, neck, the perineum, the genitalia, udder, and the limbs are the predilection sites. The whole of the skin of the infected animal is covered with lesions infrequent cases. Typical LSD lesions are round, irregular, about 5-50 mm in diameter, and appear as circumscribed areas of erect hair over a firm and slightly raised area of skin (Figure 3).

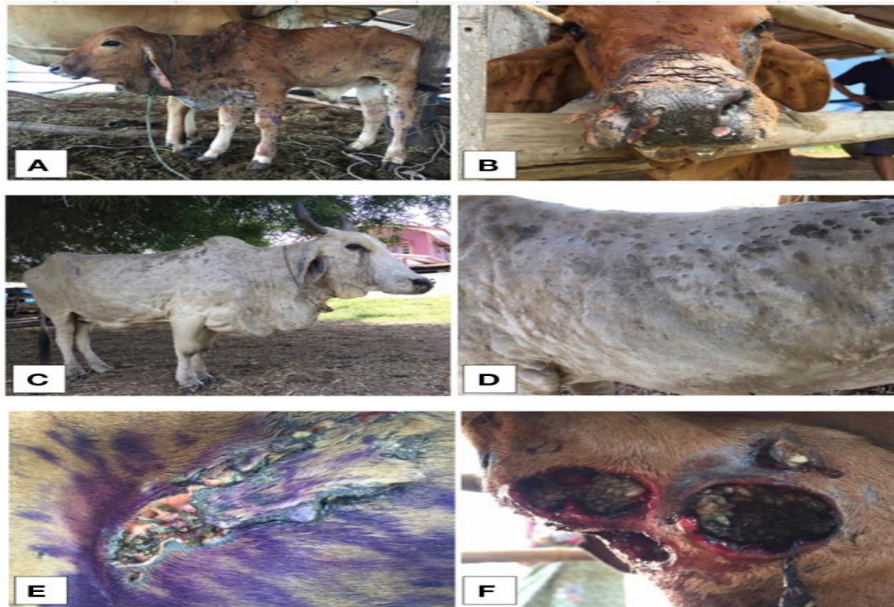


Figure-3: Cow infected with LSD reveals multiple skin nodules

Structure: Like other viruses in the *Poxviridae* family, capripoxviruses are brick-shaped. Capripoxvirus virions are different than orthopoxvirus virions in that they have a more oval profile, as well as larger lateral bodies. The average size of capripoxvirions is 320 nm by 260 nm.

Genome: The virus has a 151-kbp genome, consisting of a central coding region which is bounded by identical 2.4 kbp-inverted terminal repeats and contains 156 genes. There are 146 conserved genes when comparing LSDV with chordopoxviruses of other genera. These genes encode proteins which are involved in transcription and mRNA biogenesis, nucleotide metabolism, DNA replication, protein processing, virion structure and assembly, and viral virulence and host range. Within the central genomic region, LSDV genes share a high degree of collinearity and amino acid identity with the genes of other mammalian poxviruses. Examples of viruses with similar amino acid identity include suipoxvirus, yatapoxvirus, and leporipoxvirus. Unique to Chordopoxviridae, LSDV contains homologues of interleukin-10 (IL-10), IL-1 binding proteins, G protein-coupled CC chemokine receptor, and epidermal growth factor-like protein, which are found in other poxvirus genera.^[7]

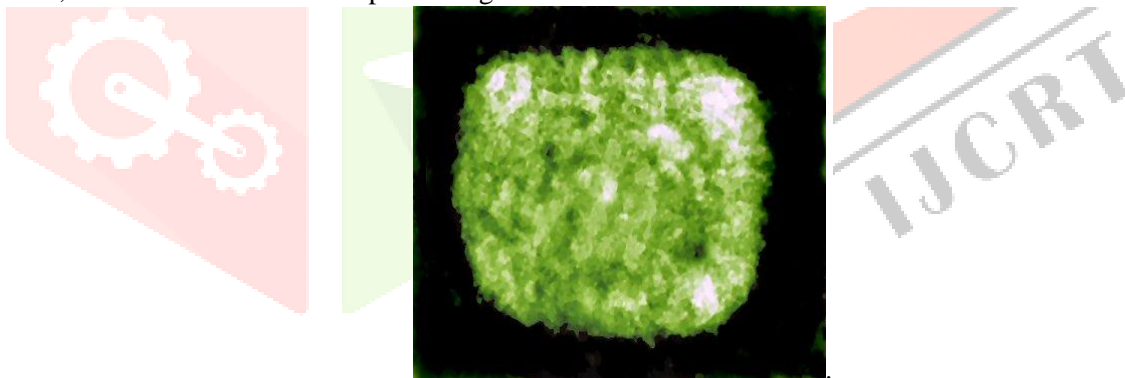


Figure-4: Structure of capripoxviruses

Transmission: Outbreaks of LSDV are associated with high temperature and high humidity. It is usually more prevalent during the wet summer and autumn months, especially in low-lying areas or near bodies of water, however, outbreaks can also occur during the dry season. Blood-feeding insects such as mosquitos and flies act as mechanical vectors to spread the disease. A single species vector has not been identified. Instead, the virus has been isolated from *Stomoxys*, *Biomyia fasciata*, Tabanidae, *Glossina*, and *Culicoides* species. The particular role of each of these insects in the transmission of LSDV continues to be evaluated. Outbreaks of lumpy skin disease tend to be sporadic since they are dependent upon animal movements, immune status and wind and rainfall patterns, which affect the vector populations. The virus can be transmitted through blood, nasal discharge, lacrimal secretions, semen and saliva. The disease can also be transmitted through infected milk to suckling calves. In experimentally infected cattle, LSDV was found in saliva 11 days after the development of fever, in semen after 22 days, and in skin nodules after 33 days. The virus is not found in urine or stool. Like other pox viruses, which are known to be highly resistant, LSDV can remain viable in infected tissue for more than 120 days.^[8]

IMMUNITY:

Artificial immunity: There have been two different approaches to immunization against LSDV. In South Africa, the Neethling strain of the virus was first attenuated by 20 passages on the chorio-allantoic membranes of hens' eggs. Now the vaccine virus is propagated in cell culture. In Kenya, the vaccine produced from sheep or goatpox viruses has been shown to provide immunity in cattle. However, the level of attenuation required for safe use in sheep and goats is not sufficient for cattle. For this reason the sheeppox and goatpox vaccines are restricted to countries where sheeppox or goatpox is already endemic since the live vaccines could provide a source of infection for the susceptible sheep and goat populations. In order to ensure adequate protection against LSDV, susceptible adult cattle should be vaccinated annually. Approximately, 50% of cattle develop swelling (10–20 millimetres ($\frac{1}{2}$ – $\frac{3}{4}$ in) in diameter) at the site of inoculation. This swelling disappears within a few weeks. Upon inoculation, dairy cows may also exhibit a temporary decrease in milk production.

Natural immunity: Most cattle develop lifelong immunity after recovery from a natural infection. Additionally, calves of immune cows acquire maternal antibody and are resistant to clinical disease until about 6 months of age.

To avoid interference with maternal antibodies, calves under 6 months of age whose dams were naturally infected or vaccinated should not be vaccinated. On the other hand, calves born from susceptible cows are also susceptible and should be vaccinated.^[9]

Diagnosis of LSD:**A confirmative diagnosis of LSD can be based upon the:**

- Laboratory investigations and identification of the agent based on (OIE Terrestrial Manual 2010; OIE 2013):
A. Isolation of the virus: Confirmation of lumpy skin disease in a new area requires virus isolation and identification. Samples for virus isolation should be collected within the first week of the occurrence of clinical signs, before the development of neutralising antibodies (Davies 1991; Davies et al 1971). Skin biopsies of early lesions (ones where necrosis has not occurred) provide samples that can be used for virus isolation and electron microscopy. In addition, LSD virus can be isolated from buffy coat from the blood sample collected into EDTA or heparin during the viraemic stage of LSD. Samples should be taken from at least three animals. Samples aspirated from enlarged lymph nodes can be also used for virus isolation. LSD virus grows in tissue culture of bovine, ovine or caprine origin. Bovine dermis cells or lamb testis (LT) cells (Primary or secondary culture), are considered to be the most susceptible cells.

LSD capripoxvirus have been also adapted to grow on the chorioallantoic membrane of embryonated chicken eggs and African green monkey kidney (Vero) cells, which is not recommended for primary isolation (OIE Terrestrial Manual 2010).

- B. Electron microscopy:** Transmission electron microscopic (TEM) diagnosis of LSD can be confirmed within a few hours of receipt of specimens. TEM demonstration of virus in negatively stained preparations of biopsy specimens taken from affected skin or mucous membranes. Mature capripox virions have an average size 320 x 260 nm and are a more oval profile and larger lateral bodies than orthopox virions (OIE Terrestrial Manual 2010).^[10]

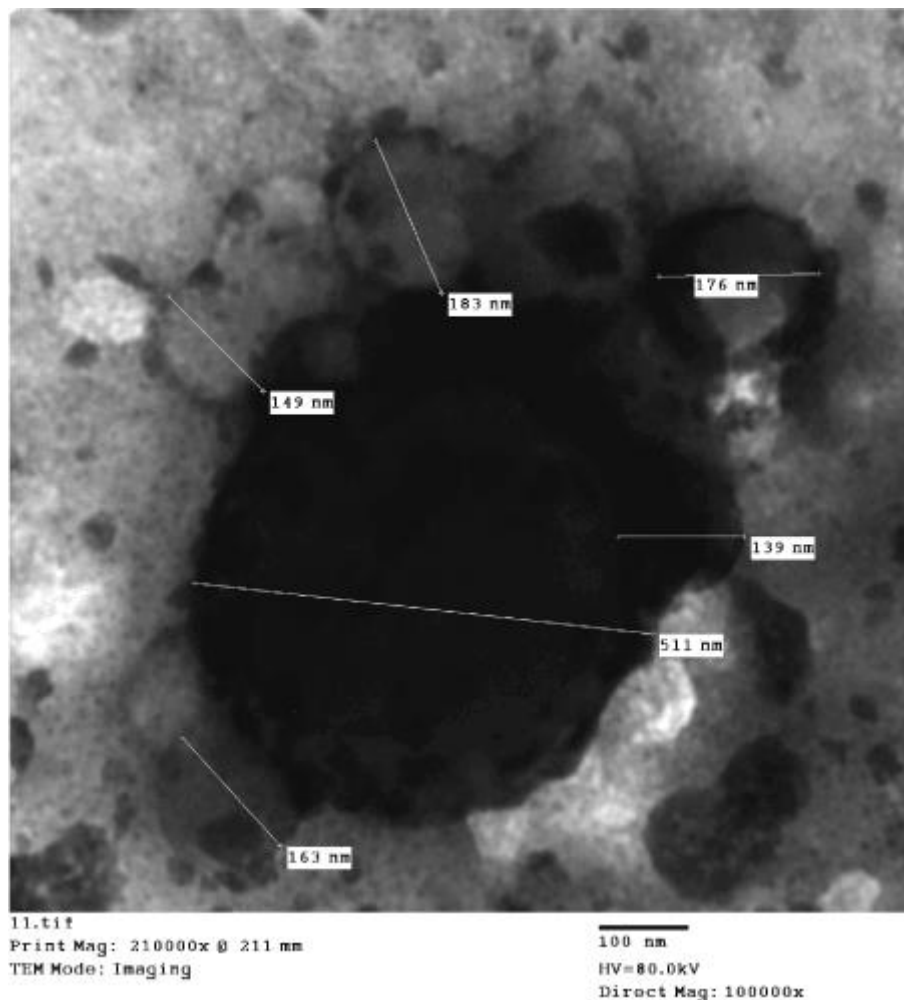


Figure-5: Human LSDV infections, skin lesion vesicular exudates showing, brick-shape virions [139-183nm in diameter]. These viral particles aggregates around an electron dense larger molecule [511 nm, width], and showing the M form and the textured surface structure of non-enveloped particle outer membrane. (Negative Staining, TEM).

C. Fluorescent antibody tests: Capripoxvirus antigen can also be identified on the infected cover-slips or tissue culture slides using fluorescent antibody tests.

D. Agar gel immunodiffusion: An agar gel immunodiffusion (AGID) test has been used for detecting the precipitating antigen of capripoxvirus, but has the disadvantage that this antigen is shared by parapoxvirus.

E. Enzyme-linked immunosorbent assay: It is made by using expressed recombinant antigen to produce P32 monospecific polyclonal antiserum and the production of monoclonal antibodies (MAbs) (Carn, et al 1994).

F. Polymerase chain reaction (PCR) and loop-mediated isothermal amplification (LAMP) assay have been used for detection of capripoxviruses with higher sensitivity. (Bowden et al 2009; Balinsky et al 2008).

• **Serology:** Frozen sera from both acute and convalescent animals are used. Virus neutralisation (cross reacts with all capripoxviruses) and indirect fluorescent antibody test (cross reaction with parapoxviruses) are commonly used. Enzyme-linked immunosorbent assay for the detection of antibodies against capripox virus has been developed using the expressed structural P32 protein (Carn et al., 1994; Heine et al 1999). Agar gel immunodiffusion tests (This test may give false-positive reactions due to cross reaction with bovine papular stomatitis virus and pseudocowpox virus). Western blot analysis provides a sensitive and specific system for the detection of antibody to capripoxvirus structural proteins, although the test is expensive and difficult to carry out.^[11]

Differential diagnosis: There are many diseases causing similar signs of LSD. It is important to obtain a definite diagnosis to ensure the best preventative and control measures for susceptible herds. LSD can be confused with the following diseases:

- Pseudo-lumpy-skin disease
- Bovine virus diarrhoea/mucosal disease
- Demodicosis (Demodex)
- Bovine malignant catarrhal fever (Snotsiekte)
- Rinderpest
- Besnoitiosis
- Oncocercariasis
- Insect bite allergies

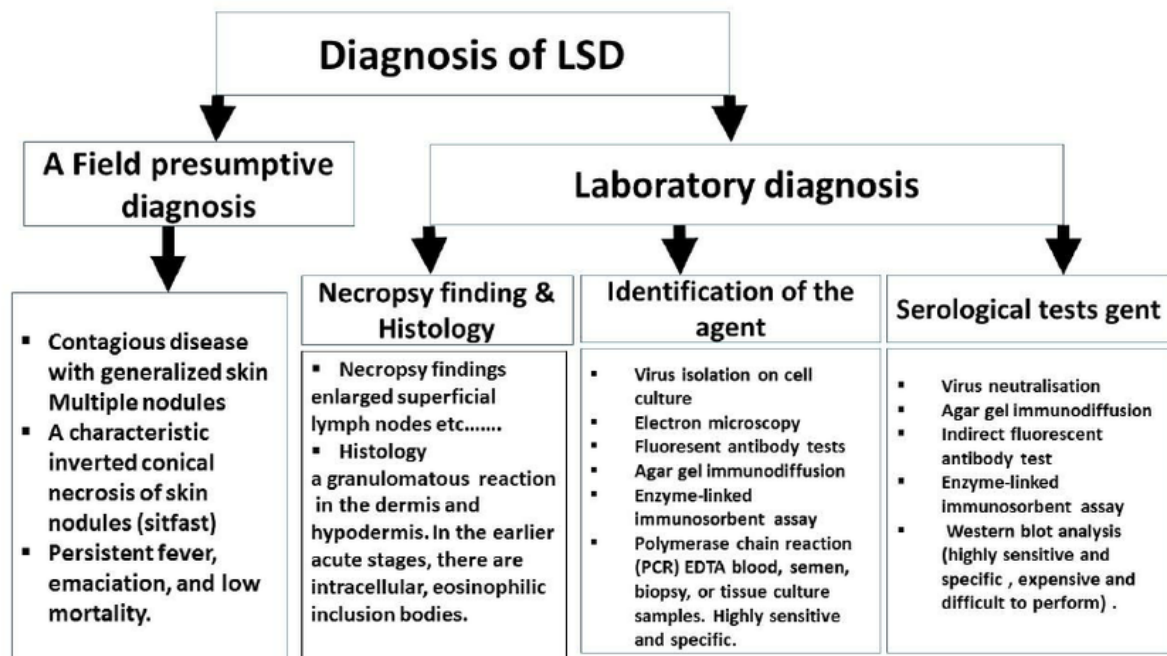


Figure-6: The diagnostic procedures of the LSD

Treatment: Lumpy skin disease is caused by virus and, therefore, has no known cure. However, antibiotics, anti-inflammatory drugs or a shot of vitamins are used in some cases to treat secondary bacterial infections or to deal with fever or inflammation and improvement of the animal's appetite.

Precaution (control) of LSD: Control of Lumpy skin disease by quarantine and movement control is not very effective because biting flies and certain tick species are most probably the most important method of transmission of the disease. Although, the control of insects was not effective in preventing the spread of LSD, but use of insecticides together with repellents can be an aid in the prevention of the spread of LSD. LSD outbreaks can be eradicated by quarantines, depopulation of infected and exposed animals, proper disposal of carcasses, cleaning and disinfection of the premises and insect control. LSD control can only be by vaccination or immunoprophylaxis. Live vaccines help control losses from lumpy skin disease in endemic areas. According to OIE, four live attenuated strains of capripoxvirus have been used as vaccines specifically for the control of LSD (Brenner et al, 2006; Capstick & Coakley 1961 & 1962; Carn et al., 1994). These are: a strain of Kenyan sheep and goat pox virus passaged 18 times in lamb testis (LT) cells or fetal calf muscle cells, Yugoslavian RM 65 sheep pox strain, Romanian sheep pox strain and lumpy skin disease virus strain from South Africa, passaged 60 times in lamb kidney cells and 20 times on the chorioallantoic membrane of embryonated chicken eggs.^[12]

The following vaccines have been used in protection of the animal:

- Homologous live attenuated virus vaccine (Neethling strain: immunity conferred lasts up to 3 years).
- Heterologous live attenuated virus vaccine (Sheep or goat pox vaccine, but may cause local, sometimes severe reactions). This vaccine is not advised in countries free from sheep and goat pox because the live vaccines could otherwise provide a source of infection for the susceptible sheep and goat populations.
- There is no new generation recombinant capripox vaccines are commercially available.

Results: LSDVh was successfully isolated from blood and skin nodules collected from infected persons. Confirmed diagnosis was achieved by the conventional PCR and sequencing procedures. The isolates were genetically characterized as Lumpy skin disease virus isolate Evros/GR/15 by partial sequence with 99 % identity. Meanwhile, LSDV virions and herpes virus particles were visualized by electron microscopic investigations (NS-DEM). The majority of LSD virions were non-enveloped showing Mulberry forms and some capsular form, and the enveloped forms. Herpes virus virions were also detected in large number, the enveloped and the non- enveloped. The apparent pathogenesis on infected human are comparatively similar to LSD in cattle however the progress of illness and stages of the disease depends on level of health care interventions. Unless the nature of human biology is greatly different from that of cattle.

Conclusions: Lumpy skin disease virus is capable of infecting humans with direct transmission without the need for insect's vector; that most probably by inhalation and certainly by the direct contacts with infected materials, infected persons [man to man], and as laboratory acquired infection. LSDVh causes skin nodules and may lead to death in cases of generalized infections and if involving the internal organs. However, it is obvious that Herpes virus gives hands and helping poxviruses during their pathogenesis in the infected subjects.

REFERENCES:

1. Alexander RA, Plowright W and Haig DA. (1957). Cytopathogenic agents associated with lumpy-skin disease of cattle. *Bull. Epiz. Dis. Afr.* 5:489-492
2. Ali Meawad Ahmed and Amina A. Dessouki. (2013). Abattoir-Based Survey and Histopathological Findings of Lumpy Skin Disease in Cattle at Ismailia Abattoir. *International Journal of Bioscience, Biochemistry and Bioinformatics.* 3(4): 372-375.
3. Ayelet G , Haftu R, Jemberie S, Belay A, Gelaye E, Sibhat B, Skjerve E and Asmare K. (2014). Lumpy skin disease in cattle in central Ethiopia: outbreak investigation and isolation and molecular detection of lumpy skin disease virus *Rev. sci. tech. Off. int. Epiz.* 33 (3), 1-23..
4. Bowden TR, Coupar BE, Babiuk SL, White JR, Boyd V, Duch CJ, Shiell BJ, Ueda N, Parkyn GR, Copps JS, Boyle DB. (2009). Detection of antibodies specific for sheeppox and goatpox viruses using recombinant capripoxvirus antigens in an indirect enzyme-linked immunosorbent assay. *Journal of Virological Methods*, 161(1):19-29. <http://www.sciencedirect.com/science/journal/01660934>
5. Capstick PB, Coackley W. (1961). Protection of cattle against lumpy skin disease. I Trials with a vaccine against Neethling type infection. *Res. Vet. Sci.*, 2:362-368.
6. Capstick PB, Coackley W. (1962). Lumpy Skin disease. The determination of the immune status of cattle by an intra-dermal test. *Res. Vet. Sci.*, 3:287-291.
7. AVIES FG. (1991) b. Lumpy skin disease of cattle: A growing problem in Africa and the Near East. *World Animal Review*, 68, 37 – 42
8. Diesel AM. (1949). The Epizootiology of Lumpy Skin Disease in South Africa. In *Proceedings of the 14th International Veterinary Congress, London, U.K.*, pp.492-500.
9. World Organisation for Animal Health (OIE). (2013). Lumpy skin disease. *Terrestrial Animal Health Code.* OIE, Paris.
10. Samia Ahmed Kamal (2016) In Vitro Study on the Effect of Bee Venom on Some Cell Lines and Lumpy Skin Disease Virus. *Journal of Agricultural Science and Technology* 6: 124-135.
11. Carn VM, Kitching RP (2015) An investigation of possible routes of transmission of lumpy skin disease virus (Neethling). *Epidemiol Infect* 114: 219-226.
12. Weiss KE, (1968). Lumpy skin disease. In: *Virology Monographs*, Vol. 3. Vienna, Austria; New York, USA: Springer-Verlag, 111-131

