



# ORBITAL TUBERCULOSIS: A CASE REPORT

B.Mrini, N. Boutimzine, O. Cherkaoui

Ophthalmology A department, Rabat University Hospital "Hôpital des Spécialités", Rabat, Morocco.

Medical School of Rabat, Mohammed V<sup>th</sup> University, Rabat, Morocco.

## ABSTRACT

Tuberculosis is endemic in Morocco. But even in places where tuberculosis is endemic orbital involvement is rare. It can be hematogenously or by contiguity from a neighboring focus. We report the case of a 39-year-old patient with tumefaction of the upper part of the face whose etiological investigation reveals orbital tuberculosis.

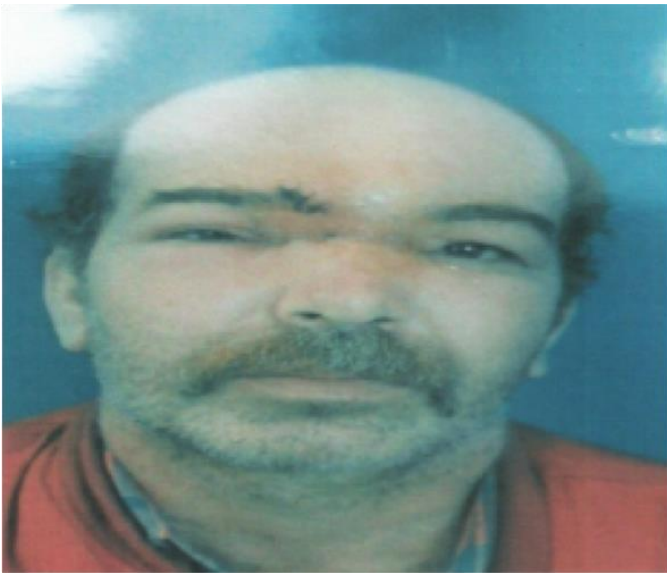**Keywords:** Tuberculosis, orbital, tumefaction.

## INTRODUCTION

Tuberculosis is endemic in Morocco. Orbital tuberculosis is a rare, necrotizing disease caused by mycobacterium tuberculosis. It can affect the different structures of the orbit by 2 mechanisms: hematogenously or by contiguity from a neighboring focus (most often sinus). The positive diagnosis is based on a series of arguments: anamnesis, clinical, radiological, biological, histological, but above all on the search for BK in orbital samples. Treatment involves multidrug therapy for tuberculosis, the only guarantee of a cure. We report a case through which we analyze the different clinical, paraclinical and therapeutic aspects of this condition.

## PATIENTS AND METHODS

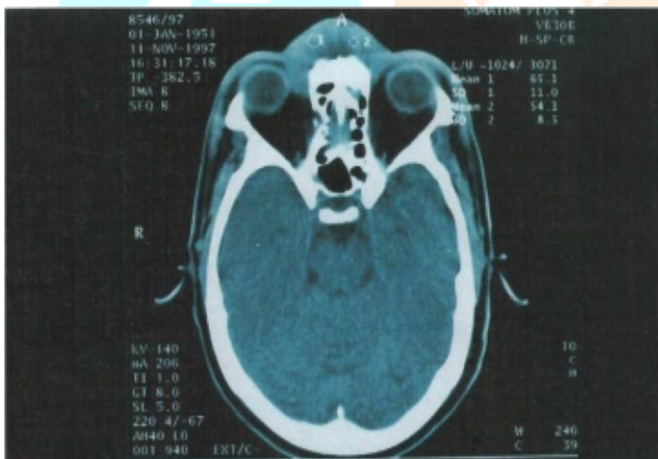
A 39-year-old male patient was referred to our department for ophthalmic evaluation. His chief complaint was swelling of the entire upper part of the face (**figure 1**). The patient gave a history of heaviness and periorbital pain, then appearance of swelling of the glabellar region, eyelids and cheeks, then appearance a few weeks later of multiple fistulas in the internal canthi of the eyelids, giving out a slightly lumpy liquid for the past 4 months. He had an antecedant of pulmonary tuberculosis treated at the age of 20 years with good progress under treatment.



**Figure 1 :** Swelling of the entire upper part of the face.

## RESULTS

On ocular examination, visual acuity was normal and anterior and posterior segment were strictly normal in both eyes. A cerebral and orbital scan was done which showed a process occupying the frontal and maxillary sinuses, with lysis of the internal wall of the frontal sinuses, the glabellar region, the supero anterior part of the cheeks, pushing the eyeballs out, the intraconic space and eyeball are normal (**figure 2**).



**Figure 2 :** Axial section of an orbital scanner without injection of contrast product.

Skin biopsy of the glabellar region was done and direct bacteriological examination was negative but the histological examination showed a dense inflammatory infiltrate system with epitheliogigantocellular granulomas without caseous necrosis.

IDR was strongly positive and VS accelerated. HIV serology was negative. The test for BK in sputum, gastric fluid and urine was also negative.

The diagnosis of osteosinus tuberculosis was made due to the history of pulmonary tuberculosis, the presence of fistulas, the result of the histological study, and the strongly positive IDR.

The patient received the following treatment during 2 months :

- rifampicine 600mg/day
- isoniazide 300mg/day
- pyrazinamide 1500 mg/day
- ethambutol 1200 mg/day
- streptomycine 1g/day

Then he received rifampicin and isoniazid for 10 months.

Evolution was spectacular with almost complete healing clinically and radiologically, but with persistence of sinus mucosa hypertrophy, as well as scar-like tissue in the glabellar region.

## DISCUSSION

Tuberculosis is a necrotizing disease constituting a major cause of mortality and morbidity in developing countries where it is endemic due to lack of hygiene and vaccination.

Orbital localization is rare, in fact only 0.3% of patients with tuberculosis present orbital localization, which occurs in two ways: hematologic or by contiguity from a contiguous focus. In HIV-positive adults, the incidence of tuberculous ocular involvement is high, varying between 50 and 90%, while orbital tuberculous involvement remains extremely rare. (1)

Several clinical forms are described at the orbit level:

- Osteoperiostitis which is the case of our patient.
- Lacrimal gland tuberculoma
- Soft tissue tuberculosis: grouping together damage to oculomotor muscles and orbital fat.

Ophthalmologic involvement of mycobacterium tuberculosis includes: choroiditis, chorioretinitis, choroidal tuberculoma, scleritis, uveitis, retinal vasculitis, optic neuropathy and endophthalmitis. Orbital tuberculous involvement can involve both bone and soft tissue.

In its extraorbital location it can give tuberculosis of the eyeball, lymph node, lung, bone or tuberculous pericarditis. (2)

The diagnosis is based on a set of arguments:

- Anamnestic: notion of contagion, or of another tuberculous localization.
- Clinics: Orbital examination: dacryoadenitis, swelling of the lacrimal compartment, ptosis, abscess of the eyelids, fistulas....

Eye examination: must be systematic in the presence of orbital involvement.

General examination

- Radiological:

Conventional radiology (lungs, eye sockets, blandeau, spine, etc.)

Ocular / orbital ultrasound

Orbital CT

- Blood tests :

As a guideline: VS, CRP, NFS, tuberculin IDR, serodiagnosis.

As an element of certainty: bacteriological and histological examinations

The treatment regimen for orbital tuberculosis is the one for extra-pulmonary tuberculosis which is 2RHZ / 4RH either two months of combination: rifampicin, isoniazid, pyrazinamide and four months of rifampicin and isoniazid (3). In the event of a history of previously treated tuberculosis, the protocol is 2SRHZE / 1RHZE / 5RHE either two months of streptomycin, rifampicin, isoniazid, pyrazinamide, ethambutol and one month of rifampicin, isoniazid, pyrazinamide, ethambutol.

The prognosis is generally good in the absence of intracranial extension or immunosuppression, and in the event of early and well-managed management which allows rapid and complete recovery (3, 4,5). In the event of delayed treatment, sequelae may set in.

## CONCLUSION

The diagnosis of tuberculosis is based on the demonstration of BK. There is a large clinical polymorphism for which tuberculosis should be considered in the face of unexplained inflammation of the orbit. Treatment is based on anti-tuberculosis chemotherapy which allows rapid and complete recovery.

### Conflict of Interest:

None of the authors have any financial interest.

### Funding:

This research did not receive any specific grant from funding agencies in the public, commercial, or not-for-profit sectors.

## REFERENCES:

1. Banait S, Jain J, Parihar PH, Karwassara V. Orbital tuberculosis manifesting as proptosis in an immunocompromised host. Indian J Sex Transm Dis. 2012 Jul-Dec; 33(2): 128- 130. PubMed | Google Scholar
2. Mahender K Narula, Vikas Chaudhary, Dhiraj Baruah, Manoj Kathuria, Rama Anand. Pictorial essay: orbital tuberculosis. Indian J Radiol Imaging. 2010 February; 20(1): 6- 10. PubMed | Google Scholar
3. Jamshidi M, Sadeghi N, Jamshidi A, Eftekhari E. Periorbital tuberculosis in a young man: a case report. Orbit. 2009; 28(2-3):166-8. PubMed | Google Scholar

4. Navneet Tuli. Orbital tuberculosis in childhood with intracranial extension: a case report. *Cases J.* 2010; 3: 38. PubMed | Google Scholar
5. Kaur A, Agrawal A. Orbital tuberculosis: an interesting case report. *Int Ophthalmol.* 2005 Jun; 26(3):107- 9. PubMed | Google Scholar
6. Owoeye JF, Salami AK, Ogundimu KO, Buhari MO. Intraorbital tuberculosis: a case report. *Niger Postgrad Med J.* 2004 Mar;11(1):68-70. PubMed | Google Scholar

