



INTERNATIONAL JOURNAL OF CREATIVE RESEARCH THOUGHTS (IJCRT)

An International Open Access, Peer-reviewed, Refereed Journal

Identification of Sacralization of L5 and Lumbarization of S1 in LS Spine Radiography

Radhe Shyam

Assistant Professor, College of Medical Sciences, IIMT University Meerut.

ABSTRACT

Background: Lumbarization of the first sacral vertebra refers to the segmentation and incorporation of this vertebra into the lumbar spine. Sacralization is the fusion between L5 and the first sacral segment.

Aim: To Identification Sacralization of L5 and Lumbarization of S1 in Ls Spine in plain x-ray.

Methods: Patients are divided into two groups according to sacralization and lumbarization . 120 patients 66 males and 54 females were divided into two groups on the basis of age and gender.

Result: Out of 120 patient, 66 patient were men and 54 were women. Result shows that Lumbarization and Sacralization were found in age group of 20-40 years and they were mostly men. The rest patients have normal back pain and not found any deformity.

Conclusion: It can be concluded that patient of group A age 20-40 years have higher risk of Lumbarization and Sacralization . A total no. of 120 patients in which 38 patients have Lumbarization, 13 patients have sacralization and rest is normal. In the study found that males have higher no. of Lumbarization and Sacralization compare with females.

Keywords : Sacralization, L5, S1, LS, Lumbarization, Spine, Radiography.

Introduction

Lumbarization of S1 and Sacralization of L5 is being performed for many years by many different people for several reasons and thus various methods of data collection for obtaining information for the same are available. This study was carried out on patients undergoing LS Spine examination over 6 months in the radiology department of SGT University.

REVIEW OF LITERATURE

1. Changzhi Yan, Xianda Gao, Yadongsun, Yong Shen carried a study and the study was done in Nov2018. The following is a list of the patients in with adult scoliosis, L5-S1 disc degeneration associated with protracted fusion finishing at L5 has been a prevalent problem. The goal of this study was to see if there were any preoperative predictors of L5-S1 disc degeneration after a length fusion arthrodesis that ended at L5 in individuals with adult scoliosis based on spinopelvic characteristics. In this retrospective study, we enrolled sixty seven adults scoliosis patients who were divided into disc degeneration and no disc degeneration groups using a modified version of radiological categorization. There was no statistical difference I preoperative lumbosacral score between the 36 patients who had the subsequent L5-s1 disc degeneration and the other 31 patients who did not have the disc degeneration. Two groups share a disc. The accuracy of the prediction of L5-S1 disc degeneration was satisfactory. In individuals with adult scoliosis, the prevalence of L5-S1 disc degeneration after protracted fusion arthrodesis finishing at L5 was 57 percent. When there are two or more of these preoperative indicators, additional care should be made to preventing degeneration of the 5-1 disc.^[11]
2. Gergory D Schroeder conducted this research in may 2016 at Thomas Jefferson university's Rothman Institute. L5/S1 fusion in degenerative spine surgery is the study's goal. For pathologies such as spondylolisthesis with stenosis, an L5/S1 interbody fusion is a typical treatment. There was a considerable difference in overall fusion rates, with a rate of 99 percent for transformal lumbar interbody fusion and an axial interbody fusion. The present literature to guide the treatment of L5/S1 pathology is limited, However the existing data imply that anterior lumbar interbody fusion and transformal lumbar interbody fusion can result in a high fusion rate. A typical surgical alteration, such as the use of bilateral pedicle screws, can remove any technique dependent benefit in fusion rate.^[8]
3. Niladari kumar Mahato conducted research at Shri Aurobindo institute of medical science in Indore MP. This research took place in July 2012, and it will compare a specific form of sacra with fully and partially fused L5 vertebrae to a normal sacra. In a sample of three hundred thirty sacra, seven linear dimensions and five surface areas were measured. These were used to create nine indices. Sixteen sacral segments were entirely connected on both sides of the L5 vertebra with the earliest sacral segments. The sacra were entirely fused to the transverse process of the L5 vertebra on one side. In terms of size, the unilaterally fused variant is smaller than the fully fused variety. These sacra had the articular surfaces ranging from the mid-5 fusion, which could be a structural modification to compensate for the smaller sacra's reduced joint surfaces. The S1 sacral segments may lumbarise as a result.^[6]

Statement of the problem:

“Identification of Sacralization of L5 and Lumbarization of S1 in LS Spine Radiography”

OBJECTIVES:-

1. To evaluate & identify sacralization of L5 in LS spine of plain x-ray.
2. To evaluate & identify Lumbarization of S1 in LS spine of plain x-ray.
3. Compare b/w sacralization & lumbarization on the basis of age & gender in plain x-ray.

Method and materials:

Sample Size: In this study we include 120 case of plain LS spine x-ray.

Study Design: It was a comparative and prospective study on patients that underwent LS Spine examination within the given period.

Study Duration: This study conducted at time period of 1year in department of radio diagnosis & imaging at SGT hospital.

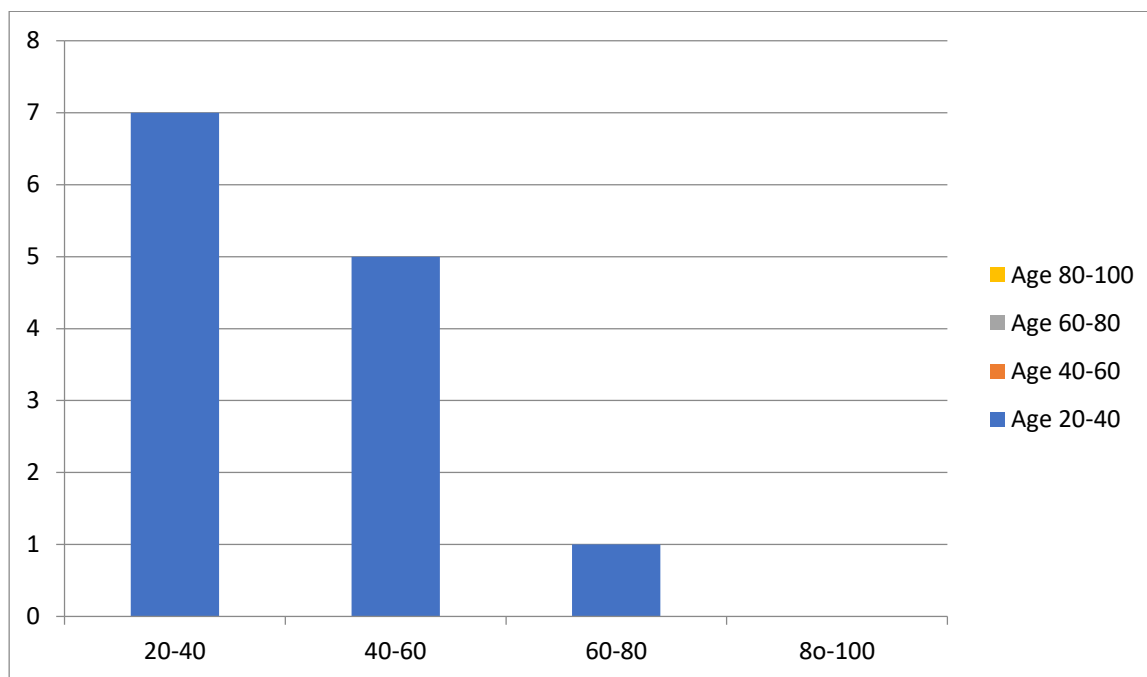
Sample collection duration: Sample collected from 1st November 2020 to 31st may 2021.

Study Area: The patients coming to SGT hospital was taken for the study.

Data collection: Data collected from the CR room in the radiology department in SGT hospital research Institute Gurugram Haryana where ALLENGER 600 MAS X-ray Machine is placed.

Results of the study:

1. evaluate & identify sacralization of L5 in LS spine of plain x-ray.



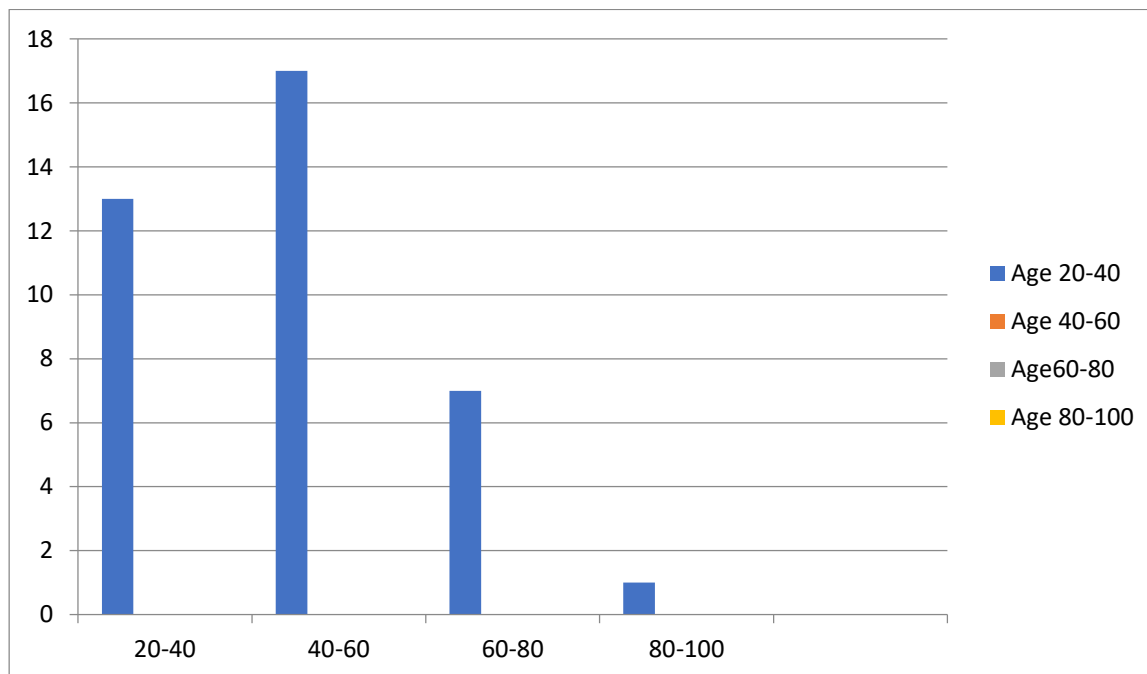
Graph no. 4 shows Sacralization of L5 acc. to age.

Table no.4 shows Sacralisation of L5 acc. to age.

Age	20-40	40-60	60-80	80-100
Sacralization	7	5	1	0

Among 120 patient of LS Spine X-ray, 13 patient have Sacralization of L5 distribution is done acc to age.

2. evaluate & identify Lumbarization of S1 in LS spine of plain x-ray.



Graph no.3 shows Lumbarization of S1 acc. to age.

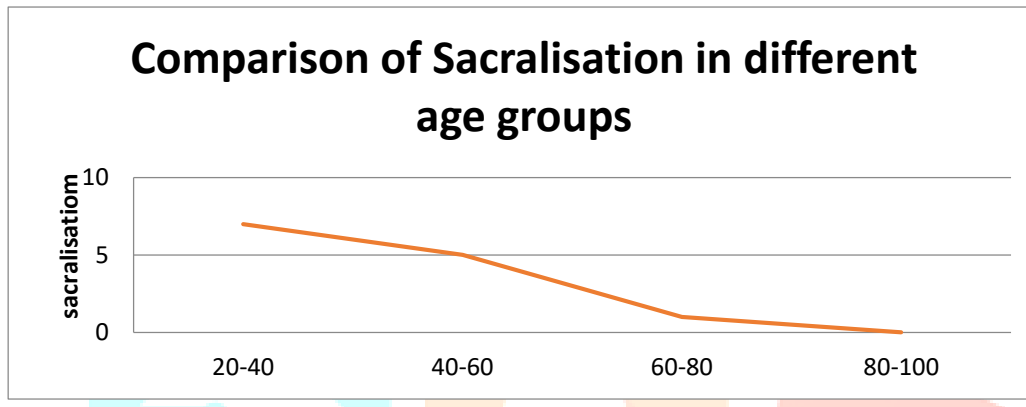
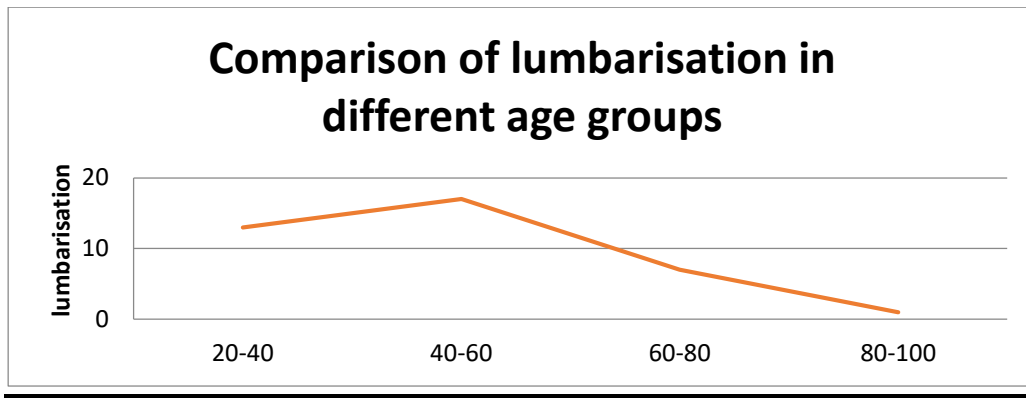
Table no.3 shows Lumbarization of S1 acc. to age.

Age	20-40	40-60	60-80	80-100
Lumbarization	13	17	7	1

Among 120 patient of LS Spine in X-ray, 38 patients have Lumbarization of S1 distribution is done acc. to age.

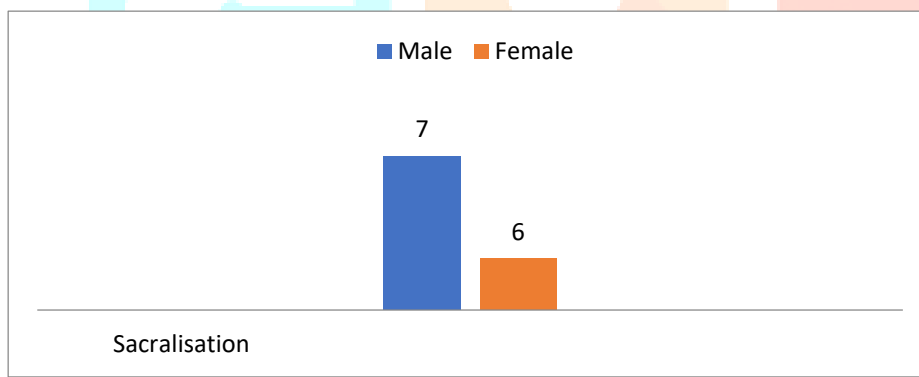
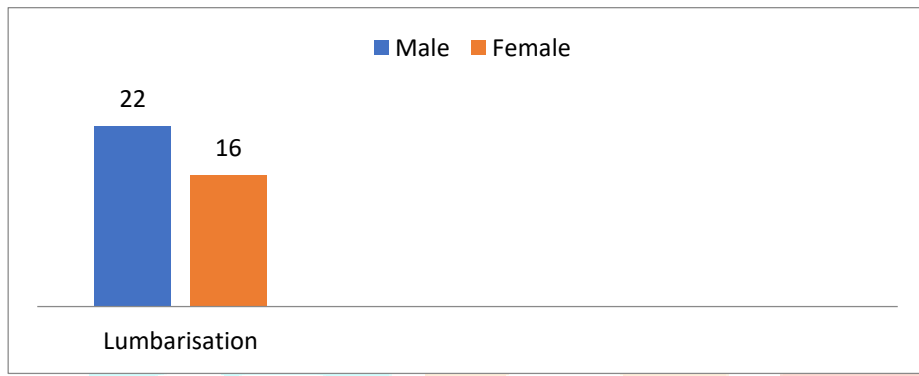
3 Compare b/w sacralization & lumbarization on the basis of age & gender in plain x-ray:

comparison of Lumbarization and Sacralization in different age groups			
Lumbarization		Sacralization	
Age Group		Age group	
20-40	13	20-40	7
40-60	17	40-60	5
60-80	7	60-80	1
80-100	1	80-100	0



➤ Comparison of lumbarisation and Sacralization on the basis of gender.

Comparison of Lumbarization and Sacralization on basis of gender			
Gender	Lumbarization	Gender	Sacralization
Male	22	Male	7
Female	16	Female	6



Conclusion

It can be concluded that patient of group A age 20-40 years have higher risk of Lumbarization and Sacralization . A total no. of 120 patients in which 38 patients have Lumbarization, 13 patients have sacralisation and rest is normal. In the study found that males have higher no. of Lumbarization and Sacralization compare with females.

References –

1. <https://www.healthline.com>
2. <https://sushovanmandal.wordpress.com>
3. <https://www.spineuniverse.com>
4. <https://www.healthline.com>
5. <http://en.wikipedia.org>
6. Mahato NK. Complete sacralization of L5 vertebrae: traits, dimensions, and load bearing in the involved sacra. Spine J. 2010 Jul;10(7):610-5. doi: 10.1016/j.spinee.2010.04.012. Epub 2010 May 23. PMID: 20547111.
7. Lee GW, Shin JH, Ryu SM, Ahn MW. The Impact of L5 Sacralization on Fusion Rates and Clinical Outcomes After Single-level Posterior Lumbar Interbody Fusion (PLIF) at L4-L5 Level. Clin Spine Surg. 2018 Feb;31(1):E62-E68. doi: 10.1097/BSD.0000000000000536. PMID: 28394774.
8. Schroeder GD, Kepler CK, Millhouse PW, Fleischman AN, Maltenfort MG, Bateman DK, Vaccaro AR. L5/S1 Fusion Rates in Degenerative Spine Surgery: A Systematic Review Comparing ALIF, TLIF, and Axial Interbody Arthrodesis. Clin Spine Surg. 2016 May;29(4):150-5. doi: 10.1097/BSD.0000000000000356. PMID: 26841206.
9. Edwards CC 2nd, Bridwell KH, Patel A, Rinella AS, Berra A, Lenke LG. Long adult deformity fusions to L5 and the sacrum. A matched cohort analysis. Spine (Phila Pa 1976). 2004 Sep 15;29(18):1996-2005. doi: 10.1097/01.brs.0000138272.54896.33. PMID: 15371700.